Diffusion-weighted MRI, ^{11}C-choline PET/CT, and ^{18}F-FDG PET/CT for predicting the Gleason score in prostate cancer

Kazuhiro Kitajima[1] MD,
Shingo Yamamoto[2] MD,
Yusuke Kawanaka[1] MD,
Yukako Nakanishi[2] MD,
Yusuke Yamada[2] MD,
Shuken Go[2] MD,
Akihiro Kanematsu[2] MD,
Hayato Kaida[3] MD,
Koichiro Yamakado[1] MD

1. Department of Radiology, Hyogo College of Medicine
2. Department of Urology, Hyogo College of Medicine
3. Department of Radiology, Kindai University Faculty of Medicine, Osakasayama, Osaka, Japan

Keywords: DWI - Choline - ^{18}F-FDG - PET - Prostate cancer - Gleason score

Corresponding author:
Kazuhiro Kitajima, MD
Department of Radiology, Hyogo College of Medicine,
Nishinomiya, Hyogo, Japan
1-1 Mukogawa-cho, Nishinomiya, Hyogo 663-8501 Japan
kazu10041976@yahoo.co.jp
Tel: +81-798-45-6883
Fax: +81-798-45-6262

Received:
10 February 2020
Accepted revised:
27 February 2020

Abstract

Objective: To evaluate diffusion-weighted magnetic resonance imaging (DWI), ^{11}C-choline positron emission tomography (PET), and fluorine-18-fluorodeoxyglucose (^{18}F-FDG) PET for predicting Gleason score in prostate cancer patients. **Subjects and Methods:** The study cohort included 11 patients with biopsy-proven prostate cancer who underwent DWI, ^{11}C-choline PET, and ^{18}F-FDG PET examinations before treatment. The correlations of Gleason score with those findings were determined using Spearman's test. Multi-technique imaging performance for separating higher Gleason score (≥8) cases was also examined. **Results:** Both diffusion coefficient (ADC) map and ^{11}C-choline PET/computed tomography (CT) findings showed prostate cancer in all 11 patients, while ^{18}F-FDG PET/CT was only successful in 6 (54.5%) cases, thus no further evaluations of that modality were performed. A moderately negative correlation was observed between Gleason score and ADC value for the primary tumor shown by DWI, though the difference was not significant (r=-0.49, P=0.13). In contrast, a strongly significant positive correlation was observed between Gleason score and maximum standardized uptake value (SUVmax) for the primary tumor in ^{11}C-choline PET findings (r=0.85, P=0.0010). Sensitivity, specificity, and accuracy for separating higher (≥8) from lower (≤7) Gleason score were 87.5%, 33.3%, and 72.7%, respectively, with a best cut-off value of 0.78 for ADC map, and 87.5%, 100%, and 90.9%, respectively, with a best cut-off value of 6.0 for ^{11}C-choline PET. **Conclusion:** Carbon-11-choline PET was found have a greater correlation with Gleason score than DWI and is considered to be more useful to predict a higher score in patients with prostate cancer. Fluorine-18-FDG PET was limited because of low sensitivity.

Hell J Nucl Med 2020; 23(1): 34-39 *Epub ahead of print: 31 March 2020* *Published online: 30 April 2020*

Introduction

In Western Europe as well as North America, prostate cancer is the most common tumor type found in males and the second-most frequent cause of all deaths from cancer [1]. The clinical behavior of primary prostate cancer ranges from microscopic well-differentiated tumors to aggressive cancer with a high likelihood of invasion and metastasis. Clinical management is diverse and may range from definitive treatment options over localized treatments to watchful waiting. Gleason score is the most commonly used pathological grading system for prostate carcinoma and remains as one of the most powerful prognostic factors [2]. Furthermore, Gleason score is central to stratifying patients into risk groups as well as determining management for prostate carcinoma patients [3, 4].

Transrectal ultrasound-guided (TRUS) biopsy results are commonly used to determine Gleason score prior to definitive management [5]. Furthermore, those results have been shown to be acceptably accurate [6] for predicting the Gleason score of prostatectomy specimens and have thus become part of the routine work-up for males suspected to have prostate cancer [3, 4]. However, the TRUS biopsy procedure has several shortcomings. First, though it is acceptably accurate, discrepancies have been reported in 25%-30% of cases [6]. In addition, while a TRUS biopsy is generally accepted to have a good safety profile, it is still an invasive procedure, with significant complications reported in up to 6% of patients [7, 8]. Finally, another study found that 15%-31% of patients may need a repeated biopsy procedure simply because the initial TRUS biopsy missed the region containing the carcinoma [9]. Additionally, patients undergoing active surveillance also require repeated biopsies [3].

Novel non-invasive imaging techniques have been proposed for either augmenting or supplanting a TRUS biopsy for prognostication in prostate carcinoma patients. These imaging techniques include diffusion-weighted magnetic resonance imaging (DWI) [10-14]

magnetic resonance spectroscopy (MRS) [15], dynamic contrast enhanced magnetic resonance imaging (MRI) [11], ^{11}C-choline positron emission tomography (PET) [13, 14-18], and fluorine-18-fluorodeoxyglucose (^{18}F-FDG) PET [13, 19]. However, it remains unclear which tool is best for predicting Gleason score in prostate cancer cases. The present study investigated and compared the accuracy of DWI, ^{11}C-choline PET, and ^{18}F-FDG PET for predicting high Gleason score in patients with prostate cancer.

Subjects and Methods

Patient

This prospective study was performed in accordance with the principles of the declaration of Helsinki. The institutional review board of Hyogo University Hospital, Japan, approved the study protocol (No. 2019). Informed consent was obtained from each patient after the procedure details were fully explained.

Eleven males (mean age 71.3±10.8 years, range 50-90 years) with biopsy-proven prostate cancer were included in this study and underwent pelvic MRI with DWI, ^{11}C-choline positron emission tomography/computed tomography (PET/CT), and ^{18}F-FDG PET/CT examinations at our institution from October 2015 to December 2019, with a maximum interval of 2 weeks between each. The interval time among the biopsy and the imaging modalities was more than eight weeks in order to avoid confusing any bleeding with cancer tissue on imaging, especially prostate MRI. These 11 patients were not under ongoing hormonal or radiation therapy or had not been treated with radiation therapy before. The median serum prostate-specific antigen (PSA) level in the cohort was 15.76 ng/mL (range 3-5916ng/mL). Additional patient details are shown in Table 1. T stage was diagnosed by pelvic MRI and N/M stage was judged by ^{11}C-choline PET/CT.

Pelvic MRI

Magnetic resonance imaging was performed using a Magnetom Avanto 1.5-T (Siemens Medical Solutions, Erlangen, Germany) system, equipped with a body coil for excitation and pelvic phased array coil for signal reception. Axial, coronal, and sagittal fast-spin-echo T2-weighted imaging (T2WI) was performed with a repetition time (TR)/echo time (TE) of 4000-4750/110-120ms, 3mm slice thickness/0.3mm gap,

Table 1. *Patients details.*

Patient	Age	Gleason score	Serum PSA	TNMstage	mean ADC value	^{11}C-choline PET SUVmax	^{18}F-FDG PET SUVmax	First treatment therapy
1	80	4+5	210.3	T2cN1M1b	0.568	7.26	4.01	Hormonal therapy
2	70	4+4	5916	T2aN1M1b	0.728	5.03	1	Hormonal therapy
3	90	5+5	3	T4N0M1b	0.611	12.91	15.21	Hormonal therapy
4	50	4+3	15.76	T2aN0M0	0.668	5.22	1	Brachytherapy
5	68	4+5	104	T2bN0M1b	0.802	6.31	3.47	Hormonal therapy
6	65	5+4	9.94	T3bN1M0	0.662	9.82	3.4	Radical prostatectomy
7	76	4+5	14	T2bN0M0	0.735	8.26	1	Radiotherapy
8	70	3+4	12.5	T2cN0M0	0.851	5.4	1	Rradiotherapy
9	82	4+5	21.5	T2cN0M0	0.707	11.25	5.12	Hormonal therapy
10	61	3+4	5.45	T2cN0M0	0.702	4.23	1	Hormonal therapy
11	72	4+5	106	T3N0M1b	0.588	8.16	4.67	Hormonal therapy

PSA: prostate-specific antigen, ADC: apparent diffusion coefficient, PET: positron emission tomography, SUVmax: maximum standardized uptake value, ^{18}F-FDG: fluorine-18-fluorodeoxyglucose

28×22cm field of view (FOV), and 228×256-256×320 matrix. T1-weighted imaging (T1WI) was performed in the axial plane with a spin-echo TR/TE of 500-550/9-10ms, 3mm slice thickness/0.3mm gap, 28×22cm FOV, and 228×256-256×320 matrix. Axial DWI was performed in 3 orthogonal directions using spin-echo-type single-shot echo planar imaging with the following parameters: b value=0 and 1000ms/mm^2, TR/TE=3500-4500/70-75ms, 3mm slice thickness/0.3mm gap, 42×32cm FOV, and 128×108 matrix. In addition, coronal T1WI and T2WI were performed with a 3mm slice thickness/0.3mm gap, 59×30cm FOV, and 228×256-256×320 matrix.

Carbon-11-choline PET/CT

Carbon-11-choline was synthesized using a commercial module, as previously described by Hara [20], and a CYPRIS-325R cyclotron (SHI, Tokyo, Japan). Acquisition of emission scan images from the mid-thigh to head was started at 6 minutes after intravenous injection of 3.0MBq/kg body weight of ^{11}C-choline. All PET/CT examinations were performed using a PET/CT scanner equipped with a 64-multidetector computed tomography device (Gemini TF64; Philips Medical Systems, Eindhoven, The Netherlands). Whole-body PET image acquisition in 3D mode was performed from the mid-thigh to top of the head (1.5 minutes per bed position; 6-8 bed positions) and obtained images were reconstructed using the ordered subsets expectation maximization reconstruction algorithm (33 subsets, 3 iterations, 4mm per slice), with attenuation correction based on low-dose CT (120kVp, 100mA, slice thickness 2mm, transverse field of view 600mm), which was also used for anatomical correlations. A dynamic acquisition of PET was not performed.

Fluorine-18-FDG PET/CT

Fluorine-18-FDG was synthesized using the nucleophilic substitution method with an F-200 ^{18}F-FDG synthesizing instrument (SHI) and CYPRIS-325R cyclotron (SHI). Patients were instructed to fast for 5 hour prior to scanning and blood glucose was measured immediately before injection of ^{18}F-FDG at 3.0MBq/kg body weight. None of the patients had a blood glucose level >160mg/dL. Whole-body ^{18}F-FDG PET/CT was performed at 60 minutes after injection of ^{18}F-FDG from the top of the head to mid-thigh, with the same acquisition and reconstruction parameters noted above for ^{11}C-choline PET/CT. No indwelling catheter or diuretic was used.

Imaging analysis

Two board-certified observers, one a double board-certified nuclear medicine physician and radiologist, and the other a board-certified radiologist, with no knowledge of the other imaging or final results, interpreted the DWI, ^{11}C-choline, and ^{18}F-FDG PET/CT imaging findings. For multiple tumors in the prostate, the dominant tumor was chosen for the estimation of MRI and PET/CT.

Apparent diffusion coefficient (ADC) maps were automatically constructed on a pixel-by-pixel basis using the following formula: ADC=log[S(b1)/S(b2)]/(b2-b1), where S(b1) and S(b2) represent the signal intensity of the diffusion weighting gradients obtained using different b1- and b2-values, ADC is the molecular diffusion coefficient, and b is the diffusion-weighted factor expressed as seconds per square millimeter. The ADC values were calculated for a pair of b-values; 0 and 1000s/mm^2, and the average ADC value within each ROI was then calculated.

Semi-quantitative analysis of abnormal radiotracer uptake for the targeted lesion was also performed using a maximum standardized uptake value (SUVmax), calculated as follows: SUV=volume of interest (VOI) of radioactivity concentration (Bq/mL)/[injected dose (Bq)/patient weight (g)]. SUVmax, defined as the highest SUV value for pixels with the highest count within the VOI, was determined for the focal areas of uptake and recorded.

Statistical analysis

Relationships between the primary tumor mean ADC values with DWI and SUVmax with ^{11}C-choline PET, as well as tumor Gleason score were assessed using Spearman's rank correlation coefficient. The strengths of the correlations were labelled using conventional statistical criteria, with 0-0.19 regarded as very weak, 0.2-0.39 as weak, 0.40-0.59 as moderate, 0.6-0.79 as strong, and 0.8-1 as very strong. An unpaired t test was applied for comparison of ADC values with DWI and SUVmax with ^{11}C-choline PET between higher (≥8) and lower (≤7) Gleason score. A receiver operating characteristic (ROC) curve was drawn to determine optimal ADC and SUVmax cut-off values that would offer the best discrimination between higher and lower Gleason score. A P-value of less than 0.05 was considered to indicate a statistically significant difference. All statistical analyses were performed using SAS software, version 9.3 (SAS Institute).

Results

Patient characteristics

Although both ADC map and ^{11}C-choline PET/CT results detected prostate cancer in all 11 patients, those of ^{18}F-FDG PET/CT were useful for detection in only 6 patients (54.5%). Thus, no further evaluations were performed with ^{18}F-FDG PET/CT. A representative case is shown in Figure 1. Dominant lesion was concordance between pelvic MRI and ^{11}C-choline PET/CT in 3 patients with multiple tumors.

Correlations of primary tumor mean ADC and SUVmax values with Gleason score

A moderately negative correlation of Gleason score with ADC value of the primary tumor in DWI results was observed, though the difference was not significant (Pearson's r=-0.49, P=0.13). On the other hand, a strongly significant positive correlation was observed between Gleason score and SUVmax of the primary tumor in ^{11}C-choline PET results (Pearson's r=0.85, P=0.0010) (Figure 2).

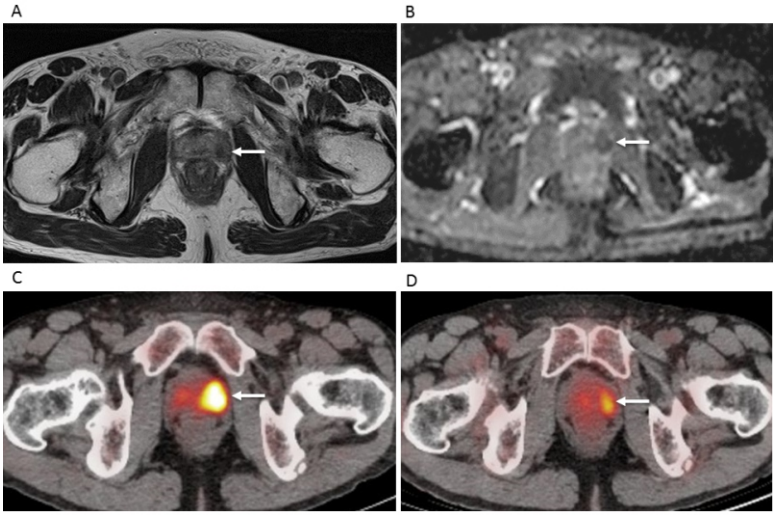

Figure 1. Images from a 68 year old male with prostate cancer, Gleason score 4+5=9 [cT2bN0M1, initial prostate specific antigen (PSA) 104ng/mL]). (a) Low signal intensity area in left peripheral zone (arrow) shown by T2WI, suggesting prostate cancer. (b) Apparent diffusion coefficient (ADC) map showing low signal intensity area in left peripheral zone (arrow), with a mean ADC value of 0.802mm^2/s, confirming prostate cancer. (c) ^{11}C-choline PET/CT image showing strong ^{11}C-choline uptake [maximum standardized uptake value (SUVmax): 6.31] in left side of prostate (arrow), confirming prostate cancer. (d) ^{18}F-FDG PET/CT image showing weak ^{18}F-FDG uptake (SUVmax: 3.47) in left side of prostate (arrow).

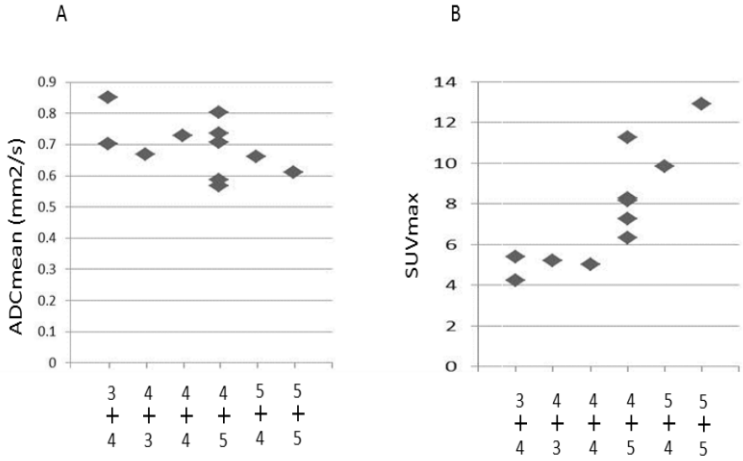

Figure 2. Correlation of mean ADC values with ^{11}C-choline SUVmax findings and Gleason score for primary prostate cancer. (a) A moderately negative correlation was observed for Gleason score and ADC values for the primary tumor by DWI, though the difference was not significant (Pearson's r=-0.49, P=0.13). (b) A strongly significant positive correlation was observed between Gleason score and SUVmax for the primary tumor by ^{11}C-choline PET (Pearson's r=0.85, P=0.0010).

Prediction of higher Gleason score

The mean ADC value (×10-3mm^2/s) for the higher Gleason score group was 0.675±0.082 (range 0.588-0.802), while that for the lower score group was 0.740±0.097 (range 0.668-0.851), which was not significantly different (P=0.38). In contrast, the mean SUVmax in ^{11}C-choline PET results for the higher score group was 8.63±2.59 (range 5.03-12.91) and for the lower score group was 4.95±0.63 (range 4.23-5.4), a significant difference (P=0.0048).

Sensitivity, specificity, and accuracy for separating higher from lower Gleason score were 87.5% (7/8), 33.3% (1/3), and 72.7% (8/11), respectively, with a best cut-off value of 0.78 for ADC value with ADC map, while those were 87.5% (7/8), 100% (3/3), and 90.9% (10/11), respectively, with a best cut-off value of 6.0 for SUVmax with ^{11}C-choline PET.

Discussion

A major finding of this study is that among the 3 modalities examined (DWI, ^{11}C-Choline PET/CT, ^{18}F-FDG PET/CT), ^{11}C-choline PET showed the best correlation with Gleason score. Furthermore, findings obtained with it were found useful to predict higher Gleason score (≥8).

Diffusion weighted imaging is dependent upon the random movement of water molecules (Brownian motion) in imaged tissues, which reflects the diffusion of water in interstitial space, thus providing information about the biophysical properties of scanned tissue, including architecture and cell density. The diffusion properties of examined tissue can

be quantified by calculating the ADC, which has been found to correlate significantly with cell density [21]. Apparent diffusion coefficient declines as the glandular architecture is gradually replaced by tightly packed cancer cells, such as in cancer cases with a higher Gleason score. Several previous studies have shown that DWI results have a significant correlation with Gleason score [10-14]. Of those, Bittencourt et al. (2010) [10] compared DWI ADC values with prostatectomy Gleason score in 24 patients and found a significantly negative correlation between the mean ADC of suspicious lesions and that score (Pearson's r=-0.63, P<0.01). In addition, Kitajima et al. (2013) [12] compared ADC values with TRUS biopsy findings for predicting true Gleason score in a study of 105 patients who underwent a radical prostatectomy and demonstrated that ADC value could predict the true score as effectively as TRUS biopsy findings.

Carbon-11-choline PET provides images that are dependent upon choline accumulation in cells. That modality uses a radiotracer based on choline, an essential component of the cell membrane that is taken up into cells by a specific transport system and then phosphorylated by choline kinase to phosphorylcholine. Prostate cancer cells are known to have a high level of uptake of choline, possibly owing to a higher proliferation rate. Carbon-11-choline PET SUV results have been reported to be significantly correlated with several immunohistochemical markers of malignancy and aggressiveness, including choline kinase α expression [22] and MIB-1/Ki-67 labeling index [16], and several studies have also investigated the relationship of ^{11}C-choline PET SUV with Gleason score. In a study of 14 patients, Piert et al. (2009) [16] compared tumor to background ^{11}C-choline PET SUV ratios with prostatectomy Gleason scores, and found significantly higher tumor to background SUV ratios in high Gleason score lesions (Gleason ≥4+3) as compared to those with a lower score (Gleason ≤3+4) (P<0.0001). Also, Park et al. (2012) [14] compared DWI, ^{11}C-choline PET, and those in combination with prostatectomy Gleason scores in a study of 17 patients, which revealed significant differences between Gleason ≥3+4 cancer cases as compared to Gleason ≤ 3+3 cases regardless of the modality or their combination.

To the best of our knowledge, only 2 other studies have examined DWI and ^{11}C-choline PET for evaluating their correlation with Gleason score and predicting that score in prostate cancer cases. Chang et al. (2014) [13] performed a study of 21 patients with peripheral zone prostate cancer who were scheduled for a radical prostatectomy, and demonstrated a significant negative correlation between mean ADC and Gleason score (Pearson's r=-0.601, P=0.004), while there was none between choline PET SUVmax and that score (Pearson's r=-0.348, P=0.122). On the other hand, Park et al. (2012) [14] studied 17 patients with prostate cancer scheduled for a radical prostatectomy and found that choline PET had a better correlation with Gleason score than DWI. They also noted that the mean ^{11}C-choline PET tumor-to-benign prostate background ratio (TBR) was significantly increased in patients with a Gleason score ≥3+4 as compared those with a score ≤3+3 (P<0.01), and that mean ADC TBR was decreased in Gleason ≥3+4 cases as compared with ≤3+3 disease (P< 0.05), similar to the findings in the present cohort.

Fluorine-18-FDG PET results allows for assessment of the metabolic state of malignant lesions by showing tumors with accumulation of ^{18}F-FDG, a glucose derivative in which the hydroxyl function in position 2 is replaced by a radioactive fluorine isotope. Fluorine-18-FDG is taken up by glucose transporters into cells and then phosphorylated via hexokinase. Because of the missing hydroxyl function, further metabolism is not possible and because of the negative charge, phosphorylated ^{18}F-FDG cannot cross the cell membrane, thus becoming trapped in the cell. Chang et al. (2014) [13] found no significant correlation between ^{18}F-FDG PET SUV findings and prostatectomy Gleason scores.

The present study has some limitations. First, it included a small number of patients enrolled from a single institution. A prospective multicenter trial with a larger cohort would help to clarify the exact role of DWI and ^{11}C-choline PET/CT for decision making in clinical situations. Furthermore, the enrolled population was heterogeneous and did not include patients with a low Gleason score (≤3+3), which likely introduced confounding factors into the analysis. Finally, new and more sensitive PET tracers for prostate cancer, such as ^{18}F-FACBC and ^{68}Ga-PSMA, have been recently introduced for clinical use, though they are not yet available in Japan.

In conclusion, ^{11}C-choline PET was found to have a greater correlation with Gleason score than DWI and is considered to be more useful to predict higher Gleason score in patients with prostate cancer. In addition, ^{18}F-FDG PET findings were shown to be limited because of low sensitivity.

Acknowledgement
This work was supported by JSPS KAKENHI grant numbers 19K08187.

The authors declare that they have no conflicts of interest.

Bibliography

1. Siegel RL, Miller KD, Jemal A. Cancer statistics, 2018. *CA Cancer J Clin* 2018; 68: 7-30.
2. Epstein JI, AllsbrookWC Jr, AminMB, Egevad LL. The 2005 International Society of Urological Pathology (ISUP) Consensus Conference on Gleason Grading of Prostatic Carcinoma. *Am J Surg Pathol* 2005; 29: 1228-42.
3. Mohler J, Bahnson RR, Boston B et al. NCCN clinical practice guidelines in oncology: prostate cancer. *J Natl Compr Canc Netw* 2010; 8: 162-200.
4. Carroll PH, Mohler JL. NCCN Guidelines Updates: Prostate cancer and prostate cancer early detection. *J Natl Compr Canc Netw* 2018; 16: 620-3.
5. Watanabe H, Igari D, Tanahashi Y et al. Transrectal ultrasonotomography of the prostate. *J Urol* 1975; 114: 734-9.
6. Fine SW, Epstein JI. A contemporary study correlating prostate needle biopsy and radical prostatectomy Gleason score. *J Urol* 2008; 179: 1335-8.
7. Loeb S, van den Heuvel S, Zhu X et al. Infectious complications and hospital admissions after prostate biopsy in a European randomized trial. *Eur Urol* 2012; 61: 1110-4.
8. Chiang IN, Chang SJ, Pu YS et al. Major complications and associated risk factors of transrectal ultrasound guided prostate needle biopsy: a retrospective study of 1875 cases in Taiwan. *J Formos Med Assoc* 2007; 106: 929-34.
9. D'Amico AV, Tempany CM, Cormack R et al. Transperineal magnetic resonance image guided prostate biopsy. *J Urol* 2000; 164: 385-7.
10. Bittencourt LK, Barentsz JO, de Miranda LC, Gasparetto EL. Prostate MRI: diffusion-weighted imaging at 1.5T correlates better with prostatectomy Gleason Grades than TRUS-guided biopsies in peripheral zone tumours. *Eur Radiol* 2012; 22: 468-75.
11. Oto A, Yang C, Kayhan A et al. Diffusion-weighted and dynamic contrast-

enhanced MRI of prostate cancer: correlation of quantitative MR parameters with Gleason score and tumor angiogenesis. *Am J Roentgenol* 2011; 197: 1382-90.
12. Kitajima K, Takahashi S, Ueno Y et al. Do apparent diffusion coefficient (ADC) values obtained using high b-values with a 3-T MRI correlate better than a transrectal ultrasound (TRUS)-guided biopsy with true Gleason scores obtained from radical prostatectomy specimens for patients with prostate cancer? *Eur J Radiol* 2013; 82: 1219-26.
13. Chang JH, Lim Joon D, Lee ST et al. Diffusion-weighted MRI, ^{11}C-choline PET and ^{18}F-fluorodeoxyglucose PET for predicting the Gleason score in prostate carcinoma. *Eur Radiol* 2014; 24: 715-22.
14. Park H, Wood D, Hussain H et al. Introducing parametric fusion PET/MRI of primary prostate cancer. *J Nucl Med* 2012; 53: 546-51.
15. Zakian KL, Sircar K, Hricak H et al. Correlation of proton MR spectroscopic imaging with Gleason score based on step-section pathologic analysis after radical prostatectomy. *Radiology* 2005; 234: 804-14.
16. Piert M, Park H, Khan A et al. Detection of aggressive primary prostate cancer with ^{11}C-choline PET/CT using multimodality fusion techniques. *J Nucl Med* 2009; 50: 1585-93.
17. Zielinski A, Behrendt FF, Verburg FA et al. Phantom studies and clinical application of high resolution, image reconstruction using ^{18}F-fluoromethylcholine PET/CT for prostate cancer. *Hell J Nucl Med* 2014; 17: 194-9.
18. Vorster M, Modiselle M, Ebenhan T et al. Fluorine-18-fluoroethylcholine PET/CT in the detection of prostate cancer: a South African experience. *Hell J Nucl Med* 2015; 18: 53-9.
19. Jadvar H. FDG PET in prostate cancer. *PET Clin* 2009; 4: 155-61.
20. Hara T, Yuasa M. Automated synthesis of [^{11}C] choline, a positron-emitting tracer for tumor imaging. *Appl Radiat Isot* 1999; 50: 531-53.
21. Zelhof B, Pickles M, Liney G et al. Correlation of diffusion weighted magnetic resonance data with cellularity in prostate cancer. *BJU Int* 2009; 103: 883-8.
22. Contractor K, Challapalli A, Barwick T et al. Use of [^{11}C]choline PET-CT as a noninvasive method for detecting pelvic lymph node status from prostate cancer and relationship with choline kinase expression. *Clin Cancer Res* 2011; 17: 7673-83.