Progression free survival related to ^{18}F-FDG PET/CT uptake and ^{131}I uptake in lung metastases of differentiated thyroid cancer

Xiaochun Zhu[1,2*] MD,
Shuqi Wu[1*] MD,
Xueyu Yuan[*3] MD,
Hui Wang[1] MD,
Chao Ma[1,3] MD

**Xiaochun Zhu, Shuqi Wu and Xueyu Yuan contributed equally to the work.*

1. Department of Nuclear Medicine, XinHua Hospital, School of Medicine, Shanghai Jiaotong University, Shanghai, China
2.Department of Nuclear Medicine, Affiliated Ninth People's Hospital of Shanghai Jiaotong, University School of Medicine, Shanghai, China
3. Department of Nuclear Medicine, Tenth People's Hospital of Tongji University, Shanghai, China

Keywords: Progression free survival - ^{18}F-FDG PET/CT uptake - ^{131}I uptake -Lung metastases -Diifferentiated thyroid cancer

Corresponding author:
Chao Ma MD, PhD, Professor
Kongjiang Road 1665, Nuclear Medicine,
Xinhua Hospital, School of Medicine,
Shanghai Jiaotong University,
Shanghai, China 200092.
Yanchangzhong Road 301,
Department of Nuclear Medicine and Tenth People's Hospital of Tongji University, Shanghai, China 200072
Tel: +86-021-25078593;
machao@xinhuamed.com.cn;
mc_7419@hotmail.com

Received:
5 May 2019
Accepted revised:
14 June 2019

Abstract

Objectives: The lungs are the distant organ most frequently having metastases from differentiated thyroid cancer (DTC). Positive fluorine-18-fluorodeoxyglucose positron emission tomography/computed tomography (^{18}F-FDG PET/CT) scan can detect pulmonary metastases (PM) and thus suggest prognosis in DTC patients. The prognostic value of such a positive scan in DTC patients has not been specified. In this paper we studied the prognostic value of ^{18}F-FDG PET/CT scan uptake and also of iodine-131 (^{131}I) in DTC patients with PM. **Subjects and Methods:** Out of 4500 DTC patients we retrospectively studied 83 patients having PM and treated with thyroidectomy and ^{131}I ablation. Clinical data were also studied. Therapeutic response assessment was based on serum thyroglobulin (Tg) levels, Tg antibodies (TgAb) and tumor size on CT before and after ^{131}I treatment. The mean follow-up period after the diagnosis of PM was 111.9±91.6 months (range: from 15 to 159 months). Sixty two (62/83) patients with PM were diagnosed soon after ^{131}I ablation, 8 patients at 6months, 6 at 12 months and 4 at 18 months after ^{131}I ablation. The remaining 3 patients were diagnosed at 30, 36 and 60 months after ^{131}I ablation, respectively. The progression-free survival was estimated by the Kaplan-Meier method. **Results:** Out of the 83 patients, 25 showed ^{18}F-FDG uptake in PM of DTC with elevated Tg. Weak significant difference in the primary tumor size was found between ^{18}F-FDG- positive and negative PM of DTC (P=0.05). After ^{131}I ablation 57/83 patients had positive to ^{131}I PM and also positive Tg. These patients were not statistically related to patients with positive or negative ^{18}F-FDG PM according to CT and Tg levels (P=0.35, 0.47). The presence of ^{131}I uptake in the lung lesions and the absence of ^{18}F-FDG uptake in these lesions were independently related to a better progression-free survival (P=0.00). **Conclusion:** So, we conclude that ^{18}F-FDG avidity predicates poor therapeutic effect on tumor size, high risk of disease progression and less favorable prognosis. Iodine-131 avidity remains the key factor suggesting a positive therapeutic effect on PM.

Hell J Nucl Med 2019; 22(2): 123-130 *Epub ahead of print: 7 July 2019* *Published online: 20 July 2019*

Introduction

The lungs are the most frequent distant site for metastases from differentiated thyroid cancer (DTC), with an incidence of approximately 1%-4% [1]. Studies have reported on clinical factors at diagnosis such as age, gender, initial size and characteristics of tumor which relate to the therapeutic effect of radioiodine (^{131}I) ablation and to prognosis inpatients with lung metastases (PM) from DTC [2-5]. These DTC metastases may be avid of fluorine-18-fluorodeoxyglucose (^{18}F-FDG) which was often thought to be a poor prognostic factor [6]. An inverse relationship between ^{131}I and ^{18}F-FDG uptake in metastatic lesions of DTC patients is well known. However, our previous data suggested that over half of the bone metastases (58.33%, 42/72) from DTC had both ^{131}I and ^{18}F-FDG uptake. Our hypothesis is that ^{131}I and ^{18}F-FDG metabolism may vary in DTC metastases in the lungs. To our knowledge, no study has related ^{18}F-FDG PET results to ^{131}I uptake as prognostic factors in PM of DTC. We have studied ^{18}F-FDG and ^{131}I uptake in PM of DTC under thyroid hormone withdrawal (THW) and ^{131}I ablation related to prognosis of survival of these patients.

Subjects and Methods

Patients

Patients from January 2004 to March 2016 were included if met the following criteria: a) Patients with pathologically established papillary or follicular cancer. b) Patients who had

^{18}F-FDG single photon emission tomography (SPET)/computed tomography (CT) or positron emission tomography/CT (PET/CT) before ^{131}I treatment for PM. c) Patients received more than one course of ^{131}I treatment after the diagnosis of PM by SPET/CT or ^{18}F-FDG PET/CT. Patients were excluded if there was a history or coexistence of other malignancies. Shanghai Jiaotong University, Medical School affiliated to Xinhua Hospital Review Board approved this retrospective study and written informed consent was obtained from all patients. The study was conducted in accordance with the Declaration of Helsinki and was approved by the appropriate institutional Human Research Committee (XHEC-D-2017-044).

The diagnosis of DTC PM was established according to one of the following criteria: a) the lung lesion was histologically proven. b) ^{131}I uptake was found in lateral or in bilateral lungs on ^{131}I post therapy scan more than once with elevated TSH, and increased serum Tg. c) Positive ^{18}F-FDG findings in the lungs on ^{18}F-FDG SPET/CT and/or the PET/CT scan with elevated Tg and/or positive ^{131}I uptake.

Therapeutic approach and follow-up schedule

All patients were instructed to follow a low-iodine diet for at least 2 weeks before ^{131}I treatment. Serum thyroid-stimulating hormone (TSH) levels were 85.03±35.37uIU/mL after withdrawal of levothyroxine (L-T4) for 3-4 weeks. Treatment with L-T4 therapy was administered 72h after ^{131}I treatment.

The adult patients having ^{131}I avid PM were treated with high doses of ^{131}I (5.55 to 9.25GBq) every 3-12 months. Patients having ^{131}I avid PM if 10-18 years old were treated with 4.625-7.4GBq and if 5-10years old were treated with 2.775-4.44GBq every 6-12 months. The cumulative activity of ^{131}I ranged from 7.77-122GBq. The number of ^{131}I therapies ranged from 2-15 (mean 4.5). The mean follow-up period was 111.9±91.6 months.

^{18}F FDG PET/CT imaging

After 3-4 weeks of THW, patients with PM were admitted to our department. On the 1st day after admission, ^{18}F-FDG PET/CT scans together with other conventional measurements, including clinical examination, serum TSH, serum stimulated thyroglobulin (Tg) and serum anti-thyroglobulin antibodies (TgAb) were examined. On the 2nd day after admission started ^{131}I treatment. A SPET scan was performed 3 days after ^{131}I treatment. At the time the scans were performed, serum TSH was 85.03±35.37μIU/mL.

A ^{18}F-FDG PET/CT scan using a camera Biograph mCT 64, Siemens Medical Systems, Knoxville, Tenn, USA images was also performed on the 1st day after admission. All patients fasted for at least 6 hours before the ^{18}F-FDG PET/CT scan. Serum glucose levels measured before ^{18}F-FDG injections were less than 150mg/dL in all patients. Fluorine-18-FDG in a dose of 5.55MBq/kg body weight was administered intravenously and then the patient tested on a chair or bed for 45-60 minutes. Patients with ^{18}F-FDG positive PM at first underwent a neck and chest scan. Abnormal foci were defined as having SUVmax>1.0 in the lungs.

^{18}F-FDG SPET/CT coincidence imaging protocol

The ^{18}F-FDG SPET/CT imaging was performed on GE infiniaVc Hawkeye H3000YS as we previously described [7]: The field of view (FOV) was 40cm, in two or three bed positions including the neck, chest, abdomen, and pelvic. The CT scans were performed with a single detector, 140kv and 2.5mA. Gantry rotation speed was 8sec per revolution. The CT images were used for attenuation correction and lesion localization. The emission images were reconstructed with the ordered subset expectation maximization implementation of iterative reconstruction [7].

^{131}I whole-body scintigram (WBS)

The ^{131}I WBS was acquired within 3-5 days after administration of the therapeutic dose of ^{131}I. Post-treatment ^{131}I WBS was obtained in the anterior and posterior projections with a large field-of-view (FOV) gamma camera equipped with a high-energy collimator (peak energy centered on 360keV with a 20% energy window) (Philips Precedence 16 SPET/CT, Philips, Netherlands, and Hawkeye WZ, GE Medical Systems, Milwaukee, WI, USA). Fusion SPET/CT was performed in doubtful cases of PM for better diagnosis.

Criteria of remission

Tumor size evaluation on anatomical imaging

The CT images on ^{18}F-FDG PET/CT were obtained with 3mm slice thickness starting from the apex of the lungs, at the supine position. Small PMs with a diameter of less than 1cm were detected only by ^{131}I WBS, while findings on chest CT were negative. Nodular PM with diameter more than 1cm were detected by CT [1]. All images were reviewed by two radiologists in consensus, who were blinded to other results or clinical findings.

The local efficacy of ^{131}I treatment was evaluated based on anatomical imaging changes of well-defined lesions. The difference in tumor size between the pre-treatment and the last follow-up CT images was assessed using Response Evaluation Criteria in Solid Tumors (RECIST, version 1.1) as follows: i) Complete response (CR): disappearance of all lesions, which lasted for at least 4 weeks; ii) Partial response (PR):>30% decrease in the sum of lesions diameters, taking as reference the baseline sum diameters, lasted also for at least 4 weeks; iii) Progressive disease (PD):>20% increase in the sum of lesion diameters or 5mm increase in the sum of lesion diameters or appearance of new lesions and iv) Stable disease (SD): no sufficient shrinkage and no sufficient increase to qualify for PD. The above CR and PR were considered good response to ^{131}I therapy in this study.

Tg evaluation

Both Tg and TgAb were obtained prior to ^{131}I administration using a time-resolved immunofluorometric assay (Anytest, symbio lifescience co., ltd, Shanghai, China). After all courses of ^{131}I therapy, comparisons of Tg level between pre-treatment and the last follow-up were classified into three types indicating [8]: i) Effectiveness: A reduction of >25% in Tg levels; ii) Stabilization: decreased or increased Tg by<25% and iii) Progression: Tg increased by >25%. A reduction of >25% in Tg levels was considered good response to ^{131}I therapy in this study.

Statistical analysis

Statistical SPSS version 18.0 was used for statistical analyses. Continuous data were expressed as mean±standard deviation; categorical data were presented as frequency and percentage. Continuous data analysis using independent samples Student's t-test and categorical data were calculated using Pearson`s chi-square test. All factors that may have affect Tg and anatomical imaging in the PM were analyzed by univariate analysis and confirmed by the chi square test. Multinomial logistic regression analysis was used to determine factors that contributed to the outcome of therapy response. The progression-free survival (PFS) time, as measured by the time between the date of the diagnosis of PM and the date of disease progression according to RECIST version 1.1 criteria was the primary end point of this study. The effect of different variables on PFS was estimated by Kaplan-Meier survival analysis and the differences between groups were compared using the log-rank test. A P value of less than 0.05 was considered statistically significant.

Results

Patients' characteristics

Patients' characteristics according to the accumulation of ^{18}F-FDG are listed in Table1. Eighty three patients with PM were enrolled in this study out of 4500 patients with DTC who entered our hospital, from January 2004 to March 2016. The age of the 83 patients was 44.1±17.1 years (ranging from 6 to 77 years). Our patients were 25 men and 58 women. Sixty two (62/83) patients were diagnosed with PM soon after ^{131}I ablation, 8 patients after 6 months , 6 patients after 12 months and 4 after 18 months. The remaining 3 patients were diagnosed at 30,36 and 60 months after^{131}I ablation, respectively. Pulmonary metastases detected by ^{18}F-FDG SPET/CT and/or by PET/CT were also detected by the ^{131}I WBS in 23/83 DTC patients. Uptake on ^{18}F-FDG was found in 25/83 patients whilethe remaining patients (58/83) had a negative ^{18}F-FDG scan. Out of these 58 patients, 46 patients showed ^{131}I uptake on the ^{131}I post therapy scan, while 12 had no ^{131}I uptake. Inverse relation between ^{131}I and ^{18}F-FDG uptake was found in 60/83. The ^{18}F-FDG positive PM patients were mostly older patients (P= 0.003) at first diagnosis and also PM patients without ^{131}I uptake were of older age (P=0.001). Seventy six patients had very little uptake and the remaining 7/83 had nodular PM (Table 1).

Furthermore, we divided the PM into 4 subgroups according to the ^{18}F-FDG SPET/CT and/or PET/CT and ^{131}I-avid results: (1)^{18}F-FDG negative and ^{131}I positive PM (F^-/I^+, n=46); (2) accumulation of both ^{18}F-FDG and ^{131}I (F^+/I^+, n=11), see Figure 1; (3) ^{18}F-FDG positive and ^{131}I negative PM (F^+/I^-, n=14) and (4) both negative accumulation of ^{18}F-FDG and ^{131}I (F^-/I^-, n=12), see Figure 2.

Response assessment based on changes of tumor size on chest CT images

According to the RECIST (version 1.1), we found that 30/83 patients showed PR, while 30/83 patients had SD and 23/83 had PD. Significant difference in changes of tumor size was found between patients with ^{18}F-FDG positive and negative PM (2=7.563, P=0.023) (Table 2). Iodine-131 avidity was the significant factor for characterizing the therapeutic effect on the PM (P<0.00). In the subgroup analysis, no significant difference in response to ^{131}I therapy was found between PM with $F^-/I^+$and F^+/I^+, F^+/I^- andF^-/I^- (P= 0.35 and 0.91)(Table 3).

Table 1. *Patients' characteristics according to ^{18}F-FDG accumulation in lung metastases from DTC.*

Characteristics	Total	Positive ^{18}F-FDG	Negative ^{18}F-FDG	P value
Number of patients	83	25	58	
Age (mean±SD, years)	44.1± 17.1	51.9± 14.1	40.8± 17.3	0.003
Gender (n, %)				0.187
Male	25 (30.1)	5	20	
Female	58 (69.9)	20	38	
Histological type (n, %)				0.443
Papillary	76 (91.6)	22	54	
Follicular	7(8.4)	3	4	
Operation method (n, %)				0.548
Lobectomy or subtotal thyroidectomy	39 (47.0)	13	26	
Total thyroidectomy	44 (53.0)	12	32	
Size of lung metastases (n, %)				0.103
Very small	76 (91.6)	21	55	
Nodular	7(8.4)	4	3	
Extent of metastases lung only	71	20	51	0.715
lung and other organs	12	4	8	

(continued)

^{131}I uptake by metastases (n, %)				0.001
Yes	57 (68.7)	11	46	
No	26 (31.3)	14	12	

Response assessment based on Tg

Iodine-131therapy was effective in 41/83patients, stable and ineffective in 14 and 28 patients, respectively based on Tg. No significant difference in Tg was found between patients with ^{18}F-FDG positive and negative PM (χ^2=0.61, P= 0.74). Avidity to ^{131}I was also the significant factor on therapeutic of ^{131}I on PM (P=0.0) (Table 2). In the subgroup analysis, no significant difference in response to ^{131}I therapy was found between PM with F^-/I^+ and F^+/I^+, F^+I^- and F^-/I^- patients

Table 2. Univariate analyses of factors predicting therapeutic response after based on anatomical imaging (chest CT) changes and s-Tg on a per-patient basis.

Factor	Changes of anatomical imaging			P value	Changes of serum Tg			P value
	PR	SD	PD		Eff	Sta	Ine	
^{18}F-FDG uptake								
Positive	4	9	11	0.023	12	5	7	0.769
Negative	26	21	12		29	9	21	
^{131}I uptake								
Positive	28	19	10	0.00	36	11	10	0.00
Negative	2	11	13		5	3	18	
Total	30	30	23		41	14	28	

*n, number; Tg, thyroid stimulating hormone (TSH)-stimulated serum thyroglobulin; PR, partial response; SD, stable disease; PD, progressive disease. Eff, effectiveness; Sta, stabilization; Ine, ineffectiveness.*means significant difference in PR between ^{18}F-FDG positive - versus ^{18}F-FDG negative lung metastases based on changes of tumor size.*

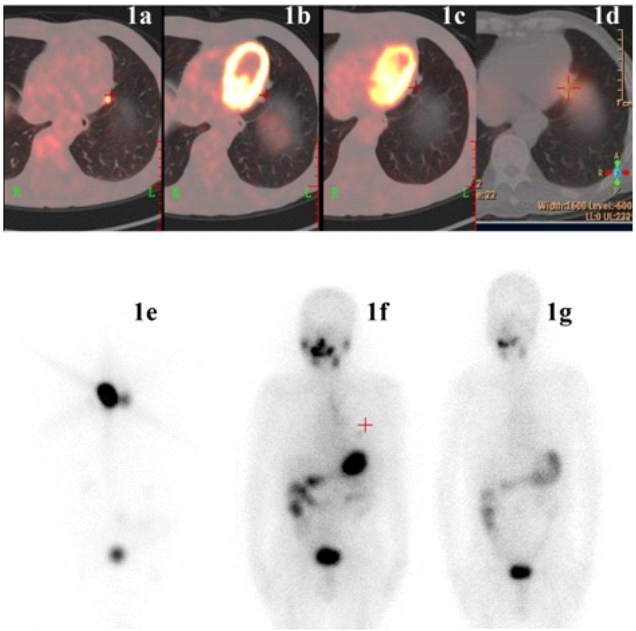

Figure 1. A 73 years old man had ^{18}F-FDG and ^{131}I avid lung metastases from papillary thyroid cancer (T1N0M1) and responded well to ^{131}I treatment (decreased Tg and tumor size). **1a,** ^{18}F-FDG PET/CT scan before ^{131}I treatment showed a tiny nodule in the lower lobe of left lung with SUVmax 5.22 as showed by a red cross; **1b,** ^{18}F-FDG PET/CT scan showed decreased ^{18}F-FDG uptake with a SUVmax 0.78 (red cross) 6 months after 3.7GBq ^{131}I; **1c,** ^{18}F-FDG PET/CT scanshowed no uptake (red cross) in the same lesion 12 months after 11.1GBq ^{131}I. **1d,** 1st post ^{131}I (3.7GBq) therapy SPET/CT fusion scan showed positive lesion at the same lesion of left lung; **1e,** The first post therapy planar imaging showed the residual thyroid tissue (TSH 19.79μIU/mL, Tg 896.47ng/mL).**1f,** 2nd post ^{131}I (7.4GBq) therapy scan also showed a positive lesion in the left lung (red cross) (TSH 75.02μIU/mL, Tg 217.63ng/mL). **1g,** the lesion was not seen on the 3rd post ^{131}I (7.4GBq) therapy scan (TSH 66μIU/mL, Tg 97.39ng/mL).

(P=0.35 and 0.91)(Table 3). Significant difference in effective decrease of Tg was found between patients with both ^{18}F-FDG and ^{131}I avid (F^+/I^+) and both ^{18}F-FDG and ^{131}I negative (F^-/I) PM (P=0.009) (Table 4).

Table 3. *^{18}F-FDG and ^{131}I accumulations and local therapeutic response after examined by CT.*

^{18}F-FDG uptake	No. of patients			P value
	CR+PR	SD	PD	
$^{18}F^-/^{131}I^+$	24	15	7	0.35
$^{18}F^+/^{131}I^+$	4	4	3	
$^{18}F^+/^{131}I^{-*}$	1	5	8	0.91
$^{18}F^-/^{131}I^-$	1	6	5	

**means significant difference between $^{18}F^-/^{131}I^+$ and $^{18}F^+/^{131}I^-$ (P=0.01). CR, complete response; PR, partial response; SD, stable disease; PD, progressive disease;.*

Progression-free survival (PFS)

Of all the 83 patients included in the study as mentioned before, 23 had disease progression. The median progression-free interval (PFI) of these patients was 39 months (ranging from 21 to 69 months). The presence of ^{131}I uptake (χ^2= 16.732, P=0.00) (Figure 3a) and the absence of ^{18}F-FDG uptake (χ^2=15.014, P=0.000) (Figure 3b), the older age (χ^2=4.758) at diagnosis of PM and extent of metastases (χ^2=4.042, P= 0.044) were related to PFS (Table 5).

During a mean of 111.9±91.6 months follow-up, 8/83 patients died, out of whom 2 had F^+/I^-, 3 had F^-/I^-, 2 had F^-/I^+ and 1 had F^+/I^+PM.

Table 4. *^{18}F-FDG and ^{131}I accumulations and local therapeutic after response by serum thyroglobulin changes.*

^{18}F-FDG uptake	No. of patients			P value
	Eff	Sta	Ine	
$^{18}F^-/^{131}I^+$	28	8	10	0.47
$^{18}F^+/^{131}I^+$	8	3	0	
$^{18}F^+/^{131}I^{-*}$	5	2	7	0.08
$^{18}F^-/^{131}I^{-*}$	0	1	11	

**means significant difference between $^{18}F^-/^{131}I^+$ and $^{18}F^+/^{131}I^-$ (P=0.002), $^{18}F^+/^{131}I^+$ and $^{18}F^-/^{131}I$ (P=0.009). Eff, effectiveness; Sta, stabilization; Ine, ineffectiveness.*

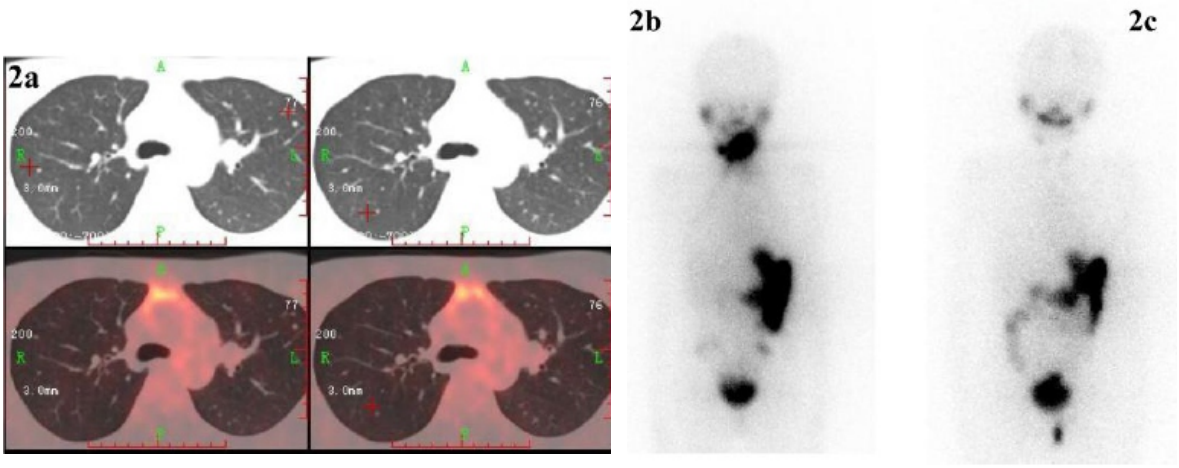

Figure 2. A 10 years old boy with both ^{18}F-FDG and ^{131}I non-avid lung metastases from papillary thyroid cancer (T2N1bM1). **2a,** ^{18}F-FDG PET/CT scan before ^{131}I treatment showed multiple tiny nodules (red cross) in the lung without ^{18}F-FDG uptake. **2b,** 1st post ^{131}I (5.5GBq) therapy scan showed no uptake in both lungs (TSH 140.15μIU/mL, Tg 644.22ng/mL). **2c,** 2nd post ^{131}I (5.5GBq) therapy scan was also negative (TSH 170 μU/mL Tg 853.25ng/mL).

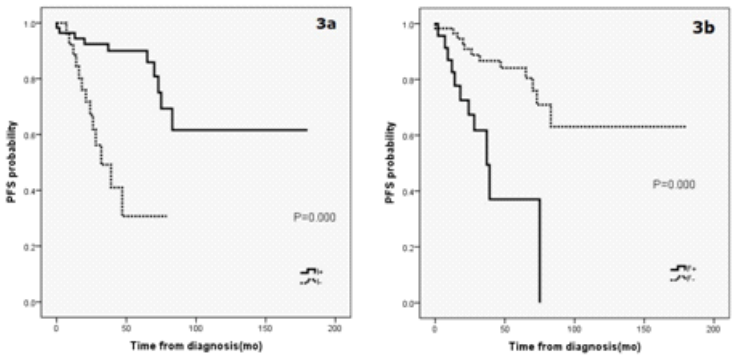

Figure 3. Progression-free survival (PFS) graphs show that patients with ^{131}I positive (χ^2=16.732, P=0.00, Figure 3a) and negative ^{18}F-FDG uptake in PM (χ^2= 15.014, P= 0.000, Figure 3b) had significantly longer PFS.

Table 5. *Univariate and multivariate analyses of factors predicting progression-free survival.*

Factor	Number of patients (n)		Median PFI (month)	P value
	Total	PD or death		
Age				0.029
≥45 yr	44	17	32	
<45 yr	39	6	54	
Gender				0.456
Female	58	14	33.5	
Male	25	9	47	
Histology				0.887
PTC	76	21	31	
FTC	7	2	48	
Extent of metastases				0.044
Lung only	72	18	48	
Lung and other organs	11	5	22.5	
^{131}I uptake				0.000
Positive	57	10	54	
Negative	26	13	25.5	
^{18}F-FDG uptake				0.000
Positive	24	11	28.5	
Negative	59	12	52	
Thyro-globulin				0.614
Decrease >25%	33	9	23	
Stable or increase	50	14	26	

Notes: PD, progressive disease; PFI, progression-free interval; PTC, papillary thyroid cancer; FTC, follicular thyroid

Results

Fluorine-18-FDG PET scanning is performed in high risk DTC patients with negative WBS and positive Tg [9, 10]. For patients with elevated Tg before ablation or during follow-up ^{18}F-FDG SPET/CT and PET/CT may be used in order to detect possible lesions. According to our knowledge, few studies focused on both the ^{18}F-FDG and ^{131}I uptake in PM from DTC [6]. There has been some debate about whether ^{18}F-FDG PET/CT should be performed under TSH stimulation for DTC patients [11-14]. Anyhow rhTSH is not available in China, therefore in our study PET scan was performed under THW. As showed ina previous study of ours, ^{18}F-FDG SPET/CT has lower sensitivity in the diagnosis of DTC recurrence with elevated Tg and negative ^{131}I scan than the ^{18}F-FDG PET/CT scan [7]. Therefore, the low sensitivity of ^{18}F-FDG SPET/CT may have limited diagnostic accuracy of the study.

Fluorine-18-FDG and ^{131}I avidity vary in PM of DTC which indicatesthe difference between glucose and iodine metabolism. As shown in this study, 30% of patients disclosed positive ^{18}F-FDG uptake and the majority of patients (57/83 could cumulate ^{131}I. This implies a more differentiated phenotype and therapeutic effect between ^{18}F-FDG and ^{131}I. Our results showed an inverse relationship between ^{131}I and ^{18}F-FDG metabolism in the majority of DTC PM (60/83). The high proportion of ^{18}F-FDG-negative lesions, demonstrated in our study, may indicate less aggressive growth of PM as compared with bone metastases. Of course, ^{18}F-FDG PET is of limited use in the very small PM of DTC.

Fluorine-18-FDG PET/CT scan-study is a valuable diagnostic method that can be used to make therapeutic decisions in patients with PM from DTC [15,16]. If ^{18}F-FDG PET results are negative, one course of ^{131}I treatment may be considered in high-risk patients with elevated Tg and negative ^{131}I scan for PM. If post therapy scan negative, no ^{131}I treatment is indicated [16]. Fluorine-18-FDG-avid metastases of DTC whether with or without ^{131}I uptake are resistant to ^{131}I therapy [17]. However, PM from DTC with ^{18}F-FDG-avidity may suggest refractory disease [7]. Only patients with ^{131}I-avid and ^{18}F-FDG-avid PM responded to ^{131}I therapy.

The lack of ^{18}F-FDG uptake in PM of DTC may predict good response to ^{131}I therapy as shown by our results based on tumor size on chest CT. Positive or negative ^{18}F-FDG uptake of the PM did not show statistical difference in terms of Tg changes in our study. This may be due to the limited number of patients includedand the detecting ability of Tg in our lab (Tg detection limits:1.59-1000ng/mL). In the subgroup analysis, the ^{18}F-FDG uptake patterns are not significant factors for the therapeutic response based on both CT and Tg. The reasons may also be the limited number of patients, less than 20 in the three subgroups. Iodine-131 therapy is the only systemic modality that has demonstrated therapeutic efficacy against severe PM from DTC [18]. As also shown by our analysis, none of the PM with negative ^{131}I uptake patients responded to ^{131}I therapy.

It is considered that ^{18}F-FDG-avid tumors tend to be less differentiated and more aggressive [19]. So, ^{18}F-FDG PET/CT

avidity of distant metastases can act as a prognostic factor in DTC patients correlated with higher mortality and shorter life span [20-22]. These studies included patients with all types of distant metastases and to our knowledge, few studies focused on ^{18}F-FDG/^{131}I uptake in PM from DTC [20-22]. Fluorine-18-FDG PET positive metastases are also a risk of cancer associated mortality [23]. About 50% of patients with PM die within 10 years [24, 25]. The resulting respiratory failure may be the most common cause of death [18]. In our study, during a less than 10 years follow-up, 8/83 patients died which confirmed the slow growth of PM in DTC. Anyhow, poor prognosis needs further study. Molecular targeting drugs may be indicated in these patients.

A couple of studies evaluated whole-body or bone marrow dosimetry using ^{131}I or ^{123}I [26, 27]. Recently, a study calculated the absorbed doses to normal organs including bone marrow, lung, heart, liver, and kidneytumors, per MBq of ^{131}I administered in patients with metastatic DTC on the basis of the ^{124}I PET/CT imaging and using the patient-specific 3D-RD software.These results suggested a high patient variability in the overall absorbed dose to normal organs per MBq of ^{131}I administered, between the two methods of stimulating TSH (THW vs rhTSH). The tumor absorbed dose per unit administered activity was higher in the THW study than in the rhTSH study for most of the tumors (~86%). In our study, ^{131}I was administered to our patients in a dose between 4.625-11.1GBq, empirically.

Limitations of our study were: The study was retrospective. The follow-up was relatively short (less than 10 years). In the subgroup analysis, for the evaluation ofthe therapeutic effects of ^{131}I, the number of patients was limited. Moreover, since the majority of PM tumors were <1cm in size, partial volume effect and respiratory motion could have significantly influenced the perception of ^{18}F-FDG-avidity.

In conclusion, ^{18}F-FDG avidity of PM from DTC patients predicates poor therapeutic effect on tumor size, disease progression and also less favorable prognosisand refractory disease. Iodine-131- avidity remains a key factor suggesting the possibility of a therapeutic effect on PM from DTC.

Funding

This study was funded by the National Natural Science Fund (grant number 81771859), Clinical Research Plan of SHDC (grant number 16CR3114B), and Shanghai Science and Technology Commission Project (grant number 18401901300).

The authors declare that they have no conflicts of interest.

Bibliography

1. Wu S, Wang H. Efficacy analysis of ^{131}I therapy and predictive value of preablation stimulated thyroglobulin for lung metastases from differentiated thyroid cancer. *Annales d'Endocrinologie* 2013; 74: 40-4.
2. Pitoia F, Bueno F, Cross G. Long-term survival and low effective cumulative radioiodine doses to achieve remission in patients with ^{131}Iodine-avid lung metastasis from differentiated thyroid cancer. *Clin Nucl Med* 2014;39:784-90.
3. Yoshio K, Sato S, Okumura Y et al. The local efficacy of I-131 for F-18 FDG PET positive lesions in patients with recurrent or metastatic thyroid carcinomas. *Clin Nucl Med* 2011;36:113-7.
4. Kim M, Kim WG, Park S et al. Initial Size of Metastatic Lesions Is Best Prognostic Factor in Patients with Metastatic Differentiated Thyroid Carcinoma Confined to the Lung. *Thyroid* 2017; 27: 49-58.
5. Ronga G, Filesi M, Montesano T et al. Lung metastases from differentiated thyroid carcinoma. A 40 years' experience. *Q J Nucl Med Mol Imaging* 2004; 48:12-9.
6. Terroir M, Borget I, Bidault F et al. The intensity of ^{18}F-FDG uptake does not predict tumor growth in patients with metastatic differentiated thyroid cancer. *Eur J Nucl Med Mol Imaging* 2016; 44: 638-46.
7. Ma C, Wang X, Shao M et al. ^{18}F-FDG SPECT/CT in the diagnosis of differentiated thyroid carcinoma with elevated thyroglobulin and negative iodine-131 scans. *Q J Nucl Med Mol Imaging* 2015; 59: 220-7.
8. Qiu ZL, Song HJ, Xu YH, Luo QY. Efficacy and survival analysis of ^{131}I therapy for bone metastases from differentiated thyroid cancer. *J Clin Endocrinol Metab* 2011; 96: 3078-86.
9. Ma C, Kuang A, Xie J, Ma T. Possible explanations for patients with discordant findings of serum thyroglobulin and ^{131}I whole-body scanning. *J Nucl Med* 2005; 46: 1473-80.
10. Haugen BR, Alexander EK, Bible KC et al. 2015 American Thyroid Association Management Guidelines for Adult Patients with Thyroid Nodules and Differentiated Thyroid Cancer: The American Thyroid Association Guidelines Task Force on Thyroid Nodules and Differentiated Thyroid Cancer. *Thyroid* 2016; 26: 1-133.
11. Vera P, Kuhn-Lansoy C, Edet-Sanson A et al. Does recombinant human thyrotropin-stimulated positron emission tomography with [^{18}F] fluoro-2-deoxy-D-glucose improve detection of recurrence of well-differentiated thyroid carcinoma in patients with low serum thyroglobulin? *Thyroid* 2010; 20: 15-23.
12. Grünwald F, Kälicke T, Feine U et al. Fluorine-18 fluorodeoxyglucose positron emission tomography in thyroid cancer: results of a multicentre study. *Eur J Nucl Med Mol Imaging* 1999; 26: 1547-52.
13. Wang W, Macapinlac H, Larson SM et al. [^{18}F]-2-fluoro-2-deoxy-D-glucose positron emission tomography localizes residual thyroid cancer in patients with negative diagnostic (131)I whole body scans and elevated serum thyroglobulin levels. *J Clin Endocr Metab* 1999; 84: 2291-302.
14. Ma C, Xie J, Lou Y et al. The role of TSH for ^{18}F-FDG-PET in the diagnosis of recurrence and metastases of differentiated thyroid carcinoma with elevated thyroglobulin and negative scan: a meta-analysis. *Eur J Endocrinol* 2010; 163: 177-83.
15. Chao M. Management of differentiated thyroid cancer with rising thyroglobulin and negative diagnostic radioiodine whole body scan. *Clin Oncol (R Coll Radiol)* 2010;22:438-47.
16. Ma C. Differentiated thyroid cancer with elevated thyroglobulin and negative radioiodine scan. *Thyroid Cancer-Diagnosis and Therapy* 2016: 147-70.
17. Yoshio K, Sato S, Okumura Y et al. The local efficacy of I-131 for F-18 FDG PET positive lesions in patients with recurrent or metastatic thyroid carcinomas. *Clin Nucl Med* 2011; 36: 113-7.
18. Song H-J, Qiu Z-L, Shen C-T et al. Pulmonary metastases in differentiated thyroid cancer: efficacy of radioiodine therapy and prognostic factors. *Eur J Endocrinol* 2015;173:399-408.
19. Feine U, Lietzenmayer R, Hanke JP et al. Fluorine-18-FDG and iodine-131-iodide uptake in thyroid cancer. *J Nucl Med* 1996;37: 1468-72.
20. Wang W, Larson SM, Fazzari M et al. Prognostic value of ^{18}F fluorodeoxyglucose positron emission tomographic scanning in patients with thyroid cancer. *J Clin Endocr Metab* 2000;85:1107.
21. Robbins RJ, Wan Q, Grewal RK et al. Real-time prognosis for metastatic thyroid carcinoma based on 2-[^{18}F]fluoro-2-deoxy-D-glucose-posit-ron emission tomography scanning. *J Clin Endocr Metab* 2006; 91: 498.
22. Deandreis D, Al GA, Leboulleux S et al. Do histological, immunohistochemical, and metabolic (radioiodine and fluorodeoxyglucose uptakes) patterns of metastatic thyroid cancer correlate with patient outcome? *Endocrine-Related Cancer* 2011;18:159.
23. Wang W, Larson SM, Fazzari M et al. Prognostic value of [^{18}F]-fluorodeoxyglucose positron emission tomographic scanning in patients with thyroid cancer. *J Clin Endocrinol Metab* 2000;85: 1107-13.
24. El Hadidy el HM, Ghonaim M, El Gawad S, El Atta MA. Impact of severity, duration, and etiology of hyperthyroidism on bone turnover markers and bone mineral density in men. *BMC Endocr Disord* 2011; 11: 15.

and bone mineral density in men. *BMC Endocr Disord* 2011; 11: 15.
25. Mazzaferri EL, Kloos RT. Clinical review 128: Current approaches to primary therapy for papillary and follicular thyroid cancer. *J Clin Endocrinol Metab* 2001; 86: 1447-63.
26. Potzi C, Moameni A, Karanikas G et al. Comparison of iodine uptake in tumour and nontumour tissue under thyroid hormone deprivation and with recombinant human thyrotropin in thyroid cancer patients. *Clin Endocrinol (Oxf)* 2006; 65: 519-23.
27. Freudenberg LS, Jentzen W, Petrich T et al. Lesion dose in differentiated thyroid carcinoma metastases after rhTSH or thyroid hormone withdrawal: 124I PET/CT dosimetric comparisons. *Eur J Nucl Med Mol Imaging* 2010;37: 2267-76.

Figure from El Naranjo, Central Veracruz, with exposed heart in place of navel, mythical location for center of world as well as human life. Museo National de Anthropologia, Mexico