High standardized uptake values of ^{18}F-FDG PET/CT imaging but not MRI correlates to pathology findings in patients with cervical cancer

Zhi Yang[1*] MD,
Jun-rong Wu[2*] MM,
Lin-Lin Wei[1] MM,
Guang-xin Liao[1] BE,
Cai-juan Yang[1] MB,
Guan-qiao Jin[3] MD,
Guo-you Xiao[1] MB,
Dan-ke Su[3] MD

**These authors have contributed equally to this work.*

1. Department of Nuclear Medicine, and
2. Department of Clinical Laboratory, and
3. Department of Radiology, of The Affiliated Tumor Hospital of Guangxi Medical University, Nanning, 530021, Guangxi, China.

Keywords: Cervical cancer
- Positron emission tomography
- Standardized uptake value
- Magnetic resonance imaging
- Apparent diffusion coefficient

Corresponding authors:
Dan-ke Su MD,
Department of Radiology,
The Affiliated Tumor Hospital of Guangxi Medical University,
Nanning 530021, Guangxi, China.
Tel: +86-07715334950;
Fax: +86-07715334950
sudanke33@sina.com; and
Guo-you Xiao MB,
Department of Nuclear Medicine,
The Affiliated Tumor Hospital of Guangxi Medical University,
Nanning, 530021, Guangxi, China.
Tel: +86-07715333501;
Fax: +86-07715333501
xgy725@aliyun.com;

Received:
7 May 2019
Accepted revised:
1 June 2019

Abstract

Objective: This study was to explore the correlation between the standardized uptake value (SUV) of fluorine-18-fluorodeoxyglucose positron emission tomography/computed tomography (^{18}F-FDG PET/CT) imaging and the apparent diffusion coefficient (ADC) value of magnetic resonance imaging (MRI) to the pathological features of cervical cancer (CC). **Subjects and Methods:** The maximum and mean SUV of ^{18}F-FDG PET/CT (SUVmax and SUVmean) and the minimum ADC (ADCmin) were collected from 72 patients with CC. The correlation between SUVmax and ADCmin was also assessed. Furthermore, the relationship between SUVmax, SUVmin, ADCmin and the clinical pathological characteristics of CC was analyzed. **Results:** A significant increase in the SUVmax was observed in the group of CC cases with lymph node metastases and in the group with distant metastases compared to those without metastases (F=6.782, P=0.002; F=4.483, P=0.015). Furthermore, in the low differentiation groups compared to high/middle differentiation groups (F=3.342, P=0.024), in the squamocellular carcinoma groups compared to the adenocarcinoma and adenosquamous carcinoma groups (F=3.295, P=0.026) and finally in the International Federation of Gynecology and Obstetrics (FIGO) stage III-IV groups compared with stage III-IV groups (F=3.123, P=0.020). The SUVmean values of the lymph node metastases and distant metastases groups were significantly higher than those without lymph node metastases (F=5.802, P=0.005; F=3.486, P=0.036). We saw no correlation between the ADCmin and lymph node metastases. The SUVmax value had weak correlation with the ADCmin (r=-0.306, P=0.036).The SUVmaxis most closely related to the clinical pathological characteristics of CC. **Conclusions:** An increased SUVmax suggests lymph node metastases or distant metastasis, low differentiation and FIGO stage III-IV. A low negative correlation was observed between the SUVmax and ADCmin, while we observed no correlation between the ADCmin and the clinical pathological characteristics of cervical cancer.

Hell J Nucl Med 2019; 22(2): 96-102 *Epub ahead of print: 7 July 2019* *Published online: 20 July 2019*

Introduction

Cervical cancer(CC) is the third most common tumor in women, ranking fourth in the number of deaths from gynecological tumors [1]. Cervical cancer has a recurrence rate of 30% and a 5 years survival rate of approximately 73% following system treatment especially among HIV seropositive patients [2], and its prognosis is related to the scope of invasion and metastases of the primary tumor. Thus, early diagnosis, accurate staging and close follow-up after treatment are of particular importance.

Both magnetic resonance imaging (MRI) and positron emission tomography/computed tomography (PET/CT) can provide important functional information regarding CC. Fluorine-18-fluorodeoxyglucse (^{18}F-FDG) PET/CT showed improved performance over MRI and CT and is now recommended by the National Comprehensive Cancer Network (NCCN), as guidelines for the routine assessment and for evaluating the clinical condition and stage of patients with CC especially for ≤stage IB1. The implementation of diffusion weighted magnetic resonance imaging (DWI) in oncologic imaging has improved tumor characterization, cancer detection, outcome prediction and treatment monitoring [3]. Multiple studies have demonstrated a high association between reduced minimum apparent diffusion coefficient (ADCmin) diffusion weighted magnetic resonance imaging (DWI) values of different tumor entities and tumor aggressiveness, the risk of metastases and/or tumor recurrence [4, 5]. The strongest metabolic uptake is represented by maximum standardize uptake value (SUVmax), which yields a strong association to tumor aggressiveness and patient prognosis [6]. However, the studies of the SUVmax and the ADCmin to the evaluation of CC are relatively limited.

The purpose of this study was to assess the reproducibility of ADCmin and SUVmax

measurements in patients with CC, to evaluate whether ADCmin and SUVmax are statistically correlated and to find out a more directional imaging index for the staging of CC.

Subjects and Methods

Study design and patients selection

This retrospective study was approved by the Institutional Ethics Committee and was performed in accordance with the guidelines of the Helsinki II Declaration. Informed consent was waived. Inclusion criteria were: adult patients with histologically proven CC who had undergone whole body ^{18}F-FDG PET/CT and pelvic DWI prior to treatment (mean delay of 3 days between examinations). A computerized search of the Picture Archiving and Communication system (PACS) archives and medical records of our institution (during of September 2017 and December 2018) retrospectively identified 72 consecutive patients with CC (mean age of 55.7 years; range 37-71 years). We excluded 25 patients from the study due to a lack of DWI imaging or poor imaging quality due to distortion caused by metal implants. Thus, only 47 patients were finally analyzed in order to evaluate the relationship between DWI and PET/CT. Tumor size was recorded as the longest diameter measured in the transverse section according to response evaluation criteria in solid tumors (RECIST) which averaged 5.26±1.55cm (range 1.10-8.90cm). Of the tumors, 39 were poorly differentiated or undifferentiated, 31 were moderately differentiated and 2 were well differentiated.

^{18}F-FDG PET/CT scan

Image acquisition was performed using a GE Discovery 710 PET/CT scanner. Positron emission tomography/CT was performed following the administration of 5.55MBq/kg body weight of ^{18}F-FDG, which was injected through the cubital veins peripheral venous. Serum glucose levels were below 150 mg/dL before administration of ^{18}F-FDG. Positron emission tomography/CT images were obtained approximately 60 minutes after injection of ^{18}F-FDG whilst drinking 450mL mineral water. All patients underwent non-contrast CT followed by PET scans from the head to mid-thigh level, which consisted of seven or eight bed positions with 2.0min/table position [7]. Positron emission tomography images were scatter-corrected and reconstructed using an ordered-subsets expectation maximization iterative reconstruction algorithm and a post reconstruction gaussian filter (3mm full-width half maximum). A technical parameter for the 64-detector-row helical CT scanner produced a section thickness of 3.27mm. Images were obtained from the basis cranii to the proximal thighs at140kV and 110mAfor attenuation correction and diagnosis.

MRI scan

Magnetic resonance imaging was performed using a 3.0 Tesla (T) clinical MR imaging system (Discovery MR 750w, GE Healthcare, America) equipped with a dedicated eight-channel phased array pelvic coil in the supine position. Diffusion weighted magnetic resonance imagingimages were acquired in the axial planes using an echo-planar imaging sequence, parallel imaging with sensitivity encoding (acceleration factor of two), fat suppression (in a spectral selective attenuated inversion-recovery sequence), volume shimming, b values of 0 and 1000sec/mm^2, TR/TE/TI = 5725/73.9ms, a 4.0mm section thickness, a 1.0mm intersection gap, a field of view of 36×36cm, and a matrix of 96×128. Apparent diffusion coefficient maps were created automatically by the system from trace-weighted images with b values of 0 and 1000sec/mm^2. Regions of interest (ROI) were drawn manually along the border of tumor on ADC figures to cover the entire lesion area, whilst obvious necrotic, liquescent, haemorrhagic, cystic, or calcified areas were excluded.

Image analysis

Image analysis was performed by a radiologist and a nuclear medicine physician with 15 and 32 years of experience in reading MRI and PET/CT imaging using post-processing software (GE Aw4.6). All tumor lesions were identified on DWI (b=0) and an ROI was manually drawn encompassing the entire target lesion. Following automatic transfer and visual confirmation of correct placement onto the corresponding parameter map, the ADCmin was determined.

Statistical analysis

Statistical analysis was performed using the IBM Statistic Package for Social Science (SPSS) version 21.0 (SPSS Inc, Armonk, NY, USA). Descriptive analysis was used to assess SUVmax, SUVmean and ADCmin values and data were expressed as the mean±standard deviation (SD) (x±SD). Pearson's correlation coefficient analysis was used to evaluate the relationship between ADCmin and SUV (SUVmean,SUVmax). According to the classification system provided by Salkin, R-values between 0.8 and 1.0 represent a very strong correlation, 0.6-0.8 a strong correlation, 0.4-0.6 a moderate correlation and 0.2 -0.4 a weak correlation. A P-value<0.05 was considered to indicate statistical significance.

Results

All PET/CT images of patients with cervical cancer displayed an increased cervical volume, soft tissue density mass, and increased ^{18}F-FDG uptake in the lesion area. There were 47 cases (65.3%) of lymph node metastases and 17 cases of distant metastases (23.6%), including (more) lung metastases (5 cases), liver metastases (4 cases), osseous metastasis(iliac crest metastases 3 cases, pubic metastases 2 cases and Lumbar metastasis 1 case), clavicle lymph node metastases (2 cases). The correlation coefficient between the SUVmax and the lesion diameter was: r=0.336 (P=0.004). As the lesion's size increased, the SUVmax increased, which was of statistical significance (P=0.004). Accordingly, when comparing SUVmax changes, covariance analysis was used to eliminate the influence of lesion size (Table 1). An increased SUVmax suggested an increased likelihood of lymph node metastasis (P=0.002), (example shown in Figure 1A and B) and distant organ metastasis (P=0.015) (example shown in Figure 1C).

Table 1. Comparison of the mean SUVmax values of the 72 patients with cervical cancer.

Grouping	Number of cases	SUVmax	F-value	P-value
Lymph node metastases				
Yes	47	19.426±8.174		
No	25	14.100±4.627	6.782	0.002
Distant metastases				
Yes	17	19.541±5.834		
No	55	16.969±7.958	4.473	0.015
Degree of differentiation				
Poor	39	18.292±9.159		
Moderate	31	16.652±5.000		
Well differentiated	2	17.950±7.553	3.342	0.024
Pathological classification				
Squamous cell carcinoma	66	17.882±7.786		
Adenocarcinoma	3	13.467±2.822		
Mixed carcinoma	3	14.967±2.871	3.295	0.026
FIGO staging				
I	6	15.483±5.013		
II	21	14.071±4.681		
III	35	19.814±8.862		
IV	10	18.360±6.239	3.123	0.020

Note: SUVmax: application of the maximum standard uptake values; FIGO: International Federation of Gynecology and Obstetrics. Mean diameter of the primary tumor lesion=5.257cm as the boundary analysis; P< 0.05 was statistically significant.

(A) Patient 62 years old, vaginal irregular bleeding for 2 years, cervical tumor biopsy pathological results: squamous cell carcinoma. Positron emission tomography/CT showed the size of the cervical mass was about 5.1x3.5cm and SUVmax was 12.5. No lymph node metastases and distant metastases.

(B) Patient 58 years old, irregular vaginal bleeding for more than 10 days. The pathological results of cervical neoplasm biopsy showed: cervical high grade squamous intraepithelial lesions (CINIII). Positron emission tomography/CT showed the size of the cervical mass is about was about 4.4x3.7cm and SUVmax was 20.9. Lymph node metastases of bilateral iliac vessels, no distant metastases.

(C) Patient 47 years old, vaginal bleeding after bedtime for more than a year cervical biopsy showed: keratocytic squamous cell carcinoma. Positron emission tomography/CT showed the size of the cervical mass was about 6.8x5.0cm and SUVmax was 31.2. Lymph node in bilateral iliac vessels and liver metastases.

Correlation coefficient r=0.229 between the SUVmean and lesion diameter. As the lesion size increased, the SUVmean significantly increased (P=0.011). Thus, when comparing differences in the SUVmean, covariance analysis was used to eliminate the influence of lesion size (Table 2).

As said before, only 47 of the 72 patients underwent DWI examination and had relatively clear ADC images, including 33 cases with lymph node metastases (70.2%) and 13 cases with distant metastases (27.7%) (Table 3).

The correlation coefficient between the SUVmax and ADCmin was r=-0.306, the difference between which was statistically significant (P=0.036) (scatter diagram is shown in Figur e 2).

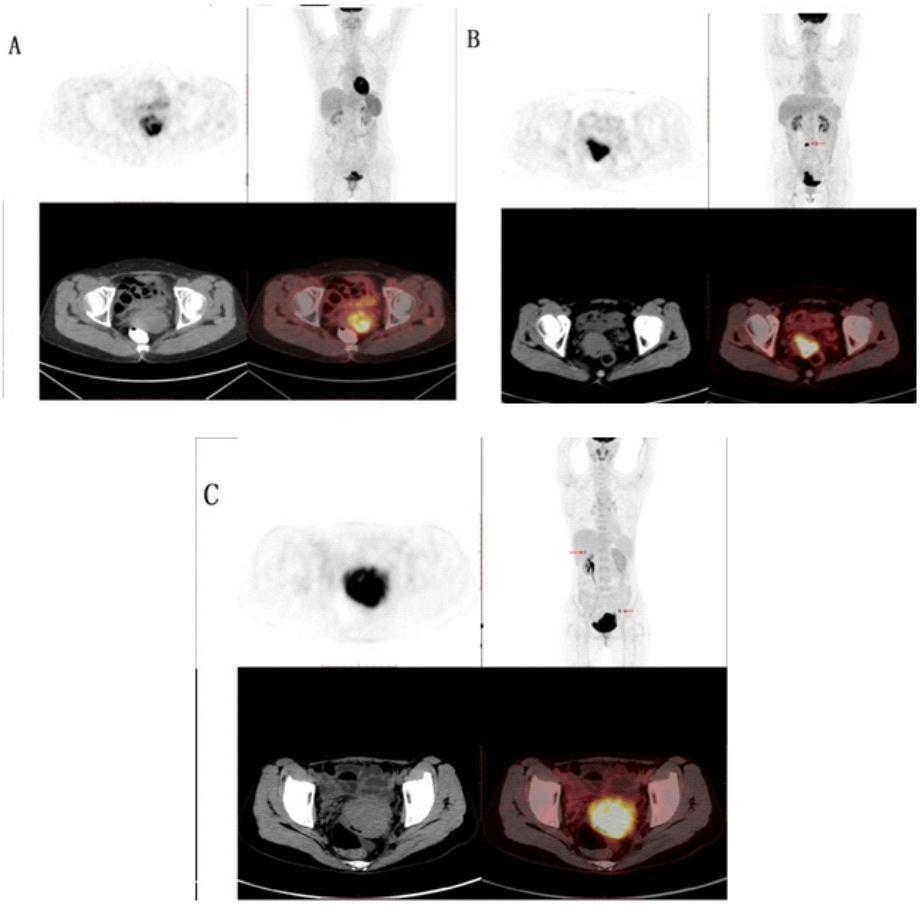

Figure 1. Without lymphatic metastases (A) vs. lymphatic metastases (B) (SUVmax: 12.5 vs 20.9). Hepatic metastases (C), SUVmax: 31.2.

Table 2. *Comparison of the mean SUVmean values of the 72 patients with cervical cancer.*

Grouping	Number of cases	SUVmean	F-value	P-value
Lymph node metastases				
Yes	47	11.330±4.852		
No	25	8.240±2.819	5.802	0.005
Distant metastases				
Yes	17	11.365±3.200		
No	55	9.915±4.789	3.486	0.036
Degree of differentiation				
Poorly	39	10.621±5.401		
Moderately	31	9.755±3.023		
Well differentiated	2	10.950±5.728	2.611	0.058

(continued)

Pathological classification				
Squamous cell carcinoma	66	10.418±4.628		
adenocarcinoma	3	8.100±1.825		
Mixed carcinoma	3	8.867±2.146	2.536	0.064
FIGO staging				
I	6	9.083±2.930		
II	21	8.081±2.810		
III	35	11.574±5.277		
IV	10	10.920±3.483	2.880	0.029

Note: SUVmean: the mean standard uptake values; FIGO: International Federation of Gynecology and Obstetrics. Mean diameter of the primary tumor lesion=5.257cm as the boundary analysis; P<0.05 was statistically significant.

Table 3. *Comparison of the mean ADCmin values of 47 patients with cervical cancer.*

Grouping	Number of cases	ADCmin	F-value	P-value
Lymph node metastases				
Yes	33	0.830±0.122		
No	14	0.807±0.105	-0.611	0.544
Distant metastases				
Yes	13	0.796±0.085		
No	34	0.836±0.127	-1.050	0.299
Degree of differentiation				
Poorly	26	0.804±0.097		
Moderately	19	0.848±0.142		
Well differentiated	2	0.895±0.028	1.161	0.323
Pathological classification				
Squamous cell carcinoma	44	0.829±0.114		
adenocarcinoma	2	0.747±0.237		
Mixed carcinoma	1	0.872	0.532	0.591
FIGO staging				
I	4	0.893±0.095		
II	13	0.772±0.105		
III	27	0.851±0.120		
IV	3	0.741±0.036	2.524	0.070

Note: ADCmin: the minimum apparent diffusion coefficient; FIGO: International Federation of Gynecology and Obstetrics. P<0.05 was statistically significant.

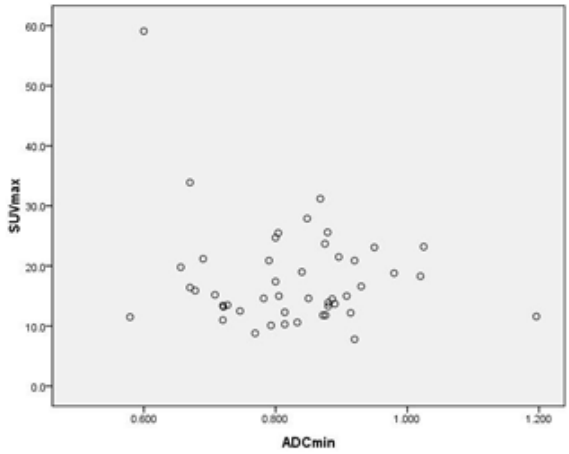

Figure 2. Scatter diagram showing the correlation between the ADCmin and SUVmax. The relationship between ADCmin and SUVmax is a linear (r=-0.306, P=0.036).

Discussion

The major metastases of cervical cancer are directby spread and lymphatic metastases, whilst blood metastases are rare. Tumor cells flow with the lymphatic fluid into local lymph nodes and spread in lymphatic vessels. Lymphatic metastases include parauterine, pericervical, obturator, internal iliac, external iliac, common iliac and anterior sacral lymph nodes. In this study, we found that 47 (65.3%) patients had lymph node metastases, which occurred primarily in the abdominal aorta and iliac blood vessels on both sides, while 8 cases had metastases after direct bladder or ureter invasion. This suggests that cervical cancer is prone to lymph node metastases, local invasion, but a few distant metastases.

Fluorine-18-FDG PET/CT includes information regarding the glucose metabolism of cells which can be measured using the SUVmax. Diffusion weighted magnetic resonance imaging provides functional imaging based on an assessment of the random motion of extracellular water molecules, which can reflect cell proliferation. Recent imaging studies on gastrointestinal tumors [8], lung cancer and cervical cancer [9], have shown that the SUV negatively correlates with the ADC. Although the SUVmax and SUVmean have the same meaning, the majority of studies adopt the SUVmax, which are objective and do not rely on an operator or artificial sketches of ROI sizes [10,11]. Previous studies [12] have shown that the SUVmax significantly correlates with cervical cancer FIGO staging (P=0.036), tumor diameter (P=0.018) and lymph node metastases (P=0.044). This study compared the relationship between cervical lesion size and SUVmax values and found that as the lesion size increased, significant increases in the SUVmax (P=0.004). Thus, covariance analysis was used to eliminate the influence of focus size on SUVmax when comparing the differences of SUVmax. The differences in SUVmax and SUVmean values in patients with or without lymphatic metastases were statistically significant (the greater the SUVmax and SUVmean, the increased occurrence of lymph node metastases, P=0.002&0.005, respectively). Blood metastasis from CC is relatively rare and can be transferred to lung, liver or bone. We observed 17 cases of distant metastases (23.6%), including lung metastases (5 cases), liver metastases (4 cases) and iliac bone metastases (3 cases).The differences in the SUVmax and SUVmean values in primary tumors with or without distant metastases were statistically significant (P=0.015&0.036, respectively). The majority patients had low or moderate differentiation (97.2%), the pathological types were mainly squamous cell carcinomas (91.7%), and the clinical stage was mostly III (48.6%). Covariance analysis showed that the SUVmax values of low differentiation were 18.292±9.159, which was higher than moderately and well differentiated (P=0.024). The average SUVmax values of squamous cancer were 17.882±7.786, which were higher than adenocarcinoma and mixed carcinoma (P=0.026). In FIGO staging, the SUVmax was lower for stage I-II patients, compared to stage III-IV patient(P=0.020).

There is no definite conclusion on the correlation between the SUVmax and ADCmin. Ho and coworkers(2009) [9] showed that the SUVmax and ADCmin/ADCmean were negatively correlated, whilst the SUVmax and ADCmin did not significantly correlate. Gu and his colleagues (2011) [13] reported that the SUVmax negatively correlates with the ADCmin and that the SUVmean and ADCmean negatively correlate in colon cancer patients. In studies of head and neck squamous cell carcinoma, Varoquaux and his colleagues(2013) [14] believed that there was a trend of low ADC and high SUV values in malignant tumors. Patients with cervical cancer in this study displayed similar results. As the ADCmin is less likely to be affected by human error when delineating the area of interest, this study directly evaluates the relationship between ADCmin values and the clinical pathology of cervical cancer. The ADCmin values with and without lymph node metastasis, distant metastasis, the degree of differentiation, pathological type and FIGO stage did not statistical significance. However, we observed a tendency for the values to decline in distant metastasis and in poorly differentiated tumors. It has been previously shown that as the SUVmax values of lesions decreases, the ADCmin values rise in comparison [8]. The mean SUVmax and ADCmin values showed a weak negative correlation (r=-0.342, P<0.05) [8]. Thus, similar to previous studies, the correlation between SUVmax and ADCmin was a weak negative correlation in our study, with a correlation coefficient of r=-0.306 (P=0.036).We therefore propose that a certain degree of negative correlation between SUVmax and ADCmin exists, but the combination of SUVmax and ADCmin more accurately defines the biological behavior of patients with cervical cancer.

Limitation of the study

The disadvantage of this study was that the number of cases were small and it was not a randomized controlled study. Some patients did not receive MRI examination, and the evaluation of the ADC graphs was influenced by human errors, which may affect the accuracy of SUVmax and ADCmin comparisons. Nevertheless, statistics strongly supported our conclusion.

In conclusion, the SUVmax values following ^{18}F-FDG PET/CT imaging of patients with cervical cancer displays a good cor-

relation with clinical pathology. Increased SUVmax values indicate metastases, poor differentiation and a high FIGO stage. We observed a weak negative correlation between the SUVmax and ADCmin, but saw no clear correlation between ADCmin and tumor pathology.

Acknowledgements
All procedures performed in this study were in accordance with the ethical standards of the 1964 Helsinki declaration and its later amendments. This study was approved by the Ethics Committee of Affiliated Tumor Hospital of Guangxi Medical University(Nanning, China).

Funding
This work was in part supported by Health Committee of Guangxi Zhuang Autonomous region China(Z20170436) and Science and Technology Department of Guangxi (2016AB09066).

The authors declare that they have no conflicts of interest.

Bibliography

1. Torre LA, Bray F, Siegel RL et al. Global cancer statistics, 2012. *CA Cancer J Clin* 2015; 65:87-108.
2. Ololade K, Mokgoro N P, Lawal I O et al. A comparison of ^{18}F-FDG PET/ CT findings in HIV positive compared to HIV negative patients with recurrent cervical cancer. *Hell J Nucl Med* 2017; 20 Suppl: 71-9.
3. Punwani S. Diffusion weighted imaging of female pelvic cancers: concepts and clinical applications. *Eur J Radiol* 2011; 78: 21-9.
4. Elmi A, Hedgire SS, Covarrubias D et al. Apparent diffusion coefficient as a non-invasive predictor of treatment response and recurrence in locally advanced rectal cancer. *Clin Radiol* 2013; 68: e524-531.
5. Nakamura K, Imafuku N, Nishida T et al. Measurement of the minimum apparent diffusion coefficient (ADCmin) of the primary tumor and CA125 are predictive of disease recurrence for patients with endometrial cancer. *Gynecol Oncol* 2012; 124:3 35-9.
6. Tong AN, Han SR, Yan P et al. Prognostic value of FDG uptake in primary inoperable non-small cell lung cancer. *Med Oncol* 2014; 31:780.
7. Martins EB, Chojniak R, Kowalski LP et al. Diffusion-Weighted MRI in the Assessment of Early Treatment Response in Patients with Squamous-Cell Carcinoma of the Head and Neck: Comparison with Morphological and PET/CT Findings. *PLoS One* 2015; 10:e0140009.
8. Wong CS, Gong N, Chu YC et al. Correlation of measurements from diffusion weighted MR imaging and FDG PET/CT in GIST patients: ADC versus SUV. *Eur J Radiol* 2012; 81: 2122-6.
9. Ho KC, Lin G, Wang JJ et al. Correlation of apparent diffusion coefficients measured by 3T diffusion-weighted MRI and SUV from FDG PET/CT in primary cervical cancer. *Eur J Nucl Med Mol Imaging* 2009; 36: 200-8.
10. Burger IA, Huser DM, Burger C et al. Repeatability of FDG quantification in tumor imaging: averaged SUVs are superior to SUVmax. *Nucl Med Biol* 2012; 39: 666-70.
11. Fruehwald-Pallamar J, Czerny C, Mayerhoefer ME et al. Functional imaging in head and neck squamous cell carcinoma: correlation of PET/CT and diffusion-weighted imaging at 3 Tesla. *Eur J Nucl Med Mol Imaging* 2011; 38: 1009-19.
12. Nakamura K, Joja I, Kodama J et al. Measurement of SUVmax plus ADCmin of the primary tumour is a predictor of prognosis in patients with cervical cancer. *Eur J Nucl Med Mol Imaging* 2012; 39: 283-90.
13. Gu J, Khong PL, Wang S et al. Quantitative assessment of diffusion-weighted MR imaging in patients with primary rectal cancer: correlation with FDG-PET/CT. *Mol Imaging Biol* 2011; 13: 1020-8.
14. Varoquaux A, Rager O, Lovblad KO et al. Functional imaging of head and neck squamous cell carcinoma with diffusion-weighted MRI and FDG PET/CT: quantitative analysis of ADC and SUV. *Eur J Nucl Med Mol Imaging* 2013; 40: 842-52.