^{18}F-FDG PET/CT and histology for diagnosing recurrent/remnant tumors in head and neck cancer patients treated with radiotherapy

Eun Ji Han[1] MD,
Joo Hyun O[2] MD,
Ie Ryung Yoo[2] MD,
Yeon Sil Kim[3] MD,
Min Sik Kim[4] MD,
Jin Hyoung Kang[5] MD,
Woo Hee Choi[6] MD

1. Department of Radiology, Daejeon St. Mary's Hospital, College of Medicine, The Catholic University of Korea, Daejeon, South Korea
2. Department of Radiology, Seoul St. Mary's Hospital, College of Medicine, The Catholic University of Korea, Seoul, South Korea
3. Department of Radiation Oncology, Seoul St. Mary's Hospital, College of Medicine, The Catholic University of Korea, Seoul, South Korea
4. Department of Otolaryngology-Head and Neck Surgery, Seoul St. Mary's Hospital, College of Medicine, The Catholic University of Korea, Seoul, South Korea
5. Department of Internal Medicine, Seoul St. Mary's Hospital, College of Medicine, The Catholic University of Korea, Seoul, South Korea
6. Department of Radiology, St. Vincent's Hospital, College of Medicine, The Catholic University of Korea, Suwon, South Korea

Keywords: Head and neck cancer
-Radiotherapy -^{18}F-FDG PET/CT
-Locoregional disease
-Diagnostic accuracy

Corresponding author:
Woo Hee Choi, MD Department of Radiology, St. Vincent's Hospital, College of Medicine, The Catholic University of Korea 93, Jungbu-daero, Paldal-gu, Suwon-si, Gyeonggi-do 16247, South Korea, Tel: 82-31-249-8494, Fax: 82-31-247-5713
wh0522@catholic.ac.kr

Received:
29 March 2017
Accepted revised:
5 May 2017

Abstract

Objectives: The aim of this study was to assess the diagnostic performance of fluorine-18-fluoro-2-deoxy-glucose (^{18}F-FDG) positron emission tomography (PET)/computed tomography (CT) for locoregional recurrent/residual tumor in patients with head and neck cancer (HNC) who underwent previous radiotherapy (RT). **Subjects and Methods:** ^{18}F-FDG PET/CT images from patients with HNC who previously underwent RT were retrospectively reviewed. Only cases with histological confirmation within 4 weeks of PET/CT imaging were included. Standardized uptake values were obtained for lesions and PET/CT findings were compared with histological results. **Results:** Of 181 cases, 114 (63%) were histologically confirmed as malignant and 67 (37%) as benign. The sensitivity, specificity, and accuracy of PET/CT were 93%, 64%, and 82%, respectively. Inflammation was the most common cause of false positives and small tumor volume and low ^{18}F-FDG avidity were the causes of false negatives. PET/CT had 100% sensitivity and 56% specificity for detecting recurrent or residual disease within 12 weeks after RT and 93% sensitivity and 64% specificity, more than 12 weeks after RT. The frequency of false positives in PET/CT images within 12 weeks of RT was similar to the results obtained 12 weeks after RT (15% vs. 14%). False positives were more frequent in PET/CT cases after two-dimensional or three-dimensional conformal RT than in those after intensity-modulated RT, although not statistically significant (15% vs. 9%, $p>0.05$). **Conclusion:** ^{18}F-FDG PET/CT might aid the diagnosis of locoregional residual/recurrent tumors in patients with HNC previously treated with RT. Inflammation was the main cause of false positives regardless of the interval between RT and PET/CT, even several years after RT. Therefore, histological verification of positive PET/CT findings should be conducted during follow-up of HNC patients treated with RT.

Hell J Nucl Med 2017; 20(2): 134-140 *Epub ahead of print: 12 July 2017* *Published online: 8 August 2017*

Introduction

Fluorine-18-fluoro-2-deoxyglucose (^{18}F-FDG) is a glucose analog. Phosphorylated glucose continues along the glycolytic pathway, but phosphorylated 18F-FDG cannot enter glycolysis and remains trapped within malignant cells [1]. Based on this phenomenon, ^{18}F-FDG positron emission tomography (PET) and PET/computed tomography (CT) are used for staging, restaging, monitoring response to treatment, and surveillance of patients with head and neck cancer (HNC) and can change their management plans [2-4]. However, in the absence of malignant involvement, degree of ^{18}F-FDG uptake varies in the tonsils, palate, floor of mouth, salivary glands, and muscles of the oropharynx, nasopharynx, and larynx [1, 5-7]. Normal physiological uptake in these areas can show an asymmetric pattern, while cancer can be hidden in symmetry to make interpretation of PET/CT images more difficult [6, 8]. Small-volume tumors can further elude detection because they can have a low tumor-to-background ratio [9, 10].

Head and neck cancer is treated using various combinations of chemotherapy, radiotherapy (RT), and surgery. Radiotherapy is a favored option for early stage definitive therapy; it is also included in the treatment strategy for most advanced-stage cancers, especially, with intensity-modulated RT (IMRT), widely available [11]. However, RT can induce blood vessel damage, inflammatory processes, and cell death [12]. Interpretation of ^{18}F-FDG PET/CT images can be hampered after RT because of acute and late complications such as soft-tissue necrosis, osteoradionecrosis, and radiation fibrosis. Furthermore, RT can alter physiologic metabolism in the head and neck region and surgery can alter head and neck anatomy. These factors can also make interpretation of PET/CT images difficult [1, 7].

The purpose of this study was to evaluate the diagnostic performance of ^{18}F-FDG PET/CT

related to histology for detecting recurrent or residual disease within the radiation field of patients with HNC who previously underwent locoregional RT. In addition, we analyzed the causes of false positives and false negatives with the intent of enhancing diagnostic accuracy.

Subjects and Methods

Patients

A total of 2994 PET/CT cases performed for evaluation of HNC from January 2004 to December 2013 were retrospectively reviewed. Inclusion criteria were patients with proven extra-cranial HNC previously treated with RT for primary tumors and metastatic lymph nodes and histological confirmation of the locoregional lesion in question within 4 weeks of PET/CT imaging. Patients with thyroid cancer, malignant lymphoma, or soft tissue sarcoma were excluded. Clinicopathological variables such as age, sex, primary tumor site, histologic type, and history of prior treatment were obtained from electronic medical records.

In addition, RT data such as the modality, total dose, and date of completion of treatment were collected. Almost all patients were treated on a linear accelerator (linac), with immobilization in the standard supine position. The prescribed dose was 1.8-2.2 Gy per fraction and was administered 5 days a week. The two-dimensional RT (2D-RT) was administered using planar X-ray. For three-dimensional conformal RT (3D-CRT) and IMRT, CT was performed in the treatment position and subsequently, the gross tumor, clinical target, planning target, and organs at risk volumes were contoured according to the consensus guidelines.

This study was performed in accordance with the approved guidelines of our hospital's institutional review board. The ethical committee of our institution waived the requirement for informed consent for retrospective review of imaging studies.

^{18}F-FDG PET/CT imaging

All patients fasted at least 6 hours before ^{18}F-FDG PET/CT, which was performed 60 minutes after intravenous administration of 370-444MBq ^{18}F-FDG. Blood glucose for all patients was lower than 160mg/dL before ^{18}F-FDG injection. Imaging for all patients was obtained using integrated PET/CT scanner (Biograph Duo or Biograph Truepoint; Siemens Medical Solutions, Knoxville, TN). All patients were placed in a supine position with arms at the sides. CT scanning was initiated at the orbitomeatal line or vertex of the skull and progressed down toward the upper thigh using a standard protocol: 130kVp, 30mA, 5-mm slice thickness (Biograph Duo); 120kV, 50mA, 5-mm slice thickness (Biograph Truepoint). Immediately after CT, PET imaging was conducted over the same target area. Acquisition time per bed position was 2-3 minutes. PET data were reconstructed using CT data for attenuation correction and using a standard ordered-subset expectation maximization algorithm. When dental prostheses caused beam-hardening artifacts, PET images uncorrected for attenuation were obtained.

Image interpretation

Two board-certified physicians in both nuclear medicine and radiology interpreted PET/CT images by visual inspection, without knowledge of patient status. Local and regional sites within the field of previous RT were independently assessed regardless of the presence of distant disease. A po-sitive PET/CT finding was defined as increased ^{18}F-FDG upta-ke that exceeded uptake seen in the adjacent background and was consistent with locoregional recurrent or residual disease. In regions with physiologically increased ^{18}F-FDG uptake, asymmetrically increased uptake was interpreted as positive. Disagreements of interpretation were resolved by consensus between the two readers. For perceptible ^{18}F-FDG uptake in the locoregional area, maximum standardized uptake value (SUV) of the lesion was recorded.

Statistical analysis

Categorical variables were expressed as absolute number and percentage and continuous variables as median or mean±standard deviation (SD) and range. Sensitivity, specificity, positive predictive value (PPV), negative predictive value (NPV), and accuracy of PET/CT were calculated for detection of recurrent or residual disease. Independent sample t-tests were used to compare SUV between tumor-positive and tumor-negative groups. Because post-treatment PET/CT is generally recommended longer than 12 weeks after completion of RT [13, 14], we divided PET/CT studies performed before and after 12 weeks following RT and calculated sensitivity and specificity for each subgroup. P value <0.05 was considered to indicate statistical significance. All statistical analyses were performed using Statistical Package for the Social Sciences software version 21.0 (IBM, Armonk, NY, USA) and MedCalc version 17.5 (MedCalc Software, Ostend, Belgium).

Results

In total, 181 PET/CT cases of 153 patients (121 men, 32 women; mean age, 59 years) were included in this study. General patient characteristics are in Table 1. The interval from completion of RT to PET/CT imaging varied from 0 to 950 weeks (median, 52). Of the 181 cases, 114 (63%) were histologically diagnosed as recurrent or residual disease and 67 (37%) were histologically negative. Of the PET/CT images, 131 (72%) were interpreted as positive and 50 (28%) as negative. For detection of locoregional recurrent or residual disease, PET/CT had a sensitivity of 93.0%, specificity of 64.2%, PPV of 80.9%, and NPV of 86.0%. Overall accuracy of PET/CT was 82.3%. When cases were stratified to include squamous cell carcinoma (SqCC) alone, PET/CT sensitivity was 93.9% and specificity was 62.8%. Of 131 PET/CT cases deemed positive, 25 were false positives; of 50 PET/CT cases deemed negative, 7 were false negatives (Figure 1). Details of false po-

sitives and false negatives are in Table 2. For the 160 cases with measurable ^{18}F-FDG uptake, mean SUV was significantly different between tumor-positive (7.3±4.1; range, 1.5-24.7) and tumor-negative groups (3.8±1.9; range, 1.4-9.0) (P<0.001). Of 21 cases without measurable uptake that could be differentiated from background activity, 4 were later confirmed to be positive for recurrent or residual disease and 17 were true negatives.

Table 1. *General characteristics of 153 patients*

Variables		No. (%)
Sex	Male	121 (79%)
	Female	32 (21%)
Mean age (range)		59 years (26-86)
Primary tumor site	Nasopharynx	20 (13%)
	Oropharynx	21 (14%)
	Hypopharynx	13 (8%)
	Larynx	33 (22%)
	Nasal cavity	9 (6%)
	Oral cavity	31 (20%)
	Maxillary sinus	12 (8%)
	Salivary gland	13 (8%)
	Metastasis of unknown origin	1 (1%)
Histology	Squamous cell carcinoma	107 (70%)
	Adenoid cystic carcinoma	12 (8%)
	Nasopharyngeal carcinoma	20 (13%)
	Mucoepidermoid cystic carcinoma	5 (3%)
	Others	9 (6%)
Prior treatment	RT only	4 (3%)
	Surgery and RT	63 (41%)
	Chemoradiation	30 (20%)
	Surgery and chemoradiation	56 (37%)
RT modality	2D-RT or 3D-CRT	111 (73%)
	IMRT	37 (24%)
	Not available	5 (3%)
Mean RT dose (range)*		62.14 Gy (24-88)

*RT:radiotherapy,2D-RT:two-dimensionalRT,3D-CRT:three-dimensionalconformalRT,IMRT:intensitymodulatedRT, *Not availablein7patients.*

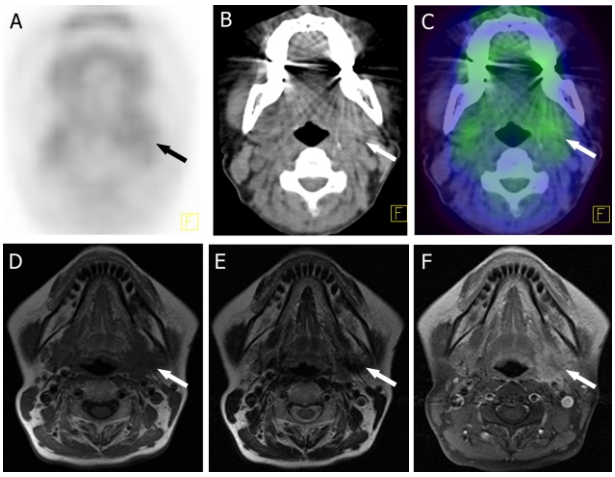

Figure 1. False-negative PET/CT case. A 53 years old woman with mucoepidermoid carcinoma was treated with left submandibular gland excision and RT 7 years earlier. PET (A), CT (B) and fused PET/CT images (C) showed mild and diffuse ^{18F}-FDG uptake in the left submandibular area (arrows) with no abnormal ^{18}F-FDG uptake distinguished from underlying background activity. By MRI, an irregular speculated and nodular soft tissue lesion (arrows) was noted in the left submandibular portion with isointense signal intensity on T1-weighted image (D) and low signal intensity on T2-weighted image (E). Contrast-enhanced T1-weighted image (F) showed enhancement in the lesion (arrow), suggestive of recurrent tumor. Operation confirmed the diagnosis of recurrent mucoepidermoid carcinoma.

Of 181 PET/CT images, 27 (15%) were obtained within 12 weeks after completion of RT and 154 (85%) were obtained more than 12 weeks after RT completion. PET/CT had 100% sensitivity and 55.6% specificity for detecting recurrent or residual disease within 12 weeks after RT and 92.6% sensitivity and 64.4% specificity more than 12 weeks after RT. The range of the time interval from completion of RT to PET/CT imaging for the 25 false positives was 1 to 795 weeks. For the 7 false negatives, the interval range was 24 to 772 weeks. PET/CT cases examined within 12 weeks of RT showed 4 false positives (15%), whereas those examined more than 12 weeks after RT showed 21 false positives (14%; P=0.8792).

Of the 175 PET/CT cases with detailed RT data, 131 (75%) underwent 2D-RT or 3D-CRT, and 44 (25%) underwent IMRT. The interval between the completion of RT and PET/CT imaging was significantly longer for the PET/CT cases after 2D-RT or 3D-CRT than for those after IMRT (131±184 vs.

Table 2. *False-positive and false-negative cases*

No.	Primary tumor site (Histology)	SUV	Interval from RT (In weeks)	Histologic result
False-positive cases				
1	Nasopharynx (NPHC)	3.5	57	Chronic inflammation
2	Nasopharynx (NPHC)	5.9	795	Marked acute and chronic inflammation
3	Nasopharynx (NPHC)	2.6	11	Fibroid muscular tissue with chronic inflammation
4	Nasopharynx (NPHC)	1.9	32	Reactive hyperplasia
5	Nasopharynx (NPHC)	3.5	272	Chronic inflammation with necrosis
6	Nasopharynx (NPHC)	2.2	36	Chronic inflammation with necrosis
7	Tonsil (SqCC)	3.4	1	Total necrosis (negative for malignancy in immunohistochemistry)
8	Tonsil (SqCC)	2.7	113	Acute and chronic inflammation with fibrosis
9	Soft palate (SqCC)	5.4	167	Epithelial hyperplasia
10	Oropharynx (SqCC)	7.1	97	Chronic inflammation
11	Hypopharynx (SqCC)	2.6	10	Severe dysplasia
12	Larynx (SqCC)	5.8	79	Acute and chronic inflammation
13	Larynx (SqCC)	3.3	134	Mild squamous dysplasia
14	Larynx (SqCC)	2.5	186	Squamous epithelia hyperplasia with chronic inflammation
15	Larynx (SqCC)	5.4	90	Reactive hyperplasia
16	Larynx (SqCC)	8.1	17	Epithelial hyperplasia with chronic inflammation
17	Larynx (SqCC)	4.7	91	Severe squamous dysplasia
18	Tongue (SqCC)	3.1	79	Reactive hyperplasia
19	Oral cavity (SqCC)	3.4	16	Chronic inflammation
20	Maxillary sinus (SqCC)	7.0	37	Reactive hyperplasia
21	Maxillary sinus (CAC)	2.7	113	Acute and chronic inflammation with focal fibrosis.
22	Maxillary sinus (SqCC)	4.2	685	Acute and chronic inflammation with abscess formation
23	Maxillary sinus (Adenocarcinoma)	2.3	6	Chronic inflammation and foreign body reaction
24	Parotid gland (Mucoepidermoid carcinoma)	3.5	89	Reactive hyperplasia
25	Minor salivary gland (CAC)	4.5	34	Chronic inflammation

(continued)

		False-negative cases		
1	Tongue (SqCC)	–*	772	SqCC (size, 0.5x0.3 cm; depth of invasion, 0.1cm)
2	Hypopharynx (SqCC)	–	184	SqCC (size, not available)
3	Larynx (SqCC)	–	24	SqCC (immeasurable microscopic focus) with severe fibrosis
4	Larynx (SqCC)	–	489	SqCC (size, < 0.5 cm) with chronic inflammation in adjacent soft tissue
5	Larynx (SqCC)	2.8	36	SqCC (size, 0.8x0.6 cm)
6	Maxillary sinus (CAC)	1.5	133	CAC (size, 3.5x2.0 cm)
7	Submandibular gland (Mucoepidermoid carcinoma)	1.6	361	Mucoepidermoid carcinoma (size, 2.0x1.5 cm)

*SUV: maximum standardized uptake value, RT: radiotherapy, SqCC: squamous cell carcinoma *Not measurable, NPHC: nasopharynxgealcarcinoma,CAC: cystic adenoid carcinoma*

44±40 weeks, P<0.001). PET/CT had 91.0% sensitivity and 62.3% specificity for detecting recurrent or residual disease after 2D-RT or 3D-CRT, and 100% sensitivity and 71.4% specificity after IMRT. Regarding the 24 false positives, PET/CT cases after 2D-RT or 3D-CRT showed 20 false positives (15%), whereas those after IMRT showed 4 false positives (9%; P=0.3385).

Discussion

The results of our study showed that ^{18}F-FDG PET/CT had good diagnostic performance for the detection of locoregional recurrent or residual disease within the radiation field in patients with HNC previously treated by RT. Previous reports showed varying results for ^{18}F-FDG PET and PET/CT for restaging of HNC. Comoretto et al. (2008) [15] found a trend toward greater accuracy for magnetic resonance imaging (MRI) than for PET/CT for detecting recurrent or residual disease at the primary site in patients with nasopharyngeal carcinoma treated with chemotherapy and RT (92.1% vs. 85.7%). However, PET/CT had higher accuracy than MRI in detecting regional lymph node metastases (96.8% vs. 90.5%) and no significant difference in overall accuracy for tumor restaging (74.6% vs. 73.0%). Ong et al. (2008) [16] demonstrated a very high NPV and specificity for excluding residual disease for ^{18}F-FDG PET/CT, suggesting it might become the most decisive modality for managing patients with HNC who underwent chemoradiotherapy. Several studies reported that ^{18}F-FDG PET/CT is superior to anatomical imaging modalities such as enhanced CT and MRI for detecting recurrent or residual tumors in patients with HNC previously treated with RT [17-19]. In our study, the specificity of PET/CT for detecting locoregional recurrent or residual disease was lower than in most previous studies [16, 19-22]. This discrepancy might be because of our strict inclusion criteria. We included only cases with histological confirmation within 4 weeks after PET/CT imaging. Cases with findings that agreed with physical examinations, fiber-optic laryngoscope, and other imaging modalities such as CT and MRI could not be assessed histologically. Therefore, many that were strongly indicative of malignancy or that were not confirmed histologically because of definite metastasis were not included. Instead, more problematic cases that could not be diagnosed using these clinical methods were included, which might have resulted in a relatively large number of false-positive cases. The effect of inflammation in increasing the false-positive rate for ^{18}F-FDG PET/CT is well-documented [23, 24]. Although Avril et al. (2005) [25] suggested that inflamed tissues have lower intensity and a different configuration of ^{18}F-FDG uptake than malignant tissues, our cases with inflammation had asymmetric focal ^{18}F-FDG uptake that could not easily be differentiated from malignant tissue uptake (Figure 2).

Our study included tumors with non-squamous cell types and salivary gland-origin tumors, which are known to have low ^{18}F-FDG-avidity [11, 26]. However, not all non-squamous cell type tumors consistently exhibit low ^{18}F-FDG uptake, as noted by Bui et al. (2003) [27] and observed in our study (Figure 3). When SqCC cases alone were included, diagnostic sensitivity and specificity of PET/CT were similar to values obtained when all cases were included. These results could be a good representation of actual clinical practice, because PET/CT imaging is not performed selectively in patients with SqCC.

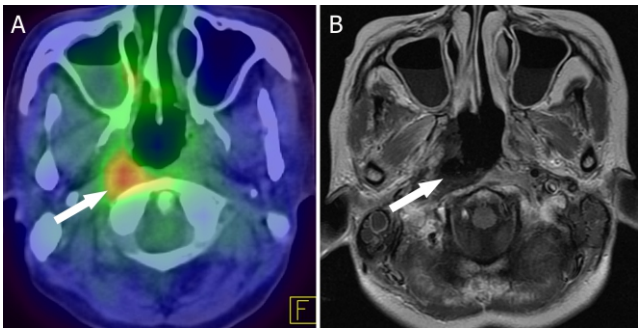

Figure 2. False-positive PET/CT case. A 33 years old woman with nasopharyngeal cancer was treated with 3D-CRT combined with chemotherapy 57 weeks earlier. In fused PET/CT image (A), asymmetrically increased ^{18}F-FDG uptake (SUV 3.5) was noted in the right posterolateral nasopharyngeal wall (arrow) within the previous radiation field. Contrast-enhanced MRI (B) showed non-enhancing necrotic lesion in the corresponding site (arrow). Biopsy was performed for suspicious lesion with a histologic result of chronic inflammation with necrosis.

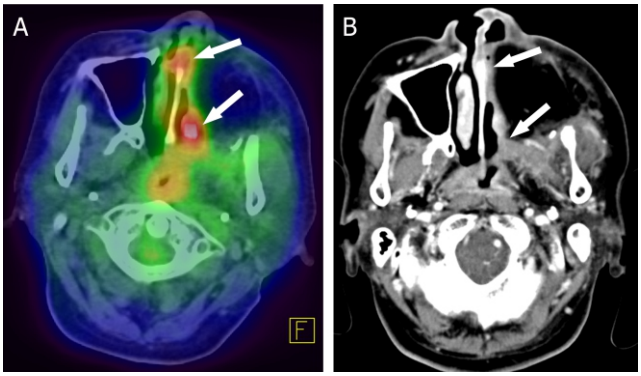

Figure 3. True-positive PET/CT case. A 52 years old woman with nasal cavity cancer (mixed squamous cell carcinoma and mucoepidermoid carcinoma) was treated with concurrent chemoradiation followed by left medial maxillectomy 12 weeks earlier. In fused PET/CT image (A), focal ^{18}F-FDG uptake areas (SUV 4.5) were noted in the medial margin of left maxillectomy site (arrows). Enhanced CT finding (B) was equivocal. Secondary operation was performed with histologic result of recurrent mucoepidermoid carcinoma without squamous cell component.

Reports of the optimal timing for ^{18}F-FDG PET/CT imaging in relation to RT have described conflicting results. Yom et al. (2005) [28] reported that early response evaluation within 4-8 weeks after completion of RT is especially important when making decisions about potential surgery in patients with T3/4 resectable non-laryngeal HNC. Nam et al. (2005) [29] showed that a month after completion of RT is not too early to evaluate treatment response using PET/CT. However, to reduce false-positive rate caused by radiation-induced inflammation, follow-up PET/CT imaging is generally recommended at a minimum of 12 weeks after completion of RT [13, 14]**.** In our study, PET/CT images taken within 12 weeks of RT had a higher false-positive rate than those taken 12 weeks after RT (44.4% vs. 35.6%); these results were consistent with those of previous reports. Kwong et al. (1999) [30] reported that a high proportion of early positive histology had spontaneous remission in patients with nasopharyngeal cancer who had completed RT, and positive histology obtained after only 12 weeks of RT was correlated with true persistent disease. Thus, 12 weeks appears to be an adequate period of time between completion of RT and response assessment. However, occurrence of false positives caused by radiation-induced inflammation is not confined to the early phase. Yen et al. (2005) [31] found that false positives were caused by inflammation within the previous radiation field, despite PET/CT imaging at 6 and 19 months after RT. Our findings showed that inflammation at the treatment site caused to false positives years after RT and these results were consistent with prior findings. The frequency of false positives in PET/CT images within 12 weeks of RT was similar to the results obtained 12 weeks after RT (15% vs. 14%, P=0.8792).

As per our results, false positives were more frequent in PET/CT cases after 2D-RT or 3D-CRT than in those after IMRT, although the difference was not statistically significant (15% vs. 9%, P=0.3385). Ghosh et al. (2016) [32] reported that IMRT for HNC provided a better outcome with reduced toxicity, compared to conventional RT techniques. IMRT has the ability to deliver radiation more precisely to the target volume, while sparing the surrounding normal tissues. Hence, we presumed that inflammation, hyperplasia, and dysplasia were more common in our patients who underwent 2D-RT or 3D-CRT. Possible false-positive findings caused by radiation-induced inflammation should be considered regardless of the interval between the RT and PET/CT imaging, especially in PET/CT cases after 2D-RT or 3D-CRT. Therefore, the histological diagnosis should be confirmed in positive PET/CT cases before taking treatment decisions.

The main limitations of this study originated from its retrospective design. First, patients who underwent different combinations of treatment modalities and heterogeneous RT doses were included, and PET/CT findings may not exclusively reflect the effects of RT. Second, detailed RT data, especially for earlier medical records or patients transferred from other hospitals, were not available in some patients. Third, the number of PET/CT images obtained within 12 weeks after completion of RT was small (27 cases of 181), so the performance of short-term follow-up PET/CT images may be misleading in our study. Fourth, our study might have had selection bias because most cases referred for PET/CT imaging had a high suspicion for malignancy and histological confirmation was more likely for tumors with a high degree of suspicion on PET/CT images. However, although limited by retrospective data, an important point of this study was that all included cases had histological confirmation.

In conclusion, ^{18}F-FDG PET/CT has a good complementary role for detection of locoregional remnant or recurrent disease within the radiation field in patients with HNC previously treated with RT. Both short-term and long-term radiation-induced inflammation were the main causes of false positives. False positives were more common in PET/CT cases after 2D-RT or 3D-CRT than in those after IMRT. Therefore, histological verification of positive PET/CT findings could be conducted during follow-up of patients with HNC treated with RT.

Bibliography

1. Massoud TF, Spencer RP. Radiopharmaceuticals for cancer imaging

mechanisms of localization, and molecular targets. In: Ell PJ, Gambhir SS. Eds. Nuclear medicine in clinical diagnosis and treatment. 3rd edn. Edinburgh: *Churchill Livingstone* 2004; 3-14.
2. Scott AM, Gunawardana DH, Bartholomeusz D et al. PET Changes Management and Improves Prognostic Stratification in Patients with Head and Neck Cancer: Results of a Multicenter Prospective Study. *J Nucl Med* 2008; 49(10): 1593-600.
3. Manca G, Vanzi E, Rubello D et al. ^{18}F-FDG PET/CT quantification in head and neck squamous cell cancer: principles, technical issues and clinical applications. *Eur J Nucl Med Mol Imaging* 2016; 43(7): 1360-75.
4. Differding S, Hanin F-X, Grégoire V. PET imaging biomarkers in head and neck cancer. *Eur J Nucl Med Mol Im* 2015; 42(4): 613-22.
5. Heusner TA, Hahn S, Hamami ME et al. Incidental head and neck ^{18}F-FDG uptake on PET/CT without corresponding morphological lesion: early predictor of cancer development? *Eur J Nucl Med Mol Imaging* 2009; 36(9): 1397-406.
6. Blodgett TM, Fukui MB, Snyderman CH et al. Combined PET-CT in the head and neck: part 1. Physiologic, altered physiologic, and artifactual FDG uptake. *Radiographics* 2005; 25(4): 897-912.
7. Fukui MB, Blodgett TM, Snyderman CH et al. Combined PET-CT in the head and neck: part 2. Diagnostic uses and pitfalls of oncologic imaging. *Radiographics* 2005; 25(4): 913-30.
8. Nabili V, Zaia B, Blackwell KE et al. Positron emission tomography: poor sensitivity for occult tonsillar cancer. *Am J Ootolar* 2007; 28(3): 153-7.
9. Lee HS, Kim JS, Roh JL et al. Clinical values for abnormal ^{18}F-FDG up-take in the head and neck region of patients with head and neck squamous cell carcinoma. *Eur J Radiol* 2014; 83(8): 1455-60.
10. Davison JM, Ozonoff A, Imsande HM et al. Squamous cell carcinoma of the palatine tonsils: FDG standardized uptake value ratio as a biomarker to differentiate tonsillar carcinoma from physiologic uptake. *Radiology* 2010; 255(2): 578-85.
11. Haddad RI, Shin DM. Recent advances in head and neck cancer. *N Engl J Med* 2008; 359(11): 1143-54.
12. Milliat F, Francois A, Isoir M et al. Influence of endothelial cells on vascular smooth muscle cells phenotype after irradiation: implication in radiation-induced vascular damages. *Am J Pathol* 2006; 169(4): 1484-95.
13. Porceddu S, Jarmolowski E, Hicks R et al. Utility of positron emission tomography for the detection of disease in residual neck nodes after (chemo)RT in head and neck cancer. *Head & Neck* 2005; 27(3): 175-81.
14. National Comprehensive Cancer Network (NCCN) guidelines. Head and neck cancers. Available from: http://www.nccn.org/professionals/physician_gls/pdf/head-and-neck.pdf. Access date: 01.01. 2016.
15. Comoretto M, Balestreri L, Borsatti E et al. Detection and restaging of residual and/or recurrent nasopharyngeal carcinoma after chemotherapy and radiation therapy: comparison of MR imaging and FDG PET/CT. *Radiology* 2008; 249(1): 203-11.
16. Ong SC, Schoder H, Lee NY et al. Clinical utility of ^{18}F-FDG PET/CT in assessing the neck after concurrent chemoRT for Locoregional advanced head and neck cancer. *J Nucl Med* 2008; 49(4): 532-40.
17. Zimmer LA, Branstetter BF, Nayak JV et al. Current use of ^{18}F-fluorodeoxyglucose positron emission tomography and combined positron emission tomography and computed tomography in squamous cell carcinoma of the head and neck. *The Laryngoscope* 2005; 115(11): 20-29-34.
18. Ng SH, Joseph CT, Chan SC et al. Clinical usefulness of ^{18}F-FDG PET in nasopharyngeal carcinoma patients with questionable MRI findings for recurrence. *J Nucl Med* 2004; 45(10): 1669-76.
19. Kim S, Kim J, Yi J et al. Evaluation of ^{18}F-FDG PET/CT and CT/MRI with histopathologic correlation in patients undergoing salvage surgery for head and neck squamous cell carcinoma. *Annals of Surgical Oncology* 2011; 18(9): 2579-84.
20. Kim SY, Lee SW, Nam SY et al. The Feasibility of ^{18}F-FDG PET scans 1 month after completing RT of squamous cell carcinoma of the head and neck. *J Nucl Med* 2007; 48(3): 373-8.
21. Abgral R, Querellou Sn, Potard Gl et al. Does ^{18}F-FDG PET/CT improve the detection of posttreatment recurrence of head and neck squamous cell carcinoma in patients negative for disease on clinical follow-up? *J Nucl Med* 2009; 50(1): 24-9.
22. Sagardoy T, Fernandez P, Ghafouri A et al. Accuracy of ^{18}F-FDG PET-CT for treatment evaluation 3 months after completion of chemoRT for head and neck squamous cell carcinoma: 2-year minimum follow-up. *Head Neck* 2016; 38 Suppl 1:E1271-6.
23. Schoder H, Fury M, Lee N, Kraus D. PET monitoring of therapy response in head and neck squamous cell carcinoma. *J Nucl Med* 2009; 50 Suppl 1: 74S-88S.
24. Wong RJ, Lin DT, Schoder H et al. Diagnostic and prognostic value of [^{18}F]fluorodeoxyglucose positron emission tomography for recurrent head and neck squamous cell carcinoma. *J Clin Oncol* 2002; 20(20): 41-99-208.
25. Avril NE, Weber WA. Monitoring response to treatment in patients utilizing PET. *Radiologic clinics of North America* 2005; 43(1): 189-204.
26. Uchida Y, Minoshima S, Kawata T et al. Diagnostic value of FDG PET and salivary gland scintigraphy for parotid tumors. *Clin Nucl Med* 2005; 30 (3): 170-6.
27. Bui CD, Ching AS, Carlos RC et al. Diagnostic accuracy of 2-[fluorine-18]fluro-2-deoxy-D-glucose positron emission tomography imaging in nonsquamous tumors of the head and neck. *Investigative Radiology* 2003; 38(9): 593-601.
28. Yom SS, Machtay M, Biel MA et al. Survival impact of planned restaging and early surgical salvage following definitive chemoradiation for locally advanced squamous cell carcinomas of the oropharynx and hypopharynx. *Am J Clin Oncol* 2005; 28(4): 385-92.
29. Nam SY, Lee SW, Im KC et al. Early evaluation of the response to RT of patients with squamous cell carcinoma of the head and neck using ^{18}FDG-PET. *Oral Oncol* 2005; 41(4): 390-5.
30. Kwong DL, Nicholls J, Wei WI et al. The time course of histologic remission after treatment of patients with nasopharyngeal carcinoma. *Cancer* 1999; 85(7): 1446-53.
31. Yen RF, Hong RL, Tzen KY et al. Whole-body ^{18}F-FDG PET in recurrent or metastatic nasopharyngeal carcinoma. *J Nucl Med* 2005; 46(5): 770-4.
32. Ghosh G, Tallari R, Malviya A. Toxicity profile of IMRT vs. 3D-CRT in head and neck cancer: a retrospective study. *J Clin Diagn Res* 2016; 10(9): XC01-XC03.