

¹⁸F-FDG PET/CT in a rare case of diffuse large B cell lymphoma presenting as deep vein thrombosis with bilateral breast involvement and subcutaneous nodules

To the Editor: Lymphoma is a disease with varied clinical presentations and organ involvements. Accurate staging remains essential to differentiate nodal and extra nodal lymphomas and to prognosticate the patients accurately. We report a female patient diffuse large B cell lymphoma presenting as deep vein thrombosis (DVT). On routine examinations, she was found to have bilateral breast masses. Fluorine-18 fluorodeoxyglucose, positron emission tomography/computerized tomography (¹⁸F-FDG PET/CT) scan helped in identifying the various sites of involvement and assess the response to treatment. The patient was 68 years old and presented with left lower limb swelling, erythema and pain. D-dimer values estimated on suspicion of DVT were elevated. Doppler ultrasound (USG) confirmed the presence of DVT. Routine mammograms revealed masses in bilateral breasts. Fine needle aspiration (FNAC) showed the masses harbouring diffuse large B-cell lymphoma (DLBCL). Subsequently the patient was subjected to ¹⁸F-FDG PET/CT for staging. This pre-treatment scan (Fig. 1A) revealed intense ¹⁸F-FDG uptake in multiple cervical, supra clavicular, celiac pericecal, mesenteric and left inguinal lymph nodes. Pancreas, both breasts and spleen also showed ¹⁸F-FDG avidity. In addition to those lesions, PET/CT also detected multiple soft tissue deposits with intense ¹⁸F-FDG uptake in the left thigh. There was no abnormal marrow uptake of ¹⁸F-FDG and the same was confirmed on bone marrow examination which was negative for marrow infiltration. The cross sectional images (Fig. 2A and Fig. 2B) of ¹⁸F-FDG PET/CT showed intense ¹⁸F-FDG uptake in bilateral breasts and subcutaneous nodules in the left thigh respec-

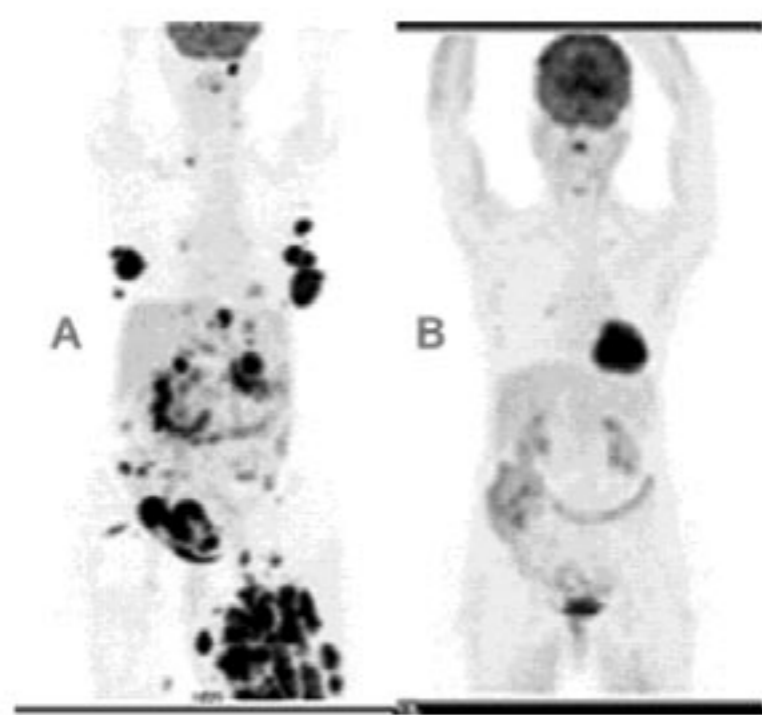


Figure 1. Pre treatment MIP image (A) showing intense ¹⁸F-FDG uptake in bilateral breasts and a left cervical lymph node and right supraclavicular node along with multiple celiac, pericecal, mesenteric and left inguinal lymph nodes. Pancreas, spleen and left thigh subcutaneous nodules also show intense ¹⁸F-FDG uptake. Post treatment MIP image of the same patient (B) after 4 cycles of R-CHOP chemotherapy show complete metabolic response except for mild uptake in a right hilar lymph node, probably due to infection.

ctively. The patient was staged as stage IV without marrow involvement. She was started on warfarin for DVT and R-CHOP (rituximab, cyclophosphamide, hydroxydoxorubicin, oncovin, prednisolone) chemotherapy for DLBCL and was reassessed with PET/CT after 4

cycles of chemotherapy. No abnormal ¹⁸F-FDG uptake was noticed elsewhere in the body but for a right hilar lymph node which would most likely present an infectious process as the patient had a bout of lower respiratory tract infection during the course of treatment (Fig. 1B). Uptake in bilateral breasts (Fig. 2C) was reduced to background indicating a very good response to chemotherapy. Complete disappearance of the uptake in the subcutaneous deposits (Fig. 2D) following R-CHOP treatment confirmed the lymphomatous nature of the deposits.

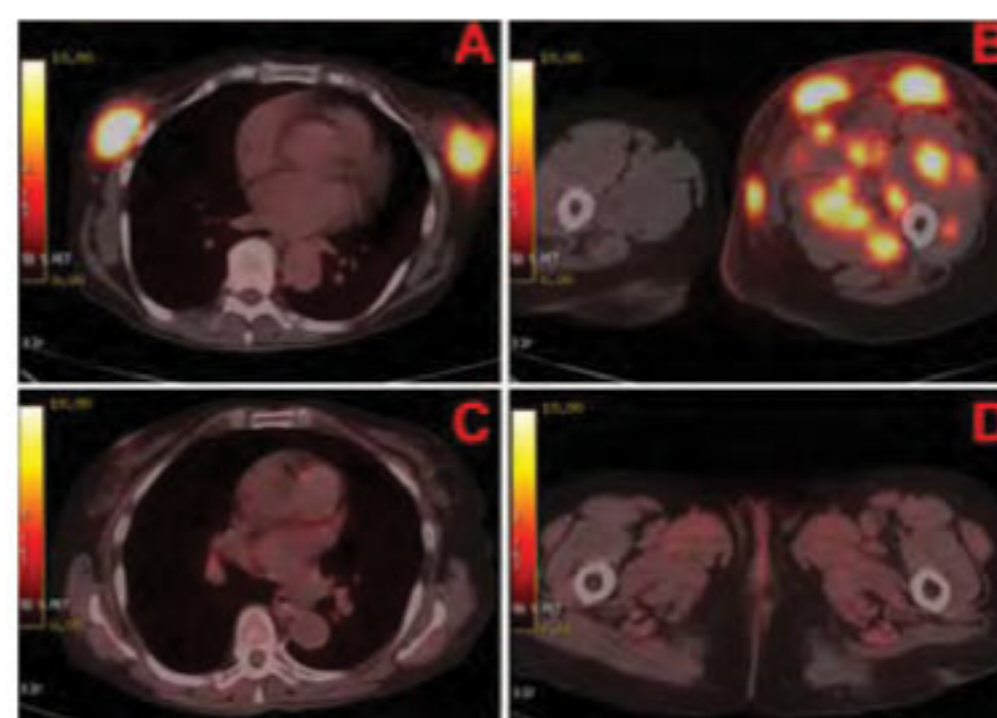


Figure 2. Pre treatment cross sectional images of ¹⁸F-FDG-PET/CT showing intense ¹⁸F-FDG uptake in bilateral breasts (A) and subcutaneous nodules in left thigh (B). Post treatment cross sectional images of ¹⁸F-FDG PET/CT of the same patient after 4 cycles of R-CHOP chemotherapy show complete disappearance of abnormal ¹⁸F-FDG uptake in bilateral breasts (C) and subcutaneous soft tissue nodules in the left thigh (D) indicating complete metabolic response to chemotherapy.

Extra nodal lymphoma defined as lymphomatous involvement of non-nodal tissue, has been described virtually in every organ and tissue. Extra nodal involvement occurs in up to 5% of patients with Hodgkin's lymphoma, and up to 33% in non-Hodgkin's lymphoma at some stage of the disease [1]. Secondary involvement of extra nodal sites by lymphoma as part of disseminated disease is generally more common than primary involvement of an organ or tissue, in which there is no or there is minor regional nodal disease. Diffuse large B-cell lymphoma and follicular lymphoma are the dominant histological subtypes in extra nodal lymphomas [2]. Lymphoma of breast is a rare entity and accounts for 0.15% of all malignant breast tumours [3]. Secondary involvement of breasts is more common than primary involvement [4]. Primary lymphomas of the breast are shown to have poor prognosis when compared to secondary involvement [5]. Criteria for differentiation of primary or secondary breast involvement depend on the assessment of other sites of the body [6]. Usually primary breast lymphoma is diagnosed when the breast is the predominant site of the disease compared to other sites. So, staging appears to be very crucial in prognosticating this group of patients. In staging extra nodal lymphomas ¹⁸F-FDG PET has been shown to be very superior to CT and other conventional imaging modalities [7]. In our

case, breast involvement was secondary as the patient had extensive abdominal lymphadenopathy and cervical lymph nodal involvement detected by ^{18}F -FDG PET/CT. Interestingly, the patient also showed multiple subcutaneous deposits with intense ^{18}F -FDG uptake presumed to be lymphomatous deposits at an initial stage. Later, these masses disappeared following chemotherapy treatment confirming the lymphomatous nature of the deposits. Subcutaneous lymphomatous involvement has been demonstrated in T cell lymphomas by ^{18}F -FDG PET [8] but to the best of our knowledge, not in DLBCL. Almost complete metabolic response was noted in all the involved sites after 4 cycles of chemotherapy signifying good prognosis. *In conclusion*, our case reports that ^{18}F -FDG PET/CT scan identified rare sites of lymphomatous involvement, supported staging and showed response to chemotherapy.

Bibliography

1. Halliday T, Baxter G. Lymphoma: pictorial review1. *Eur Radiol* 2003; 13: 1154-64.
2. Vinnicombe SJ, Reznick RH. Extranodal manifestations of lymphoma. *Imaging* 1999; 11: 240-6
3. Bae YA, Lee KS. Cross-sectional evaluation of thoracic lymphoma. *Radiol Clin North Am* 2008; 46: 253-64.
4. Yang WT, Muttarak M, Ho LW. Non mammary malignancies of the breast: ultrasound, CT, and MRI. *Semin Ultrasound CT MR* 2000; 21: 375-94.
5. Carbone A. Primary diffuse large B-cell lymphoma of the breast: an aggressive subgroup with nongerminial center B-cell-like phenotype. *Am J Hematol* 2009; 84: 129-30.
6. Zucca E, Cavalli F. Challenging issues in the management of extranodal lymphomas. In: Cavalli F, Stein H, Zucca E, editors. *Extranodal Lymphomas. Pathology and Management*. London: Informa Healthcare; 2008: pp 3-9.
7. Moog F, Bangerter M, Diederichs CG et al. Extranodal malignant lymphoma: detection with FDG PET versus CT. *Radiology* 1998; 206: 475-81.
8. Berk V, Yildiz R, Akdemir UO et al. Disseminated extra nodal NK/T-cell lymphoma, nasal type, with multiple subcutaneous nodules: utility of ^{18}F -FDG PET in staging. *Clin Nucl Med* 2008; 33: 365-6.

Kuruva Manohar MBBS¹, Bhagwant Rai Mittal MD, DNB¹, Sampath Santhosh MBBS¹, Anish Bhattacharya DRM, DNB¹, Pankaj Malhotra MD², Subhash Varma MD²

1. Department of Nuclear Medicine and 2. Internal Medicine, Postgraduate Institute of Medical Education and Research, Chandigarh 160 012, India

Dr. B.R. Mittal, Professor and Head,

Department of Nuclear Medicine, PGIMER, Chandigarh, 160012, India
Tel: (91)-172-2756722, Fax: (91)-172-2742858, E-mail: brmittal@yahoo.com

Hell J Nucl Med 2010; 13(3): 298-299
Published on line: 25-11-10