

Follow-up ^{18}F -FDG-PET for the detection of inguinal metastatic penile squamous cell carcinoma: An ultrasound guided fine-needle aspiration

To the Editor: We read with great interest the Letter to the editor "An original case of isolated unilateral adrenal metastasis from penile carcinoma: documentation by fluorine-18 fluorodesoxyglucose-positron emission tomography (^{18}F -FDG-PET) imaging and histopathology" [1], which was also a response to the published report in *Hell J Nucl Med*. Others have primarily emphasized on the utilization of ^{18}F -FDG-PET in the diagnosis of metastatic adrenal from squamous cell carcinoma of the penis [2]. Our presentation emphasizes a follow-up ^{18}F -FDG-PET examination in the most common metastatic site-inguinal regions, with correlation with ultrasound guided fine-needle aspiration cytology. An 80 years old man had a tissue diagnosis of penile invasive squamous carcinoma more than 3 years and 5 months ago, and had partial penectomy and negative for subsequent bilateral superficial inguinal lymph node dissection. The patient stated he had had a longstanding penile wart in that area which was removed approximately 50 years ago. A follow up in the clinic found a hard and fixed left inguinal nodule. An ultrasound guided fine needle aspiration cytology was performed which was positive for metastatic squamous cell carcinoma arising from the glans penis. Three weeks later a ^{18}F -FDG-PET-computed tomography (CT) showed a 3.5x2.3cm mass with 7.7 of SUV in the left inguinal region (Fig. 1A). The patient was considered to have a neoadjuvant treatment.

Squamous cell carcinoma of the penis is a rare malignancy accounting for less than 1% of all male malignancy [3, 4]. The superficial inguinal nodes are the first echelon of drainage of the lymphatic from the penile skin, foreskin, and the subcutaneous tissues that freely anastomoses along the dorsum of the penis and at its base [5]. It is not surprising that most reported cases metastasize to inguinal or groin region [2, 6, 7] as in our case. Follow-up ^{18}F -FDG-PET examination in our case, showed a distinguished large mass 3.5x2.5cm in size involving a superficial lymph node with high uptake with SUV of 7.7 which stood-out when fused with CT scans as shown on the Figures.

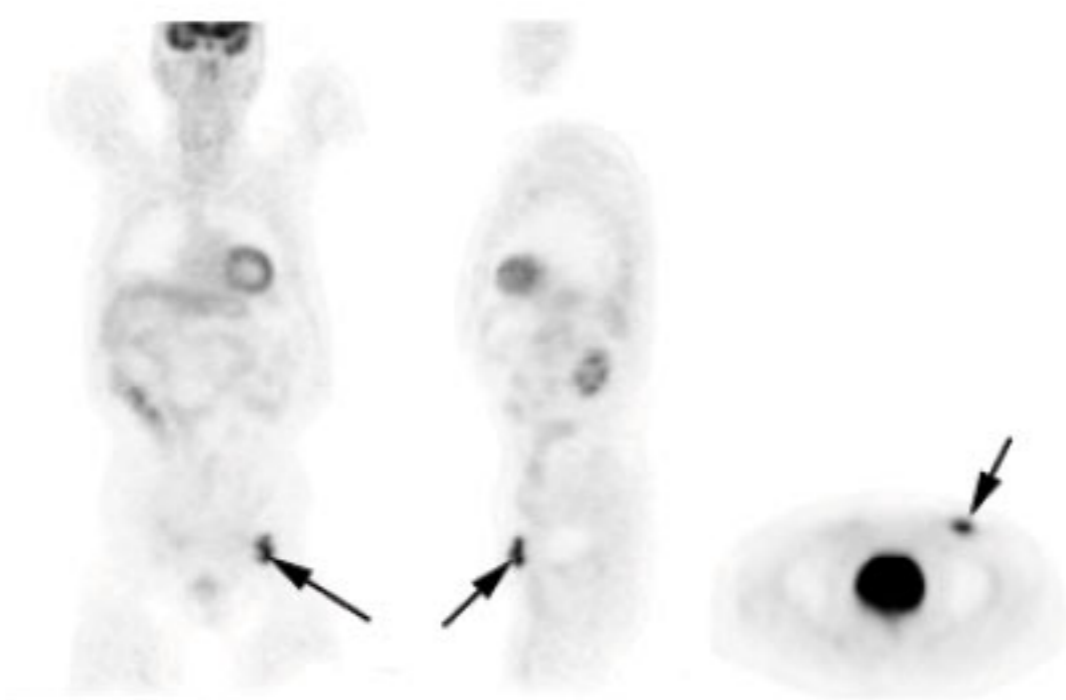


Figure 1A. Coronal (left), sagittal (middle), and axial (right) sections of ^{18}F -FDG-PET images show a focally increased uptake (arrows) with maximal SUV of 7.7 in the left inguinal region.

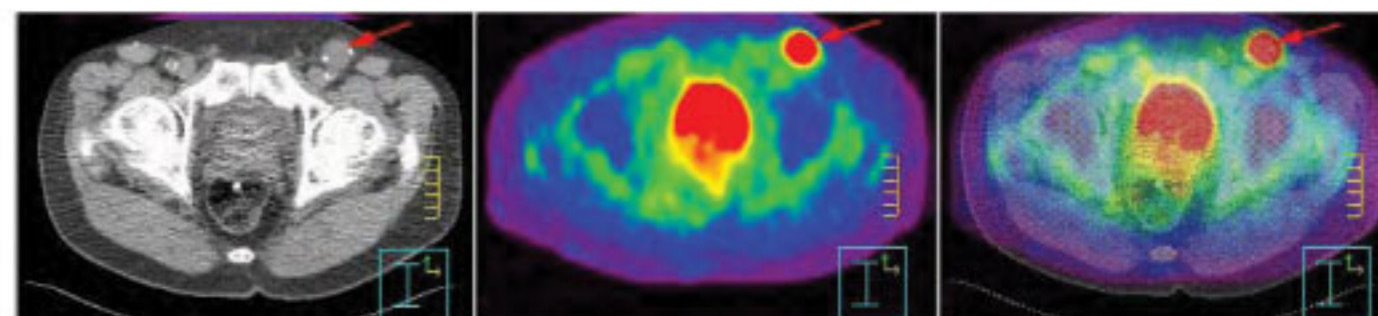


Figure 1B. PET (middle) and PET-CT (right) axial section through the inguinal region show a focally bright-red uptake (red arrows) corresponding to the lymph node shown on axial CT (left).

Image-guided (CT guided or ultrasound guided) percutaneous biopsy for suspected malignancies is common procedure at most medical centers [8]. Fine-needle aspiration biopsy from the inguinal lymph node is currently used in metastatic prostate carcinoma [9], bladder carcinoma [10], and malignancy of testis [11]; and in penile squamous cell carcinoma is also successfully used to diagnose metastases [5, 12]. Approximately 40% of patients develop nodal metastases during their disease [13]. Generally, distant metastasis is uncommon in patients and occurs late in the course of the disease, and is associated with poor prognosis. Lung, liver, bone, brain and skin are common locations for metastatic disease from penile cancer; there is rarely seen an adrenal metastasis [1]. Only 5% of patients with penile cancer have distant metastases at the time of diagnosis [13].

Imaging plays an increasingly important role in the determination of lymph nodal metastases [3]. Although CT plays an important role for the detection of lymphadenopathy, it suffers from the inability to detect metastases in normal-sized lymph nodes. In addition, CT is nonspecific because enlargement of the lymph nodes may be caused by infection. Our patient's metastatic mass is detectable on PET fused to CT images, combined functional and anatomic image-modalities [7]. Risk factors include increasing age, smoking, and absence of circumcision, phimosis, poor hygiene, human papilloma virus, and the known premalignant penile lesions [14]. Our patient's squamous cell carcinoma of the penis might have been related to a long standing existing penile wart in the past. Penile carcinoma is a chemoresponsive disease many agents have been effective either alone or in combination [15]. *In conclusion*, we present a case of a follow-up ^{18}F -FDG-PET to show a prominent inguinal lymph node metastasis from penile squamous cell carcinoma.

Acknowledgement

The authors thank to Mark Ingram, reference librarian, for his excellent and diligent search of the literature during the preparation of this paper.

Bibliography

1. Joshi P, Kulkarni MJ, Basu S et al. An original case of isolated unilateral adrenal metastasis from penile carcinoma: documentation by ^{18}F -FDG-PET imaging and histopathology. *Hell J Nucl Med* 2010; 13: 63-4.

2. Halac M, Zincirkeser S, Sonmezoglu K et al. Fluoro-18 fluorodeoxyglucose positron emission tomography/computerized tomography scans in a patient with penile cancer for appropriate therapeutic strategy. *Hell J Nucl Med* 2007; 10: 113-5.
3. Singh AK, Gonzalez-Torrez P, Kaewlai R et al. Imaging of penile neoplasm. *Semin Ultrasound CT MRI* 2007; 28: 287-96.
4. Misra S, Chaturvedi A, Misra NC. Penile carcinoma: a challenge for the developing world. *Lancet Oncol* 2004; 5: 240-7.
5. Scappini P, Riscioli F, Pusioi T et al. Penile Cancer Aspiration Biopsy Cytology for Staging. *Cancer* 1986; 58: 1526-33.
6. Ravizzini GC, Wagner M, Boerges-Neto S. Positron Emission Tomography Detection of Metastatic Penile Squamous Cell carcinoma. *J of Urology* 2001; 165: L 1633-4.
7. Scher B, Seitz M, Reiser M et al. ¹⁸F-FDG PET /CT for Staging of Penile Cancer. *J Nucl Med* 2005; 46: 1460-5.
8. Quinn SF, Sheley RC, Nelson HA et al. The Role of Percutaneous Needle Biopsies in the Original Diagnoses of Lymphoma: A Prospective Evaluation. *JVIR* 1995; 6: 947-52.
9. Rosa M, Chopra HK, Sahoo S. Fine needle aspiration biopsy diagnosis of metastatic prostate carcinoma to inguinal lymph node. *Diagn Cytology* 2007; 35: 565-7.
10. Hamano A, Udagawa K, Nomura S, Ishida T. Inguinal metastasis of a bladder mixed carcinoma with predominant adenocarcinoma component. *Scandinavian J of Urology & Nephrology* 2006; 40: 75-7.
11. Grant JJ, Nagarajan S, Barrett PD et al. Malignant teratoma of the testis presenting with lateral inguinal lymphadenopathy and diagnosis. *Cystopathology* 1997; 8: 122-6.
12. Senthil Kumar MP, Ananthakrishnan N, Prema V. Predicting regional lymph node metastasis in carcinoma of the penis: a comparison between fine-needle aspiration cytology, sentinel

lymph node biopsy and medical inguinal lymph node biopsy. *British J of Urology* 1998; 81: 453-7.

13. Pizzocaro G, Piva L, Bandieramontie G et al. Up-to-date management of carcinoma of the penis. *Eur Urol* 1997; 32: 5-15.
14. Power DG, Galvin DJ, Cuff S et al. Cisplatin and gemcitabine in the management of metastatic penile cancer. *Urol Oncol: Semin and Origin Investigation* 2009; 27: 187-90.
15. Joerger M, Warzinek T, Klaeser B et al. Major tumor regression after paclitaxel and carboplatin polychemotherapy in a patient with advanced penile cancer. *J Urol* 2004; 63: 778-81.

Wei-Jen Shih MD¹, George L. Shih MD, MS², Primo P. Milan MD³

1. Nuclear Medicine Service, Lexington VA Medical Center, and Department of Radiology, University Kentucky Medical Center, Lexington KY 40536, USA

2. Department of Radiology, Weil Medical College, Cornell University, New York, NY, USA and

3. Radiology Service, Lexington VA Medical Center, Lexington, KY 40502, USA

Wei-Jen Shih MD,

Nuclear Medicine Service, Lexington VA Medical Center,
1100 Veterans Drive, Lexington, Kentucky, 40502 USA
Tel: 859-381-5928, Fax: 859-323-2171
Email: wshih0@uky.edu

Hell J Nucl Med 2010; 13(3): 283-284
Published on line: 25-11-10