

# The effect of antiallergic treatment with desloratadine-montelukast on salivary glands function in allergic rhinitis

Arif Ayan<sup>1</sup> MD,  
Ozgur Yoruk<sup>2</sup> MD,  
Bedri Seven<sup>1</sup> MD,  
Ebru Orsal<sup>1</sup> MD,  
Vahit Mutlu<sup>2</sup> MD,  
Berrin Aydin<sup>2</sup> MD

1. Department of Nuclear  
Medicine, Ataturk University,  
Medical School, 25240  
Erzurum-Turkey

2. Department  
of Otorhinolaryngology,  
Ataturk University,  
Medical School, 25240  
Erzurum-Turkey

**Keywords:** Allergic rhinitis  
- Salivary glands function  
- Desloratadine-montelukast  
- Salivary glands scintigraphy

## Correspondence address:

Arif Kursad Ayan,  
Ataturk University Faculty  
of Medicine, Department  
of Nuclear Medicine,  
E-mail: ayankursad@gmail.com  
Tel: + 90 442 3446654  
Fax: + 90 442 2360968

Received:

7 July 2014

Accepted revised:

11 September 2014

## Abstract

The aim of this study was to evaluate the possible favorable effect of desloratadine-montelukast combination on salivary glands (SG) function in patients with allergic rhinitis (AR) using SG scintigraphy. The study population consisted of 64 patients with AR and 28 healthy controls: 14 males and 14 females, with mean age  $32.3 \pm 8.6$  years. The patients were divided into two groups: the untreated patients group of 32 patients, 16 males and 16 females, mean age  $28.5 \pm 5.4$  years and the treated group, who received the standard clinically recommended oral dose of montelukast 10mg/d and desloratadine 5mg/d for 6 weeks. This group consisted of 32 patients, 16 males and 16 females, mean age  $38.3 \pm 8.4$  years. All patients and healthy controls underwent SG scintigraphy. After the intravenous injection of technetium-99m pertechnetate, ( $^{99m}\text{Tc-P}$ ), dynamic SG scintigraphy was performed for 25min. Using the time-activity curves, the following glandular function parameters were calculated for the parotid and the submandibular SG: uptake ratio, maximum accumulation and ejection fraction. Results showed SG hypofunction. All functional parameters obtained for the untreated patients and for the desloratadine-montelukast treated patients were significantly lower than those in healthy controls ( $P < 0.05$ ). There was no statistically significant difference between treated and untreated patients ( $P > 0.05$ ). In conclusion, our study showed that hypofunction of SG was present in all patients with AR. This hypofunction, as tested by semi-quantitative SG scintigraphy, and also the quality of life did not improve after treatment with montelukast and desloratadine.

Hell J Nucl Med 2014; 17(3): 190-193

Epub ahead of print: 12 November 2014

Published online: 22 December 2014

## Introduction

Allergic rhinitis (AR) is an extremely common health problem affecting 10% to 25% of the population [1, 2]. It is a chronic inflammatory disease that impairs quality of life due to both nasal symptoms, like rhinorrhea, itching, and sneezing and eye signs, like redness and itching [3, 4]. Salivary flow rates are often found to be significantly decreased [5, 6].

The second-generation antihistamine drug, desloratadine has been recommended as first line treatment for AR and its decongestant effect has been shown in previous reports [7, 8]. Montelukast, a leukotriene receptor antagonist has significantly improved day-time and night-time symptoms in patients with AR [9]. Recent studies in rats have shown that montelukast had potential protective effect on salivary glands (SG) function against I-131 induced damage [10]. Combination of both drugs has shown a synergistic effect in treating AR and improving patients' quality of life [4].

Salivary glands scintigraphy with technetium-99m pertechnetate ( $^{99m}\text{Tc-P}$ ) has been used for the functional assessment of the major SG both qualitatively and semi-quantitatively in multiple diseases or for appraising side effects of certain medications affecting SG [11-13].

A similar study showed that the same combined treatment has improved in perennial AR both the quality of life and nasal obstruction [4], but did not study SG function. The purpose of this prospective study was to evaluate the possible favorable effect of combined desloratadine and montelukast treatment on SG function in AR patients using  $^{99m}\text{Tc-P}$  SG scintigraphy.

## Subjects and methods

### Patients

The study population consisted of 64 patients with AR and 28 healthy controls. Healthy controls were 14 males and 14 females ranging in age from 22 to 47 years old, mean

age  $32.3 \pm 8.6$  years old. The patients were divided into two groups: an untreated patient group of 32 patients, 16 males and 16 females ranging in age from 23 to 46 years old, mean age  $28.5 \pm 5.4$  years old and a patients' group treated with desloratadine-montelukast, which consisted of 32 patients, 16 males and 16 females ranging in age from 22 to 53 years old, mean age  $38.3 \pm 8.4$  years old (Table 1). All patients in the treated group received the standard usually recommended oral dose of montelukast and desloratadine (DESMONT<sup>®</sup>, Nuvomed, Istanbul, Turkey) once daily for 6 weeks. Each tablet contains desloratadine 5mg and montelukast sodium 10mg. The Ethics Committee of our university approved this study.

All patients had perennial nasal symptoms such as rhinorrhea, itching, sneezing fits, and nasal congestion and a positive skin test to common inhalant allergens such as mite, pollen and mold. None of the patients or healthy controls had a connective tissue or other systemic disease, interfering with SG function or a history of head or neck surgery or of radiation treatment.

**Table 1.** Characteristics of healthy controls and of the two groups of patients

Groups	N	Gender (male/female)	Mean age $\pm$ SD (years)
Healthy controls	28	14/14	32.3 $\pm$ 8.6
Untreated patients	32	16/16	28.5 $\pm$ 5.4
Treated patients	32	16/16	38.3 $\pm$ 8.4

### Salivary glands scintigraphy

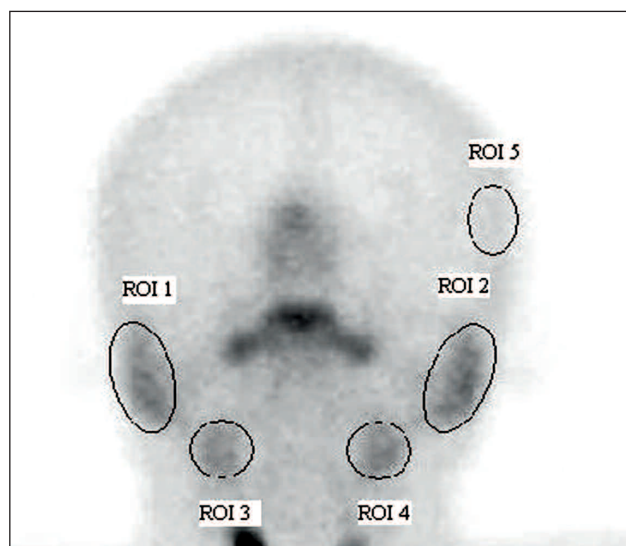
After the intravenous injection of about 185MBq of <sup>99m</sup>Tc-P, dynamic SG scintigraphy was performed using a double-head gamma camera (Siemens E.CAM, Siemens Medical Systems, Inc. Hoffman Estates, IL 60195, USA) equipped with a parallel-hole, low-energy, high-resolution collimator. The photopeak was centered at 140keV with a 20% window. A total of 25 frames of 60s each were acquired in the anterior position of the head and neck during the 25min study with a zoom of 1.33 and matrix of 128x128. Secretion of the SG was stimulated with 3mL concentrated lemon juice instilled orally with a syringe at 20min. The intervention and diagnostic procedure were well tolerated by all patients and healthy controls.

### Parameters studied, statistical semi-quantitative analysis

For semi-quantitative analysis, regions of interest (ROI) were manually drawn over each of the four major SG on the summation images of dynamic scintigraphy. A background ROI was placed in the temporal region (Fig. 1). Time-activity curves were generated for each SG (Fig. 2). The following points were assigned on the time-activity curve: a) vascular perfusion, at 1min; b) the maximum count before stimulation; c) the background count at the time of peak activity and d) the minimum count after stimulation (Fig. 2). The following glandular function parameters were calculated using the above a-d, the time-activity curves for each SG: uptake ratio (UR)=b/c, maximum accumulation(MA%)=(b-a)/ bx100, excretion fraction (EF%)=(b-d)/bx100.

The One Way Anova post-hoc Duncan's multiple comparison test was used for comparison of scintigraphic parameters

between patients with AR and healthy controls. Differences with a P-value less than 0.05 were accepted as significant, with data in the text presented as mean $\pm$ standard deviation (SD). Statistical Package for the Social Sciences (SPSS version 20.0) software program was used for statistical analysis.



**Figure 1.** Regions of interest (ROI) on the summation image, obtained by dynamic scintigraphy. ROI 1: right parotid gland; ROI 2: left parotid gland; ROI 3: right submandibular gland; ROI 4: left submandibular gland; ROI 5, background

## Results

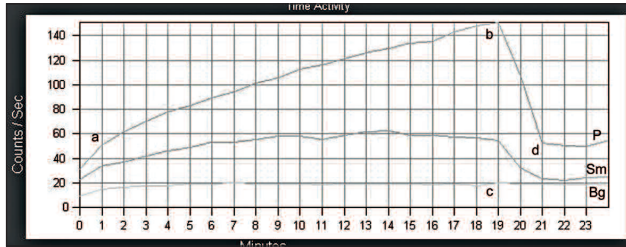
In Table 2, the mean $\pm$ SD values for the UR, MA% and EF% for the parotid and submandibular glands are presented.

Statistical analysis revealed that the UR, MA% and EF% values for the right and left major SG obtained in untreated and in desloratadine-montelukast treated patients were significantly lower than those in healthy controls ( $P < 0.05$ ) (Fig. 3). There was no statistically significant difference between desloratadine-montelukast treated and untreated patients ( $P > 0.05$ ).

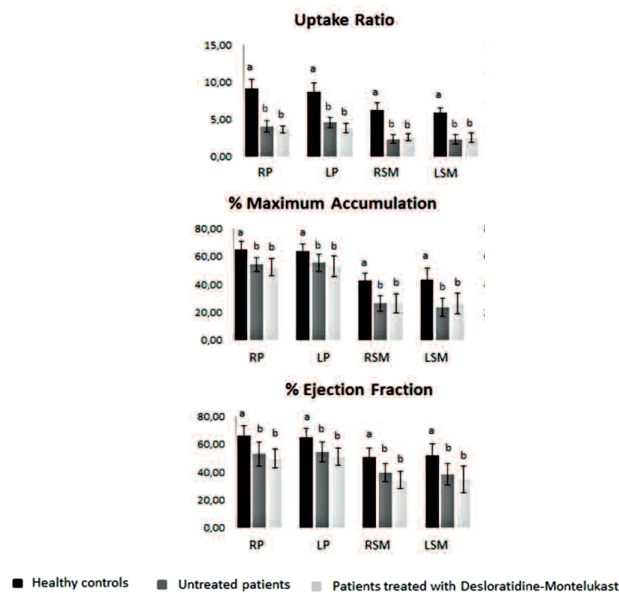
**Table 2.** Comparison of mean $\pm$ SD values of scintigraphic parameters in healthy controls and in the two patients' groups

Parameters	Healthy controls	Untreated patients	Treated patients	
UR	RP	9.16 $\pm$ 1.19	4.04 $\pm$ 0.76	3.64 $\pm$ 0.41
	LP	8.71 $\pm$ 1.19	4.59 $\pm$ 0.67	3.82 $\pm$ 0.68
	RSM	6.27 $\pm$ 1.03	2.34 $\pm$ 0.57	2.56 $\pm$ 0.45
	LSM	5.86 $\pm$ 0.74	2.30 $\pm$ 0.60	2.52 $\pm$ 0.65
% MA	RP	65.09 $\pm$ 5.55	54.30 $\pm$ 5.04	52.20 $\pm$ 6.11
	LP	63.84 $\pm$ 5.34	55.51 $\pm$ 6.03	52.89 $\pm$ 7.55
	RSM	42.76 $\pm$ 5.17	26.37 $\pm$ 5.53	26.34 $\pm$ 6.83
	LSM	43.51 $\pm$ 8.29	23.56 $\pm$ 6.66	26.17 $\pm$ 7.45
% EF	RP	66.41 $\pm$ 7.16	53.07 $\pm$ 8.78	49.73 $\pm$ 6.68
	LP	65.21 $\pm$ 6.51	54.52 $\pm$ 7.30	50.99 $\pm$ 6.17
	RSM	50.79 $\pm$ 6.31	39.59 $\pm$ 6.52	34.26 $\pm$ 6.28
	LSM	52.24 $\pm$ 8.03	38.37 $\pm$ 7.69	34.78 $\pm$ 9.58

UR: uptake ratio, MA: maximum accumulation, EF: ejection fraction, RP: right parotid; LP: left parotid; RSM: right submandibular gland; LSM: left submandibular gland.



**Figure 2.** A schematic presentation of patients' time activity curves from one P and one Sm. The symbol a is representing vascular perfusion at 1min; b, is the maximum count before stimulation; c, the background (bg) counts at the time of peak activity; and d, the minimum counts after stimulation.



**Figure 3.** Results are: means $\pm$ SD. Comparison of the uptake ratio, maximum accumulation percentage and percentage ejection fraction values in patients and healthy controls by using the Duncan test. The means in the same column with the same letter were not significantly different ( $P=0.05$ ). RP: right parotid; LP: left parotid; RSm: right submandibular gland; LSM: left submandibular gland.

## Discussion

Allergic rhinitis is an inflammatory disorder of the nasal mucosa, induced by an immunoglobulin E (IgE)-mediated reaction [14] and is associated with systemic inflammation [15]. Allergen exposure leads to symptoms such as nasal itching, sneezing, rhinorrhea, and nasal congestion [3]. In addition, dry mouth signs have been described [16]. Reduced salivary flow rate was reported by using sialometry and salivary scintigraphy in patients with AR [17]. In our study, the difference in the salivary flow rate between AR and health controls was statistically significant, similar to previous reports [5, 17].

Monotherapy with montelukast and combination treatment with montelukast and desloratadine induces improvement in the quality of life, in patients suffering from persistent AR [18]. Montelukast has been shown to have secondary anti-inflammatory properties, apparently unrelated to conventional antagonism of leukotriene receptors [19]. Furthermore, a protective effect of montelukast on SG has been reported [10].

Oral antihistamines are recommended as first choice med-

ications for AR [20]. The first generation antihistamines such as diphenhydramine, block histaminic and muscarinic receptors, and are recognized as having clinically significant anticholinergic adverse effects. Dry mouth, constipation and urinary retention are attributed to the antimuscarinic effects of these drugs [21]. The second generation antihistamines mainly block histaminic receptors. Desloratadine, a second generation antihistamine, is effective in the treatment of AR either intermittent or persistent [22]. Although antimuscarinic effects have not been reported with most of the second generation antihistamines, it is indicated that desloratadine has higher anticholinergic selectivity as compared to diphenhydramine and this may be the cause for dry mouth [23, 24]. It has also been reported that desloratadine is effective for itching and rhinorrhea in AR, but less effective for nasal congestion [25].

Other researchers have reported that montelukast could reduce nasal congestion in persistent AR and that combined treatment with desloratadine and montelukast is more effective than monotherapy with montelukast for improvement of nasal congestion [26].

Combined desloratadine and montelukast treatment on SG functions in AR patients using  $^{99m}\text{Tc}$ -P SG scintigraphy has not been reported in the literature. As for xerostomia and its negative effects on the quality of life, although not mentioned in our results, it is our impression that this treatment did not improve xerostomia.

Accurate assessment of SG function is important in patients with AR suffering from symptoms like xerostomia because subjective symptoms can differ from the results of an objective analysis [27]. Several methods have been suggested to evaluate SG function such as CT, sialography, SG ultrasonography, and labial SG biopsy. Nevertheless, these methods are either invasive or do not allow semi-quantitative measurements [22]. SG scintigraphy offers a semi-quantitative evaluation. Due to its low radiation dose, scintigraphy is also safe for these patients [28].

There have been few studies using SG scintigraphy for estimating SG function in AR [5, 17]. A lower salivary flow rate was reported in patients with AR compared to healthy controls [17]. In SG scintigraphy, no significant difference was found in their functional parameters between AR patients treated with levocetirizine-a third generation antistaminic and healthy controls [5]. AR patients have hypofunction of SG before treatment. Since only this 3rd generation drug was effective, we studied the combination of the 2 other drugs to see a possible treatment effect on SG functions using SG scintigraphy for the first time. We found no difference among patients treated with desloratadine and montelukast as compared to patients left untreated. The reason may be related to the daily use of montelukast sodium 10mg for 6 weeks that has insufficient protective effect on SG functions in patients with AR. Further comparative studies are needed.

*In conclusion*, our study showed that hypofunction of SG was present in all our patients with AR. Furthermore, combined treatment with montelukast and desloratadine did not improve SG functions as tested by semi-quantitative SG scintigraphy.

*The authors declare that they have no conflicts of interest.*

## Bibliography

1. Skoner DP. Allergic rhinitis: definition, epidemiology, pathophysiology, detection, and diagnosis. *J Allergy Clin Immunol* 2001; 108: S2-8.
2. Bousquet J, Van Cauwenberge P, Khaltaev N et al. Allergic rhinitis and its impact on asthma. *J Allergy Clin Immunol* 2001; 108: S147-334.
3. Ng ML, Warlow RS, Chrishanthan N et al. Preliminary criteria for the definition of allergic rhinitis: a systematic evaluation of clinical parameters in a disease cohort (II). *Clin Exp Allergy* 2000; 30: 1417-22.
4. Cingi C, Oghan F, Eskizmir G et al. Desloratadine-montelukast combination improves quality of life and decreases nasal obstruction in patients with perennial allergic rhinitis. *Int Forum Allergy Rhinol* 2013; 3: 801-6.
5. Seven B, Yoruk O, Varoglu E et al. Evaluation by <sup>99m</sup>Tc-pertechnetate scintigraphy of the effect of levocetirizine on salivary glands function, in allergic rhinitis patients. *Hell J Nucl Med* 2009; 12: 119-22.
6. Broccoletti R, Massolini G, Carbone M et al. Potential benefit of nizatidine in female patients with idiopathic xerostomia: A pilot study. *Eur Geriatr Med* 2013; 4: 199-201.
7. Nayak AS, Schenkel E. Desloratadine reduces nasal congestion in patients with intermittent allergic rhinitis. *Allergy* 2001; 56: 1077-80.
8. Meltzer EO, Prenner BM, Nayak A et al. Efficacy and tolerability of once-daily 5mg desloratadine, an H-1-receptor antagonist, in patients with seasonal allergic rhinitis - Assessment during the spring and fall allergy seasons. *Clin Drug Invest* 2001; 21: 25-32.
9. Patel P, Philip G, Yang W et al. Randomized, double-blind, placebo-controlled study of montelukast for treating perennial allergic rhinitis. *Ann Allerg Asthma Im* 2005; 95: 551-7.
10. Koca G, Gultekin SS, Han U et al. The efficacy of montelukast as a protective agent against I-131-induced salivary gland damage in rats: scintigraphic and histopathological findings. *Nucl Med Commun* 2013; 34: 507-17.
11. Kumar BS, Sathasivasubramanian SP. The role of salivary gland scintigraphy in detection of salivary gland dysfunction in type 2 diabetic patients. *Indian journal of nuclear medicine: IJNM* 2012; 27: 16-9.
12. Orsal E, Seven B, Keles M et al. Assessment of salivary gland function in patients after successful kidney transplantation using <sup>99m</sup>Tc-pertechnetate salivary gland scintigraphy. *Hell J Nucl Med* 2013; 16: 107-10.
13. Keles M, Seven B, Varoglu E et al. Salivary gland function in continuous ambulatory peritoneal dialysis patients by <sup>99m</sup>Tc-pertechnetate scintigraphy. *Hell J Nucl Med* 2010; 13: 26-9.
14. Blaiss MS, Meltzer EO, Derebery MJ et al. Patient and healthcare-provider perspectives on the burden of allergic rhinitis. *Allergy Asthma Proc* 2007; 28(Suppl 1): S4-10.
15. Braunstahl GJ, Fokkens WJ, Overbeek SE et al. Mucosal and systemic inflammatory changes in allergic rhinitis and asthma: a comparison between upper and lower airways. *Clin Exp Allergy* 2003; 33: 579-87.
16. Daniels TE. Evaluation, differential diagnosis, and treatment of xerostomia. *J Rheumatol* 2000; 61(Suppl): 6-10.
17. Yoruk O, Seven B, Varoglu E et al. Evaluation of salivary gland function in allergic rhinitis patients by [<sup>99m</sup>Tc] pertechnetate salivary gland scintigraphy. *Cent Eur J Med* 2010; 5: 246-50.
18. Ciebiada M, Ciebiada MG, Kmiecik T et al. Quality of life in patients with persistent allergic rhinitis treated with montelukast alone or in combination with levocetirizine or desloratadine. *J Invest Allerg Clin Immun* 2008; 18: 343-9.
19. Tintinger GR, Feldman C, Theron AJ et al. Montelukast: more than a cysteinyl leukotriene receptor antagonist? *The Scientific World Journal* 2010; 10: 2403-13.
20. Bousquet J, Khaltaev N, Cruz AA et al. Allergic Rhinitis and its Impact on Asthma (ARIA) 2008 update (in collaboration with the World Health Organization, GA(2)LEN and AllerGen). *Allergy* 2008; 63(Suppl 86): 8-160.
21. Bachert C, Maurer M. Safety and efficacy of desloratadine in subjects with seasonal allergic rhinitis or chronic urticaria: results of four postmarketing surveillance studies. *Clin Drug Investig* 2010; 30: 109-22.
22. Bachert C, van Cauwenberge P. Desloratadine treatment for intermittent and persistent allergic rhinitis: a review. *Clinical Therapeutics* 2007; 29: 1795-802.
23. Orzechowski RF, Currie DS, Valancius CA. Comparative anticholinergic activities of 10 histamine H1 receptor antagonists in two functional models. *Europ J Pharmacol* 2005; 506: 257-64.
24. Anolik R. Desloratadine and pseudoephedrine combination therapy as a comprehensive treatment for allergic rhinitis and nasal congestion. *Expert Opinion on Drug Metabolism & Toxicology* 2009; 5: 683-94.
25. Wallace DV, Dykewicz MS, Bernstein DI et al. The diagnosis and management of rhinitis: an updated practice parameter. *J Allergy Clin Immun* 2008; 122: S1-84.
26. Ciebiada M, Gorska-Ciebiada M, DuBuske LM et al. Montelukast with desloratadine or levocetirizine for the treatment of persistent allergic rhinitis. *Annals of Allergy, Asthma & Immunology* 2006; 97: 664-71.
27. Fox PC, Busch KA, Baum BJ. Subjective reports of xerostomia and objective measures of salivary gland performance. *J Amer Dental Assoc* 1987; 115: 581-4.
28. Booker J, Howarth D, Taylor L et al. Appropriate utilization of semi-quantitative analysis in salivary scintigraphy. *Nucl Med Commun* 2004; 25: 1203-10.