

# Novel use of hepatobiliary scintigraphy for the diagnosis of interleukin-2 cholangiopathy

Jon K. Marti<sup>1</sup> DO,  
Kevin P Banks<sup>2</sup> MD,  
Won S Song MD

1. Wilford Hall Medical  
Center, Department of  
Radiology,  
2200 Bergquist Dr, Lackland  
Air Force Base TX 78236,  
U.S.A

2. Nuclear Medicine Service,  
Brooke Army Medical  
Center,  
3851 Roger Brooke Drive,  
Fort Sam Houston  
TX, 78234, U.S.A

\*\*\*

#### Keywords:

-Interleukin-2  
-Cholangiopathy  
-Acalculous cholecystitis  
-Hepatobiliary scintigraphy

#### Corresponding Address:

Kevin P Banks, Nuclear  
Medicine Service, Brooke  
Army Medical Center,  
3851 Roger Brooke Drive,  
Fort Sam Houston  
TX, 78234, U.S.A.  
Tel: 1-210-916-1906,  
Fax: 1-210-916-0957  
E-mail:  
[kevin.banks@amedd.army.mil](mailto:kevin.banks@amedd.army.mil)

#### Received:

1 April 2010

#### Accepted:

12 April 2010

## Abstract

We report a case of interleukin-2 (IL-2) induced cholangiopathy diagnosed with the aid of hepatobiliary scintigraphy. Patient was a 32 years old, male with history of metastatic melanoma. Computed tomography (CT) upon admission demonstrated worsening of patient's metastatic lung disease with a normal appearance of the gallbladder. The patient was started on high dose IL-2 treatment for regression of his disease. Four days after IL-2 treatment was begun, the patient developed severe right upper quadrant pain and elevated liver function tests. A right upper quadrant ultrasound and surgical consultation were requested. Sonographic findings demonstrated diffuse gallbladder wall thickening, mural edema, a positive sonographic Murphy's sign, but no gallstones. The preliminary working diagnosis was acalculous cholecystitis versus IL-2 induced cholangiopathy. To clarify between these two entities, a hepatobiliary scan was obtained that demonstrated filling of the gallbladder with prompt biliary-to-bowel transit and normal liver function. In this case, the clinical presentation and history of recent IL-2 treatment were suggestive of IL-2 cholangiopathy, though the patient's co-morbidities and in-patient status raised concern for acalculous cholecystitis. Given the marked differences in treatment, hepatobiliary imaging was requested and found to be normal, making acalculous cholecystitis very unlikely. *In conclusion*, we believe this is the first case in which hepatobiliary scintigraphy was used to aid in the diagnosis of IL-2 induced cholangiopathy.

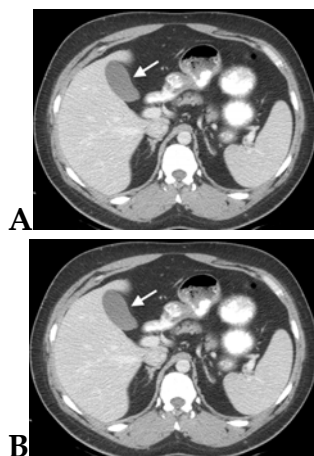
*Hell J Nucl Med 2010; 13(2):163-165 • Published on line: 22-6-2010*

## Introduction

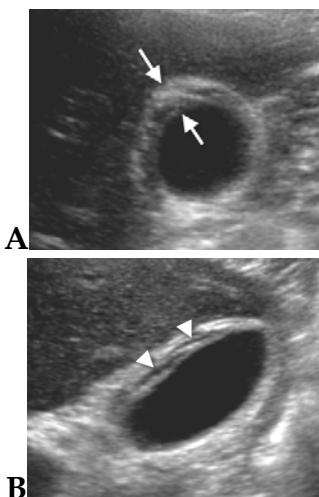
Radionuclide scans can be useful in clinical decision making for the evaluation of gallbladder disease. In the setting of acute right upper quadrant pain, the differential typically favors acute calculous or acalculous cholecystitis. Both typically present with gall bladder wall thickening in addition to other anatomic features of inflammation. The differential diagnosis of a thickened gallbladder wall on ultrasound or CT is broad and may also be the result of non biliary causes, such as cardiac and renal failure, hepatitis, ascites, or hypoalbuminemia, and human immunodeficiency virus (HIV) [1]. More recently, gallbladder wall thickening has been seen in patients treated with high dose interleukin-2 (IL-2) who develop IL-2 induced cholangiopathy [2, 3].

## Description of the case

A 32years old man with a history of metastatic melanoma was admitted for non specific chest wall pain. Computed tomography on admission showed multiple new pulmonary masses and a normal gallbladder (Fig. 1a, 1b). Findings were consistent with progression of known metastatic melanoma. After a contrast enhanced head CT was negative for intracranial disease, high dose interleukin-2 intravenous treatment was initiated for advanced metastatic melanoma. After 4 days of treatment, the patient developed severe right upper quadrant pain with elevation of alkaline phosphatase and total bilirubin levels. The total white blood count level was normal. Serologic tests for hepatitis A, B, and C were negative. Patient was afebrile and physical exam demonstrated moderate right upper quadrant pain, with no scleral icterus. Sonography demonstrated a diffusely thickened gallbladder wall with a positive sonographic Murphy's sign (Fig. 2a, 2b). The working diagnosis at this time favored acalculous cholecystitis. However, hepatobiliary imaging was important in confirming the definitive diagnosis of interleukin-2 cholangiopathy by demonstrating normal hepatic function with prompt gallbladder filling (Fig. 3a, 3b). The appropriate diagnosis led to the cessation of the IL-2 treatment and within 48 hours the patient's abdominal pain had resolved and his liver function studies had returned to baseline levels. Given the increased number of uses for interleukin-2 treatment, physicians need to be aware of this complication and include it in the differential diagnosis for diffuse gallbladder wall thickening [2, 3].



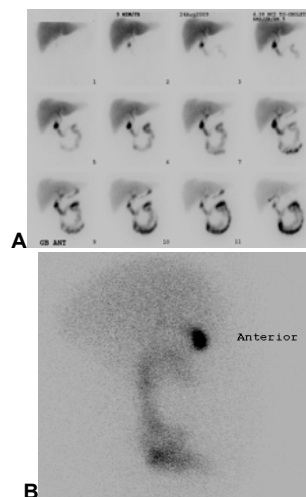
**Figures 1A-B.** Contrast enhanced axial CT of the chest, abdomen, and pelvis performed for re-assessment of patient's metastatic melanoma. (A) Image through the lower chest using lung window shows multiple new pulmonary masses and bilateral effusions (comparison not shown) consistent with severe interval progression of disease. (B) Image through the upper abdomen shows benign appearance of the gallbladder (arrow) without appreciable wall thickening/edema or surrounding inflammation.



**Figures 2A-B.** Abdominal ultrasound performed 5 days following CT and 4 days following initiation of interleukin-2 treatment. Exam performed for new onset of abdominal pain and abnormal liver function enzymes. (A) Transverse and (B) longitudinal images through the gallbladder show gallbladder wall thickening (arrows) with hypoechoic striations (arrowheads) consistent with mural edema. No stones are seen.

## Discussion

Radionuclide scans can be useful in clinical decision making for the evaluation of diffuse gallbladder wall thickening. The non infectious differential diagnosis of a thickened gallbladder wall on ultrasound or CT may be the result of non biliary causes, such as Radionuclide scans can be useful in clinical decision making for the evaluation of diffuse gallbladder wall thickening. The non infectious differential diagnosis of a thickened gallbladder wall on ultrasound or CT may be the result of non biliary causes, such as cardiac and renal failure, hepatitis, ascites, hypoalbuminemia, pancreatitis, and lymphatic obstruction [1]. Gallbladder wall thickening can also be commonly seen in patients treated with high dose IL-2 treatment [2, 3].



**Figures 3A-B.** Hepatobiliary scan performed using 162MBq of technetium-99m Choletec for clinical concern of acalculus cholecystitis. (A) Compressed dynamic images (5min each for 1h total) show normal hepatic uptake, biliary-to-bowel transit and prompt filling of the gallbladder. Incidental note is made of entero gastric reflux. (B) Gallbladder filling confirmed on right lateral view.

Other etiologies that need to be considered are as follows: gallbladder carcinoma, HIV, CMV, salmonella infection, leukemic infiltration, prolonged fasting, adenomyomatosis, and acute or chronic cholecystitis [1]. Diagnosing acalculous cholecystitis or acute cholecystitis in critically ill patients can sometimes be difficult due to atypical presentations and additional confounding medical problems. In patients receiving Interleukin-2 treatment with diffuse gallbladder wall thickening and a normal hepatobiliary scan, the diagnosis of IL-2 cholangiopathy can be made with confidence. Physicians should know about this diagnosis to aid in eliminating the need for unnecessary and expensive testing and possible invasive surgical intervention or percutaneous cholecystotomy.

IL-2 is a type of cytokine, a natural protein produced in the body. It stimulates the T-lymphocytes (T-cells) to grow and divide. Administering immunotherapy with IL-2 in high doses (inpatient only treatments) is the only FDA approved systemic treatment currently available that is capable of curing metastatic renal cell carcinoma (RCC) and malignant melanoma [4]. Candidates for the high dose IL-2 treatment must not have any intracranial metastatic disease. Also, due to serious side effects patients must also have normal cardiac and lung function. Response rates to IL-2 regimens for metastatic RCC and malignant melanoma of 8%-20% have been reported, with some reports of up to 80% of the RCC treatment responders obtaining a complete response, with no disease recurrence [5].

Other potential treatments for IL-2 have been used or studied in HIV, lung cancer, colon cancer, leukemia and lymphoma. Reports of high dose IL-2 treatment in previously treated end stage pediatric patients with refractory or relapsed solid malignancies such as metastatic neuroblastoma and osteosarcoma have also shown some promise of complete remission [6].

However, treatment with IL-2 is associated with some severe, but reversible side effects [2, 3]. The major toxicity of high dose IL-2 results from a capillary-leak syndrome, leading to fluid extravasation from tissues with hypotension and oliguria. Other severe side effects are prolonged neutropenia and thrombocytopenia. All of

these side effects together can mimic septic shock, but are completely reversible. Additionally, reversible transient hepatitis and right upper quadrant pain with associated gallbladder wall thickening (IL-2 cholangiopathy) is often seen in patients. The leaky capillary side effects are hypothesized to cause the edema within the gallbladder wall [7]. It has been noted that reduction in the dose decreases side effects of the IL-2 high dose treatment, with complete reversibility of the side effects in nearly all patients within 48 hours of cessation of treatment.

IL-2 induced cholangiopathy should be recognized as a distinct entity to avoid unnecessary, expensive diagnostic testing and potentially invasive interventions. Radiologists can aid in this diagnosis by being cognizant of the radiologic manifestations of the high dose IL-2 therapy and the effects upon the gallbladder.

*In conclusion*, it should be kept in mind the IL-2 cholangiopathy effects and the abdominal pain type symptoms that are completely reversible with discontinuing treatment.

## Bibliography

1. van Brieda Vriesman AC, Engelbrecht MR, Smithuis RH, Puylaert JB. Diffuse Gallbladder Wall Thickening: Differential Diagnosis. *AJR* 2007; 188: 495-501.
2. Premkumar AH, Walworth CM, Vogel S et al. Prospective Sonographic Evaluation of Interleukin-2-induced Changes in the Gallbladder. *Radiology* 1998; 206: 393-6.
3. Powell FC, Spooner KM, Shawker TH et al. Symptomatic interleukin-2 induced cholecystopathy in patients with HIV infection. *AJR* 1994; 163: 117-21.
4. Rosenberg SA, Lotze MT, Muul LM et al. A progress report on the treatment of 157 patients with advanced cancer using lymphokine activated killer cells and interleukin-2 or high dose interleukin-2 alone. *N Engl J Med* 1987; 316: 889-905.
5. Rosenberg SA. Interleukin 2 for patients with renal cancer. *Nat Clin Pract Oncol* 2007; 4: 497.
6. Schwinger W, Klass V, Benesch M et al. Feasibility of high-dose interleukin-2 in heavily pretreated pediatric cancer patients. *Ann of Oncol* 2005; 16: 1199-206.
7. Lissoni P, Barni S, Cattaneo G et al. Activation of the complement system during immunotherapy of cancer with interleukin-2: a possible explanation of the capillary leak syndrome. *Int J Biol Markers* 1990; 5: 195-207.