

Attenuation correction of myocardial perfusion SPET in patients of normal body mass index

**Mohamed Shawgi MSc, MRCP,
Christine M. Tonge MSc,
Richard S. Lawson PhD,
Sivakumar Muthu MSc, MRCP,
Jacqueline James MSc, MRCGP,
FRCP,
Parthiban Arumugam, MSc,
FRCP**

Nuclear Medicine Centre,
Central Manchester University
Hospitals, Manchester, United
Kingdom

Keywords: Attenuation correction
- Myocardial perfusion
- SPET - Normal BMI

Correspondence address:

Dr Mohamed Shawgi, Nuclear
Medicine Centre, Manchester
Royal Infirmary, Oxford Rd,
Manchester, M13 9WL, UK
Tel: +44 0161 276 4820 or 4786;
Fax: + 44 0161 276 8023;
E-mail: mshawgi@gmail.com

Received:

22 September 2012

Accepted:

13 November 2012

Abstract

Soft tissue attenuation artefacts are more likely to occur in patients with high body mass index (BMI) undergoing myocardial perfusion imaging (MPI) and therefore it is routine practice in our department to perform attenuation correction in this group of patients. However, we suspected that attenuation artefacts may also occur in patients with normal BMI. *We collected data prospectively on 57 patients with BMI less than 25kg/m² who underwent stress-rest MPI single photon emission tomography (SPET) as part of their standard management at our institution. The differences between the attenuation corrected (AC) and non attenuation corrected (NC) images were evaluated by two experienced readers blinded to patient gender and clinical details. Visual improvement in perfusion with attenuation correction was seen in 54.4% of patients with normal BMI and was more common in males (84.2%) than females (39.5%). Discordances between AC and NC were most frequent in the inferior, inferolateral and anteroseptal segments in both males and females and were also seen in the apical and anterior segments in some patients, mainly in females, in keeping with the well-recognized distribution pattern for attenuation artefacts. In conclusion, although a small sample size was used in this study, changes in appearance with attenuation correction likely to represent attenuation artefacts were seen in 54.4% of patients with normal BMI and were two times more common in males than females. These changes were felt to be clinically relevant in that they could lead to a change in the final report and may ultimately affect the diagnosis and clinical management. Thus, attenuation correction could be of value in patients of normal BMI. Further larger studies with correlation with clinical follow up or invasive coronary angiography are warranted.*

Hell J Nucl Med 2012; 15(3): 215-219

Published on line: 2 December 2012

Introduction

Soft tissue attenuation is a major limitation of myocardial perfusion imaging (MPI) with single photon emission tomography (SPET) due to artefacts which are often quite variable and can degrade the quality of images [1, 2]. Although soft tissue attenuation artefacts are more likely to occur in patients with high body mass index (BMI) we suspected that they may also occur in a proportion of patients with normal BMI. To date, none of the studies in the literature looked exclusively at soft tissue attenuation in patients of normal BMI. Here we present our experience relating to the latter subgroup of patients.

Materials and methods

Patients

The study was approved by the Local Research Ethics Committee. Informed consent was obtained from all participating patients.

Patients with suspected coronary artery disease who were referred for MPI SPET imaging at our institution and whose body mass index was less than 25kg/m² were invited to take part in the study. Excluded were those who were claustrophobic and patients who found it hard to raise their arms above the head.

Sixty one patients (19 male, 42 female) accepted the invitation. Four studies were excluded, 3 due to high extra-cardiac activity and 1 due to excessive patient motion on the computed tomography (CT) component. Therefore, complete data was obtained in 57 patients.

SPET myocardial perfusion imaging

A two day MPI SPET standard departmental protocol was used. All patients were stressed using exercise or pharmacological stress with intravenous Adenosine or Dobutamine (in

conjunction with low load exercise). Stress and rest electrocardiography (ECG) gated SPET images were acquired 45-60min after injection of 400MBq ^{99m}Tc Tetrofosmin in accordance with the United Kingdom's Administration of Radioactive Substances Advisory Committee (ARSAC) recommendations. The patients were scanned in the supine position with both arms supported above the head using a dual head gamma camera (GE Millennium VG with Hawkeye or GE Infinia with Hawkeye 4). An energy window of 20% centred around 140keV was used and 60 images were acquired into a 64x64 matrix over a 180 arc. Attenuation correction using CT attenuation maps (CTAC) was performed for both the stress and rest studies. Images were transferred to a Xeleris work station (GE Healthcare) for reconstruction and analysis.

SPET analysis

Tomographic reconstructions were obtained using OSEM iterative reconstruction with and without CTAC. The reconstruction was carried out using 10 subsets and 2 iterations. A post-processing Butterworth filter (cut-off frequency 0.3 cycle/cm, order 5) was applied to the reconstructed data.

Image interpretation

Using quantitative perfusion SPET (QPS) software (Cedars-Sinai Medical Centre, Los Angeles), two sets of bulls-eye images were created for the attenuation corrected (AC) and non-corrected (NC) images. Each bulls-eye plot was further divided into 5 regions representing the myocardial walls: anterior, septal, apical, inferior and lateral. The images were visually interpreted by two experienced readers without prior knowledge of gender or clinical history. The readers were asked to document differences in perfusion between the AC and NC image sets and to record whether these differences were sufficient to lead to a clinically significant change in the diagnostic report. Any differences in interpretation were resolved by consensus.

Results

Patient population

The patient characteristics are summarised in Table 1. More females were included in this trial than males but this was not unexpected because the majority of patients who are referred to us and who undergo MPI within our department are female. The BMI distribution of the patient cohort is shown in Figure 1.

Table 1. Characteristics of study population (n=57)

	Number of patients	%
Male	19	33.3
Female	38	66.7
BMI (Mean \pm SD)	22 \pm 2	N/A
Age (Mean \pm SD)	62 \pm 13	N/A
Exercise stress	4	7.0
Adenosine stress	50	87.7
Dobutamine stress	3	5.3

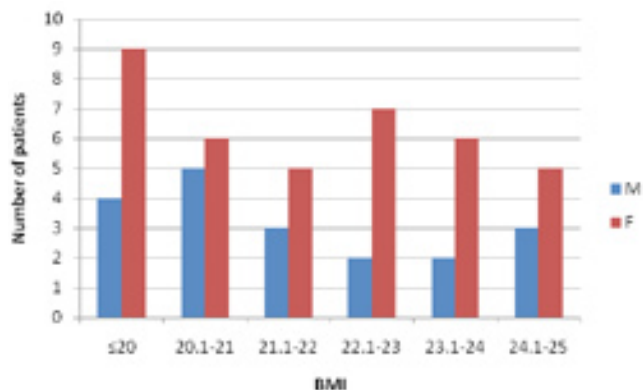


Figure 1. Distribution of body mass index (BMI).

Interpretation of images

Two experienced readers compared the NC and AC images and categorised each set of images into one of three likelihood groups: (i) no difference in perfusion between AC and NC; (ii) small difference in perfusion (in one or more segments) between AC and NC, i.e. insufficient to lead to a clinically significant change in the diagnostic report; and (iii) marked difference in perfusion between AC and NC, i.e. sufficient to lead to a clinically significant change in the diagnostic report. The results are presented in Table 2.

Table 2. Differences between AC and NC based on visual interpretation

	Number of patients (n=57)		
	Male	Female	Total
Marked difference	9	8	17
Small difference	7	7	14
No difference	3	23	26

Visual improvement in perfusion with attenuation correction was seen in 31 out of 57 (54.4%) patients. Discordances between AC and NC which were judged by the readers to be sufficient to lead to a clinically significant change in the diagnostic report were seen in 9 males and 8 females. Differences in perfusion with CTAC were more prevalent in males with 16 out of 19 (84.2%) showing marked or small differences between NC and AC.

Examples of marked differences in perfusion between AC and NC are shown in Figure 2 for two men with BMI 24 and a woman with BMI 23. The images show apparent perfusion abnormalities in various segments on the NC images with clear improvement within these segments on the AC images.

Analysis of diagnostic reports

All 57 studies were further analysed by two experienced readers using complete sets of image data including rotating raw images, reconstructed slices displayed in short axis, vertical long axis and horizontal long axis with and without AC in addition to ECG gated reconstructions. Each study was reported as: normal, probably normal, equivocal, probably abnormal or abnormal. Fixed defects were seen in 22 patients and were more common in the inferior, inferoseptal and anteroseptal segments in males and in the apical and anterior segments in females (Fig. 3). Reversible defects were seen in 10 out of 57 patients and were more common in males than females.

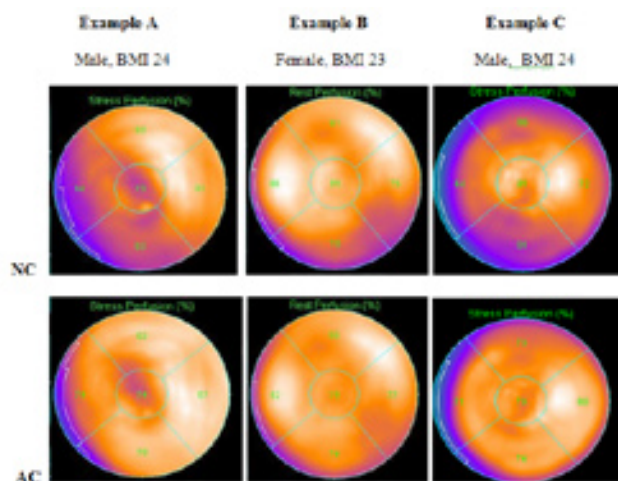


Figure 2. Examples of marked differences in perfusion between AC and NC.

Discussion

Attenuation artefacts can reduce the interpretative and quantitative accuracy of MPI SPET in comparison to other cardiac imaging techniques [3-6]. Several techniques have been developed to counteract the problem posed by attenuation artefacts including ECG-gated acquisitions, utilisation of computerised quantitative software, and development of new attenuation correction methods. CTAC has attained widespread acceptance as a useful tool in nuclear cardiology [7-14]. A transmission CT scan produces a patient-specific attenuation map which is incorporated into the reconstruction algorithm and allows mathematical correction of the emission data for photon absorption. The magnitude of photon attenuation is related to several factors including the density and location of the attenuating tissue in addition to the patient's gender, body size and position under the camera. Several studies have shown that attenuation correction is beneficial in both obese and non obese patients and that the benefit is greater in patients of high BMI [13, 15-18]. However, none of these studies looked specifically at patients of normal BMI (<25kg/m²) or at the frequency or pattern of attenuation in this group of patients. It is commonly assumed that soft tissue attenuation is exclusively a problem in obese patients and that they occur infrequently in patients with normal BMI [19]. Therefore, attenuation correction is usually reserved for

patients who are obese and is not performed on patients with normal BMI, as was the case in our department.

The remit of this study was not to evaluate the diagnostic accuracy of attenuation correction as this has been extensively covered in the literature, but to determine whether there is a difference in appearance between attenuation corrected and non corrected images in patients with normal BMI. The results presented show that on comparing NC and AC images, improvement in perfusion with attenuation correction was seen in 54.4% of patients of normal BMI. A considerable number of patients showed marked visual improvement in perfusion with attenuation correction which was judged by the readers to be sufficient to lead to a clinically significant change in the diagnostic report and could therefore affect the diagnosis and management in clinical practice. The experienced readers felt that the changes in appearance with attenuation correction were most likely to represent attenuation artefacts particularly as the discordances between AC and NC were predominantly in regions where attenuation artefacts are known to occur.

The true prevalence of soft tissue attenuation artefacts is unknown but estimates ranging from 20% to 50% have been reported in the literature [20, 21]. It is well recognized that artefacts involving the inferior wall are frequently seen in men due to attenuation by subdiaphragmatic structures; In females, attenuation of the anterior, lateral or apical segments is more common due to attenuation by breast tissue. Breast attenuation in females is estimated to occur in 40% of studies and inferior attenuation in men in approximately 25% [22, 23]. This is reflected in our cohort (Fig. 3): apical and anterior segment defects were more frequent in females and defects involving the inferior segment were more common in men. Differences between AC and NC images were most frequent in the inferior, inferolateral and anteroseptal regions in both males and females although changes were also seen in the apical and anterior region in some patients, mainly females. Differences in perfusion were more common in males (84.2%) than females (39.5%). This suggests that CTAC may be more useful in men than women although we acknowledge that twice as many women as men were examined in this study.

Is ECG gating not enough?

ECG gating improves the diagnostic specificity of MPI SPET through assessment of wall motion and thickening [24]. Several studies have shown that attenuation correction when


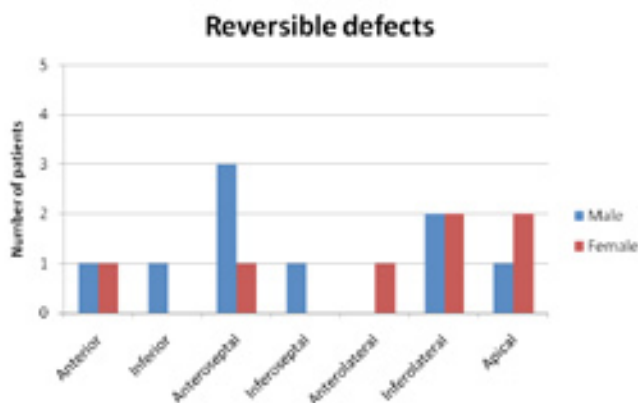


Figure 3. Fixed and reversible defects by segment.

used in conjunction with ECG gating improves reader confidence and significantly increases the number of studies reported as definitely normal or abnormal [18, 24].




Figure 4. Interpretation of MPI SPET studies.

Our results (Fig. 4) showed that the use of ECG gated MPI in patients with normal BMI resulted in more studies being reported as definitely normal in comparison to MPI alone. The addition of AC to gated MPI resulted in further increase in the definitely normal category and a reduction in the non definite categories (i.e. probably normal, probably abnormal and equivocal). The results also showed a reduction in the small number of scans reported as definitely abnormal when AC gated MPI is used in comparison to MPI alone, although this was comparable to the reduction seen with gated MPI alone. The results are in line with previous literature which showed a pronounced increase in the 'normal' interpretation category with combined AC and ECG gating compared to gated MPI or MPI alone [18].

Overall, the results of this study suggest that the use of attenuation correction in combination with ECG-gating in MPI SPET would be useful in all patients regardless of their BMI. The potential benefits of using attenuation correction in all patients include increased interpretative confidence, enhanced artefact recognition and hence improved specificity, possible improvement in normalcy rates and facilitation of stress only imaging [25].

Potential pitfalls of AC

Although newer algorithms and advanced computer software have led to improved attenuation correction, none of the available attenuation correction techniques completely overcome attenuation artefacts and some may even introduce new forms of artefact [26]. Our study involved rigorous quality assurance of the AC process, image reconstruction and registration to ensure maximum robustness of the system and to ensure that new artefacts were not introduced. This is essential because artefacts can occur as a result of overcorrection, truncation, scatter or misregistration of emission and transmission scans [25, 27]. Misregistration artefacts occur because the emission and transmission scans are acquired sequentially and may therefore be affected by alterations in patient position, breathing pattern or patient motion [28, 29]. It is essential to review the fused images prior to evaluation of the attenuation corrected images. Furthermore, caution should be exercised when using attenuation correction so as to avoid wrong interpretation and it is fundamental that the uncorrected images are reviewed

prior to the corrected images so that the latter are not read in isolation.

Another potential disadvantage of CTAC is the additional radiation dose to the patient which is estimated to be around 0.8-1.6mSv [30]. CTAC also has cost and time implications. There is increased cost associated with purchase of a SPET/CT imaging system, reconstruction software, increased storage requirements and additional medical physics expert or specialist time with regards to quality control of the attenuation correction equipment and images [25]. Exact cost analysis is beyond the scope of this report. Nonetheless, these disadvantages may be outweighed by the benefits of AC as a normal attenuation corrected SPET MPI may lead to savings in cost, time and radiation by preventing an unnecessary coronary angiogram.

Study limitations

One limitation of this study is that only a small number of patients were recruited. Although invitations were sent out to more than 100 patients who met the inclusion criteria, only 61 agreed to take part in the study. Another limitation is the lack of correlation with coronary angiography. The majority of MPI SPET scans were reported as 'normal' or 'probably normal' and therefore invasive cardiac investigations were not instigated.

In conclusion, although a small sample size was used in this study, changes in appearance with attenuation correction likely to represent attenuation artefacts were seen in 54.4% of patients with normal BMI and were two times more common in males than females. These changes were felt to be clinically relevant in that they would lead to a clinically significant change in the final diagnostic report and could therefore affect the diagnosis and clinical management. Thus, attenuation correction could be of value in patients of normal BMI. Further larger studies with correlation with clinical follow up or invasive coronary angiography are warranted.

The authors declare that they have no conflicts of interest.

Bibliography

1. Corbett JR, Ficaro EP. Attenuation correction: a better cardiac SPECT. *ACC Current Journal Review* 1999; 8: 62-8.
2. Hendel RC, Corbett JR, Cullom SJ et al. The value and practice of attenuation correction for myocardial perfusion SPECT imaging: a joint position statement from the American Society of Nuclear Cardiology and the Society of Nuclear Medicine. *J Nucl Cardiol* 2002; 9: 135-43.
3. Corbett JR, Cahill JM, Krtzman JN et al. Diagnostic accuracy of hybrid cardiac SPECT/CT for attenuation correction of stress myocardial perfusion imaging in obese compared to normal weight patients. *J Nucl Cardiol* 2007; 15: S19.
4. Picano E, Bedetti G, Varga A, Cseh E. The comparable diagnostic accuracies of dobutamine-stress and dipyridamole-stress echocardiographies: a meta-analysis. *Coron Artery Dis* 2000; 11: 151-9.
5. Kim C, Kwok YS, Heagerty P, Redberg R. Pharmacologic stress testing for coronary disease diagnosis: A meta-analysis. *Am Heart J* 2001; 142: 934-44.
6. Heijnenbroek-Kal MH, Fleischmann KE, Hunink MG. Stress echocardiography, stress single-photon-emission computed tomography and electron beam computed tomography for

- the assessment of coronary artery disease: a meta-analysis of diagnostic performance. *Am Heart J* 2007; 154: 415-23.
7. Heller GV, Links J, Bateman TM et al. American Society of Nuclear Cardiology and Society of Nuclear Medicine joint position statement: attenuation correction of myocardial perfusion SPECT scintigraphy. *J Nucl Cardiol* 2004; 11: 229-30.
 8. Masood Y, Liu YH, Depuey G et al. Clinical validation of SPECT attenuation correction using x-ray computed tomography-derived attenuation maps: multicenter clinical trial with angiographic correlation. *J Nucl Cardiol* 2005; 12: 676-86.
 9. Tonge CM, Manoharan M, Lawson RS et al. Attenuation correction of myocardial SPECT studies using low resolution computed tomography images. *Nucl Med Commun* 2005; 26: 231-7.
 10. Fricke E, Fricke H, Weise R et al. Attenuation correction of myocardial SPECT perfusion images with low-dose CT: evaluation of the method by comparison with perfusion PET. *J Nucl Med* 2005; 46: 736-44.
 11. Seo Y, Wong KH, Sun M et al. Correction of photon attenuation and collimator response for a body-contouring SPECT/CT imaging system. *J Nucl Med* 2005; 46: 868-77.
 12. Utsunomiya D, Tomiguchi S, Shiraishi S et al. Initial experience with X-ray CT based attenuation correction in myocardial perfusion SPECT imaging using a combined SPECT/CT system. *Ann Nucl Med* 2005; 19: 485-9.
 13. Genovesi D, Giorgetti A, Gimelli A et al. Impact of attenuation correction and gated acquisition in SPECT myocardial perfusion imaging: results of the multicentre SPAG (SPECT Attenuation Correction vs Gated) study. *Eur J Nucl Med Mol Imaging* 2011; 38: 1890-8.
 14. Pazhenkottil AP, Ghadri JR, Nkoulou RN et al. Improved outcome prediction by SPECT myocardial perfusion imaging after CT attenuation correction. *J Nucl Med* 2011; 52: 196-200.
 15. Bateman TM, Heller GV, Johnson LL et al. Does attenuation correction add value to non-attenuation corrected ECG-gated technetium-99m sestamibi SPECT [abstract]. *J Nucl Cardiol* 2003; 10: S91
 16. Grossman GB, Garcia EV, Bateman TM et al. Quantitative Tc-99m sestamibi attenuation-corrected SPECT: development and multicenter trial validation of myocardial perfusion stress gender-independent normal database in an obese population. *J Nucl Cardiol* 2004; 11: 263-72.
 17. Thompson RC, Heller GV, Johnson LL et al. Value of attenuation correction on ECG-gated SPECT myocardial perfusion imaging related to body mass index. *J Nucl Cardiol* 2005; 12: 195-202.
 18. Heller GV, Bateman TM, Johnson LL et al. Clinical value of attenuation correction in stress-only Tc-99m sestamibi SPECT imaging. *J of Nuclear Cardiology* 2005; 11: 273-81.
 19. Hendel RC. Attenuation correction: eternal dilemma or real improvement? *Q.J.Nucl.Med.Mol.Imaging* 2005; 49: 30-42.
 20. Desmarais RL, Kaul S, Watson DD, Beller GA. Do false positive thallium-201 scans lead to unnecessary catheterization? Outcome of patients with perfusion defects on quantitative planar thallium-201 scintigraphy. *J.Am.Coll.Cardiol* 1993; 21: 1058-63.
 21. Hendel RC, Berman DS, Cullom SJ et al. Multicenter clinical trial to evaluate the efficacy of correction for photon attenuation and scatter in SPECT myocardial perfusion imaging. *Circulation* 1999; 99: 2742-9.
 22. Johnstone DE, Wackers FJT, Berger HJ et al. Effect of Patient Positioning on Left Lateral Thallium-201 Myocardial Images. *J Nucl Med* 1979; 20: 183-8.
 23. Manglos SH, Thomas FD, Gagne GM, Hellwig BJ. Phantom study of breast tissue attenuation in myocardial imaging. *J Nucl Med* 1993; 34: 992-6.
 24. Smanio PE, Watson DD, Segalla DL et al. Value of gating of technetium-99m sestamibi single-photon emission computed tomographic imaging. *J Am Coll Cardiol* 1997; 30: 1687-92.
 25. Garcia EV. SPECT attenuation correction: An essential tool to realize nuclear cardiology's manifest destiny. *J Nucl Cardiol* 2007; 14: 16-24.
 26. Anagnostopoulos C, Harbinson M, Kelion A et al. Procedure guidelines for radionuclide myocardial perfusion imaging. *Heart* 2004; 90 Suppl 1: i1-10.
 27. Heller EN, DeMan P, Liu YH et al. Extracardiac activity complicates quantitative cardiac SPECT imaging using a simultaneous transmission-emission approach. *J Nucl Med* 1997; 38: 1882-90.
 28. Goetze S, Wahl RL. Prevalence of misregistration between SPECT and CT for attenuation-corrected myocardial perfusion SPECT. *J Nucl Cardiol* 2007; 14: 200-6.
 29. Huang R, Li F, Zhao Z et al. Hybrid SPECT/CT for attenuation correction of stress myocardial perfusion imaging. *Clin Nucl Med* 2011; 36: 344-9.
 30. Vija A, Rempel T, Whawman E, Engdahl J. Method to minimize dose for CT attenuation correction in SPECT. In: *IEEE Nuclear Science Symposium Conference Record* 2004. Piscataway (NJ). Institute of Electrical and Electronics Engineers; New Jersey 2004: 2929-33.

