

The prevalence of a false-positive myocardial perfusion stress SPET test in a skinny patient, induced by projection truncation

To the Editor: During the last decade, technical developments in myocardial perfusion single photon emission tomography (SPET) imaging systems have significantly improved the accuracy of diagnosing coronary artery disease. Nevertheless, the patient's position and/or the acquisition protocol can affect the studies' quality, possibly leading to misdiagnoses [1, 2]. In HJNM and in other journals the importance of proper positioning of the heart of the patient to be examined by myocardial perfusion SPET stress/rest testing, has been emphasized [3, 4]. According to our knowledge, only three cases of truncation artifact during SPET myocardial perfusion imaging acquired with original SPET cameras, related to improper positioning in very thin patients, have been reported. In all cases, patients were examined according to a single day stress/rest technetium-99m-sestamibi protocol, using a dual 90 degree detector system, equipped with high resolution, parallel-hole collimators [3, 5, 6]. However, several published manuscripts have underlined the significance of appropriate patients' positioning in myocardial perfusion scintigraphy using dedicated, cadmium-zinc-telluride (CZT) or small field-of-view cardiac SPET systems [4, 7-10].

A typical case is that of a 47 years old man (height 187cm, weight 67kg), heavy smoker, with atypical chest pain. He exercised very well according to the Bruce protocol, achieving 95% of maximal age-predicted heart-rate and a technetium-^{99m}m-tetrofosmin (^{99m}Tc-TF) myocardial perfusion imaging with 370MBq of ^{99m}Tc-TF followed [11, 12] with a dual head

camera (Infinia GE, USA), equipped with low-energy, high-resolution, parallel-hole collimators at 90° (L-mode configuration). Projection images were obtained from 45° RAO to 45° LPO position, in step and shoot mode (60 projections, 30sec per projection; matrix 64x64 and zoom 1.3). Auto body contour was not used [13, 14]. Unprocessed raw data, showed neither patient motion nor significant extracardiac activity that could result in false positive defects on myocardial perfusion stress images (Figure 1a, b) [15]. However, truncation at the apex of the heart was observed. In detail, truncation of activity of apical portion of the heart from frame 45-60 (detector 1) and frames 1-5 (detector 2) was noticed (indicated by yellow arrows).

Processed stress images demonstrated a severe defect in the apex and the apical part of the anteroseptal wall (Figure 2a). Moreover, less intense defects were observed in the inferior and septal walls. All acquisition parameters were double checked and a possible error regarding the "zoom" was ruled out. Hence, it became evident that the aforementioned artifact has originated from an eccentric patient's position and thus some heart projections were missed.

A second stress acquisition was performed after repositioning the patient with emphasis on positioning of the heart at the center of the field of view as shown in Figure 2b. Figure 2 depicts both the correct and incorrect positioning the heart in regard to the camera detectors. As a result, improvement of the above mentioned defects, mainly in the apex and the apical anteroseptal wall were shown in Figure 2b.

In the literature, a number of recent studies have mentioned the effect of the truncation artifact even with newly equipped gamma cameras, emphasizing the importance of the heart being in the field of view throughout the acquisi-

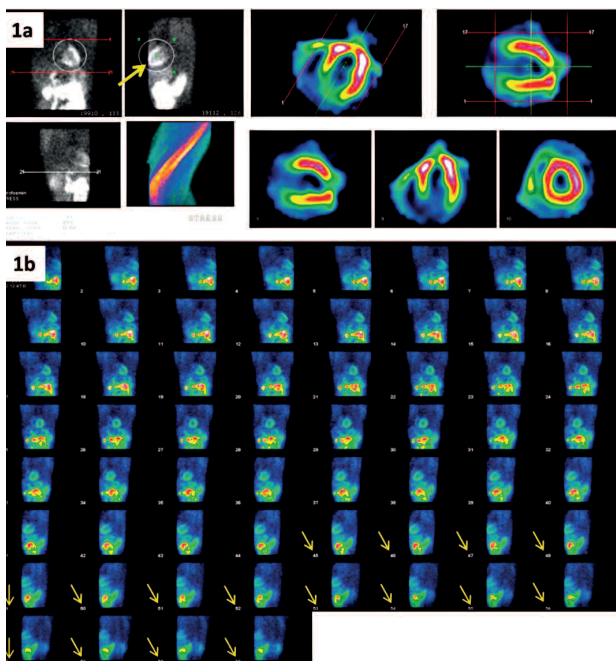


Figure 1. a, b: Cinematic/raw data.

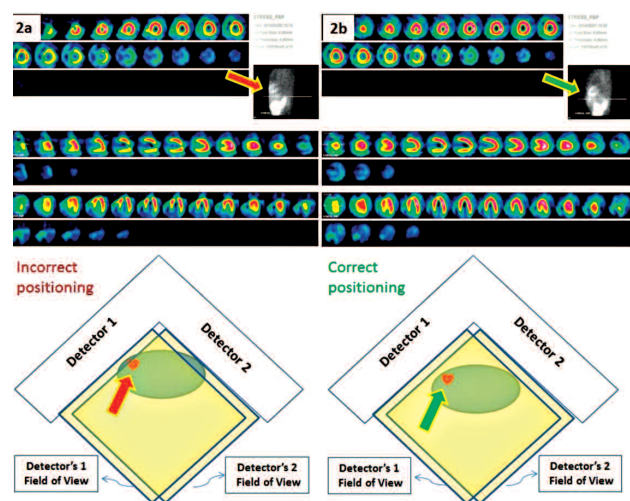


Figure 2. a, b: Patient's positioning-outcome.

Correspondence

tion procedure [4, 7-9]. Few of them used parallel-hole collimation [3, 5, 6].

In conclusion, it is suggested that in cases of very thin patients it is often necessary to avoid truncation artefacts by correctly positioning the patient's heart.

The authors declare that they have no conflicts of interest.

Bibliography

- Burrell St, MacDonald A. Artifacts and Pitfalls in Myocardial Perfusion Imaging. *J Nucl Med Technol* 2006; 34: 193-211.
- Shawgi M, Tonge CM, Lawson RS et al. Attenuation correction of myocardial perfusion SPET in patients of normal body mass index. *Hell J Nucl Med* 2012; 15: 215-9.
- Yapici O, Baris S, Alic T, Basoglu T. Auto-contouring at 90 degrees dual head fitting angle: a potential cause of a myocardial per fusion SPET artifact in slim patients. *Hell J Nucl Med* 2009; 12: 289-90.
- Hinford C, Oddstig J, Hedeer F et al. Importance of correct patient positioning in myocardial perfusion SPECT when using a CZT camera. *J Nucl Cardiol* 2014; 21(4): 695-702.
- Wosnitzer B, Gadiraju R, DePuey G. The truncation artifact. *J Nucl Cardiol* 2011; 18(1): 187-91.
- Wosnitzer B, Friedman M, DePuey G. Truncation in Myocardial Perfusion SPECT Imaging. *Int J Nucl Ener Science and Engineering* 2012; 2: 116-21.
- McGowan SE, Greaves CD, Evans S. An investigation into truncation artefacts experienced in cardiac imaging using a dedicated cardiac SPECT gamma camera with transmission attenuation correction. *Nucl Med Comm* 2012; 33: 1287-91.
- Xiao J, Verzijlbergen JF, Viergever MA et al. Small field-of view dedicated cardiac SPECT systems: impact of projection truncation. *Eur J Nucl Med Mol Imaging* 2010; 37: 528-36.
- Chen J, Galt JR, Case JA et al. Transmission scan truncation with small-field-of-view dedicated cardiac SPECT systems : impact and automated quality control. *J Nucl Cardiol* 2005; 12(5): 567-73.
- Ozulkur T, Ozulkur F, Ozpacaci T. ^{99m}Tc-MDP and ¹⁸F-FDG uptake in calcified metastatic lesions from ovarian papillary serous adeno carcinoma. *Hell J Nucl Med* 2009; 12(3): 287-8.
- Hesse B, Tagil K, Cuocolo A et al. EANM/ESC procedural guidelines for myocardial perfusion imaging in nuclear cardiology. *Eur J Nucl Med Mol Imaging* 2005; 32: 855-97.
- Georgoulas P, Demakopoulos N, Kontos A et al. Tc99m Tetrofosmin Myocardial Perfusion Imaging Before and Six Months After Percutaneous Transluminal Coronary Angioplasty. *Clin Nucl Med* 1998; 23: 678-82.
- Case AJ, Bateman MT. Taking the perfect nuclear image: Quality control, acquisition, and processing techniques for cardiac SPECT, PET, and Hybrid imaging. *J Nucl Cardiol* 2013; 20: 891-907.
- Germano G. Technical Aspects of Myocardial SPECT Imaging. *J Nucl Med* 2001; 42: 1499-507.
- DePuey EG III. How to Detect and Avoid Myocardial Perfusion SPECT Artifacts. *J Nucl Med* 1994; 35: 699-702.

Ioannis Tsougos¹ MSc, PhD, Sotiria Alexiou² MD, Kiki Theodorou¹ MSc, PhD, Varvara Valotassiou² MD, Panagiotis Georgoulas² MD, PhD

1. Department of Medical Physics and 2. Department of Nuclear Medicine, University Hospital of Larissa, Larissa, Greece

Panagiotis Georgoulas, MD, PhD

Assoc. Professor of Nuclear Medicine, Director of the Nuclear Medicine Department. Faculty of Medicine, University of Thessaly, Biopolis, 41110, Larissa, Greece. Tel: 00302413502918, Fax: 00302413501863, E-mail: pgeorgoul@med.uth.gr, georgoulas@hotmail.com

Hell J Nucl Med 2015; 18(1): 79-80

Published online: 31 March 2015

On 16-19 April 2015 in Yokohama, Japan will be held a very important Conference of the Society of Radiology of Japan.

For more information please refer to Professor Tomoaki Yamamoto: tyamamoto@ks.kyorin-u.ac.jp

With thanks of the Editorial Board to all who reviewed papers in 2014 for the Journal

Editors of the Hellenic Journal of Nuclear Medicine are privileged to cooperate with authors and with distinguished reviewers who try to better evaluate the papers submitted for publication.

Authors benefit of the guidance of the reviewers and the Journal is proud to publish important papers. It was unfortunate that few of the papers submitted presented facts with not sufficient statistical support. In case of doubt, we may ask the opinion of a third reviewer. One should not express results as per cent, if these results are fewer than a hundred, all together. Furthermore, high standard deviation of the mean may not be accepted.

We thank the following colleagues for reviewing papers for the Hellenic Journal of Nuclear Medicine during the last year (2014): B. Ajdinovic, K. Aloumanis, D. Apostolopoulos, V. Artiko, K. Badiavas, G. Bandopadyaya, T. Basoglu, S. Bostantzopoulou, D. Boundas, G. Cheng, F. DeGeeter, D. Dhawan, G. Fountos, S. Gaberscek, A. Georgakopoulos, G. Gerasimou, D. Goulis, V. Hatzipavlidou, N. Karatzas, I. Karfis, I. Kotsalou, M. Lyra, G. Mariani, G. Meristoudis, E. Moralidis, B. Palumbo, E. Papanastasiou, N. Pianou, N. Pontikidis, G. Psillas, H. Raihan, G. Rubini, N. Shantly, B. Singh, H. Sinzinger, E. Skoura, T. Spyridonidis, C. Tsopelas, P. Valsamaki, T. Yamamoto, A. Zafirakis and A. Zissimopoulos.

Prof. emer. Ph. Grammaticos, Editor-in-Chief



ΚΑΤΑΧΩΡΗΣΗ ΜΕ ΥΠΕΡΗΧΟΥΣ

