

Serial changes of ^{18}F -FDG PET/CT findings in ischiopubic synchondrosis: comparison with contrast-enhanced MRI

Kazunobu Tsuji¹ MD,
Tatsuro Tsuchida¹ MD,
Nobuyuki Kosaka¹ MD,
Akihiko Tanizawa² MD,
Hirohiko Kimura¹ MD

1. Department of Radiology and
2. Department of Pediatrics,
Faculty of Medicine, University
of Fukui, Fukui, Japan

Keywords: Ischiopubic synchondrosis
- ^{18}F -FDG PET - MRI
- Physiological uptake

Correspondence address:

Kazunobu Tsuji MD
23-3 Matsuoka-shimoaizuki,
Eiheiji-cho, Yoshida-gun,
Fukui 910-1193, Japan
Tel: 81-776-61-3111
(ext.2335)
Fax: 81-776-61-8137
kazunobu@u-fukui.ac.jp

Received:

21 November 2014

Accepted revised:

18 December 2014

Abstract

A 3 years old female patient underwent resection and chemotherapy for a yolk sac tumor of the retroperitoneum. Two years later, fluorine-18 fluorodeoxyglucose positron emission tomography/computed tomography (^{18}F -FDG PET/CT) showed high uptake in the right ischiopubic synchondrosis (IPS), which had a radiolucent structure on CT. The structure showed contrast enhancement on magnetic resonance imaging (MRI), which was a non-specific finding. Six weeks later, a follow-up ^{18}F -FDG PET/CT scan was performed which showed no abnormal uptake in the IPS. The disappearance of ^{18}F -FDG uptake preceded that of contrast enhancement on MRI, which was seen 7 months after the initial ^{18}F -FDG PET/CT scan. **Conclusion:** This is the first report showing serial changes of ^{18}F -FDG uptake in IPS, in comparison to MRI findings.

Hell J Nucl Med 2015; 18(1): 66-67

Epub ahead of print: 13 February 2015

Published online: 31 March 2015

Introduction

The ischiopubic synchondrosis (IPS) is a temporary event, occurring in all children before puberty during fusion of the ischial and pubic bones [1]. The IPS, which is considered a normal variant, can frequently be seen in conventional radiographs, as a tumor-like fusiform radiolucent area at the ischiopubic fusion zone [1]. Usually IPS without a history of trauma or positive laboratory findings does not need further investigation [2]. Differential diagnosis includes bone metastasis in patients having a malignant tumor. Other researchers reported that two-thirds of IPS had on MRI a hypointense band-like structure perpendicular to the pubic axis [3], which they called "fibrous bridging". According to these authors, fibrous bridging seems to be the only specific imaging finding and absence of this finding does not exclude metastasis. Then a follow-up or a biopsy is indicated [3]. There are few reports on ^{18}F -FDG PET in IPS [4], but the serial changes of ^{18}F -FDG uptake in IPS in comparison to MRI findings have never been reported. To the best of our knowledge, this is the first report to confirm the disappearance of abnormal uptake of ^{18}F -FDG in IPS as shown on the follow-up ^{18}F -FDG PET scan earlier than on the MRI examination. Thus, ^{18}F -FDG PET follow-up may contribute earlier than MRI to rapid diagnosis.

Case report and Discussion

A 3 years old female patient with a yolk sac tumor of the retroperitoneum and multiple lung metastases underwent multimodal treatment including resection of the primary tumor and chemotherapy. After treatment, the lung metastases disappeared, and she was free of local recurrence. Two years later, she underwent ^{18}F -FDG PET/CT examination for a follow-up study which showed increased uptake in the right inferior ischial ramus (Figure 1a, 1c), with a radiolucent structure on CT (Figure 1b). On hematological and biochemical testing, leukocytes were slightly increased: 11400/ μL , C-reactive protein (CRP), 0.06mg/dL, α -fetoprotein (AFP), 3.2ng/mL, Hb and Ht were normal. On the initial MRI scan, isointensity was shown as compared with the normal bone marrow of the right inferior ischial ramus, both on T1- and T2-weighted images. After gadopente-

Original Case Report

tate dimeglumine infusion, the above structure showed contrast enhancement (Figure 1d). The band-like structure that is thought to be specific to IPS could not be detected, and, therefore, short-term follow-up without any treatment was decided. A follow-up ^{18}F -FDG PET/CT performed six weeks after the initial ^{18}F -FDG PET/CT showed a normal uptake in the ischial ramus area (Figure 2c), although the radiolucent area was still present. On the second MRI performed six weeks after the follow-up ^{18}F -FDG PET/CT scan, the ischial ramus showed weaker enhancement (Figure 2d), and, finally, the contrast enhancement disappeared on the MRI performed four months after the second MRI (Figure 2e).

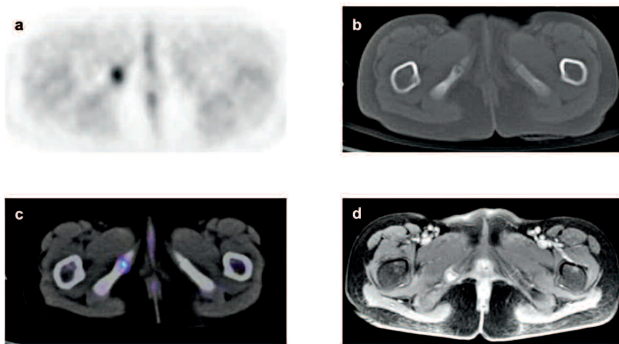


Figure 1. ^{18}F -FDG PET image shows focal uptake (a), which corresponds to the radiolucent structure in the right inferior ischial ramus on CT (b). ^{18}F -FDG PET/CT fusion image (c) confirms the findings shown above. MRI (d) shows contrast enhancement of the structure.

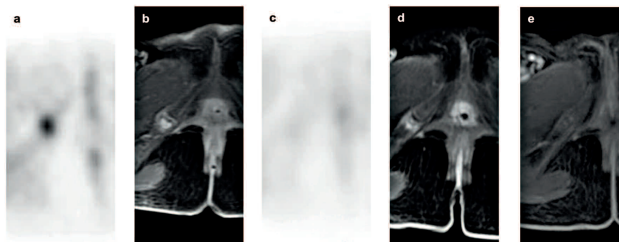


Figure 2. Time course of the changes of ^{18}F -FDG PET and contrast-enhanced MRI findings. Initial ^{18}F -FDG PET (a) shows high ^{18}F -FDG uptake on the right IPS. MRI, 4 days after the initial ^{18}F -FDG PET (b) shows the same with contrast enhancement. ^{18}F -FDG uptake in the IPS has disappeared on follow-up ^{18}F -FDG PET, 6 weeks after the initial ^{18}F -FDG PET (c). However, weaker contrast enhancement still remains on the follow-up MRI 4 months after the initial ^{18}F -FDG PET (d). Seven months after the initial ^{18}F -FDG PET, contrast enhancement in MRI has finally disappeared (e).

In 1924, van Neck found several cases of enlargement of the IPS and named this evidently new pathology “osteochondritis ischiopubica”. Later, because of its apparent benign and spontaneous evolution, other names were used, such as “osteochondrosis” or “osteochondropathia,” until the present name of IPS came into use [5]. Asymmetrical enlargement of the IPS is a physiologic phenomenon related to asymmetrical mechanical stress of the adductors, iliopsoas, and gemellus muscles over each hemipelvis. This causes constant movement of the IPS, with an inflammatory reaction and delayed union of the cartilage layers and ossification centers [5]. In general, the fusion of the ischial and

the pubic bones causes no symptoms, but in some children it is accompanied by pain in the groin and restriction in the movement of the hip joint [5]. Histological studies of the enlarged IPS before fusion reveal cells with strong staining with hematoxylin and eosin. This pattern is typical of joint or joint-like structures subjected to mechanical stress [3]. IPS is seen as a radiolucent fusiform swelling on conventional radiographs and CT [1, 5]. Bone scintigraphy shows increased radiotracer uptake at the site [5]. These findings can resemble neoplasia and also post-traumatic osteolysis, osteomyelitis, or stress fracture, leading to problems with differential diagnosis. Besides the specific findings in MRI of fibrous bridging, other findings as fusiform swelling on T1-weighted sequences and hyperintense signal alteration of the adjacent soft tissues on T2-weighted sequences, as well as irregular margins are suggestive of hyperemia and edema and can correspond to mechanical stress on these temporary joints. To the best of our knowledge, there is only one case report of ^{18}F -FDG PET/CT that showed high uptake in IPS [4]. The serial changes of ^{18}F -FDG uptake and the degree of contrast enhancement with MRI in IPS have not been reported. In the present case, disappearance of uptake on ^{18}F -FDG PET preceded the disappearance of contrast enhancement on MRI. This result suggests that changes in glucose metabolism are more sensitive than signal alterations on MRI. Diagnostic difficulties associated with distinguishing between physiologic IPS and metastasis are expected to become more frequent in the future. The specific finding of IPS on MRI, which cannot be detected in 1/3 of these cases, could be detected and followed-up by ^{18}F -FDG PET, thus, contributing to rapid diagnosis.

In conclusion, we present a case of IPS studied by ^{18}F -FDG PET and MRI. Disappearance of uptake on ^{18}F -FDG PET preceded the disappearance of contrast enhancement on MRI. This result suggests that glucose metabolism changes seen on ^{18}F -FDG PET are more sensitive and precede the signal alterations on MRI.

Acknowledgement

We thank Dr. Takahiro Oshikiri, Department of Pediatric Surgery, Kanazawa Medical University for providing part of the radiographic images.

The authors declare that they have no conflicts of interest.

Bibliography

1. Caffey J, Ross SE. The ischiopubic synchondrosis in healthy children: some normal roentgenologic findings. *Am J Roentgenol Radium Ther Nucl Med* 1956; 76: 488-94.
2. Herring JA, Tachdjian MO, Texas Scottish Rite Hospital for C. *Tachdjian's pediatric orthopaedics*. 4th edn. Saunders/Elsevier, Philadelphia 2008: 169.
3. Herneth AM, Trattnig S, Bader TR et al. MR imaging of the ischiopubic synchondrosis. *Magn Reson Imaging* 2000; 18: 519-24.
4. Drubach LA, Voss SD, Kourmouzi V, Connolly LP. The ischiopubic synchondrosis: changing appearance on PET/CT as a mimic of disease. *Clin Nucl Med* 2006; 31: 414-7.
5. Oliveira F. Differential diagnosis in painful ischiopubic synchondrosis (IPS): a case report. *Iowa Orthop J* 2010; 30: 195-200.