

Preparation of ^{99m}Tc labeled 5-fluorouracil as a potential diagnostic agent in advanced breast cancer: First clinical trial

Ume Kalsoom Dar^{1,2} BS,
Irfan Ullah Khan¹ PhD,
Muhammad Javed³ MSc,
Rashid Rasheed³ MSc,
Zaid Mahmoud² PhD,
Syed Waqar Hyder¹ MSc,
Sohail Murad Bhatti³ DMRT,
Jamil Anwar² PhD

1. Radiopharmacy Division,
Institute of Nuclear Medicine and
Oncology (INMOL), New Campus
Road, P. O. Box 10068, Lahore-
54600, Pakistan
2. Institute of Chemistry, University
of the Punjab, Quaid-e-Azam
Campus, Lahore-54590, Pakistan
3. Gujranwala Institute of Nuclear
Medicine (GINUM), Gujranwala,
Pakistan

Keywords: 5-fluorouracil
- Radiolabeling - Clinical trial
- Breast cancer

Correspondence address:

Dr. Irfan Ullah Khan MD, PhD,
Pr. Scientist Institute of Nuclear
Medicine and Oncology (INMOL)
New Campus Road, PO Box
10068, Lahore- 54600, Pakistan
Cell: +923224110569
Email: drirfankhan69@gmail.com

Received Revised:

3 January 2012

Accepted:

15 February 2012

Abstract

The chemotherapeutic drug 5-fluorouracil (5FU) is used for treatment of various types of cancers. *The present study was conducted* to evaluate the potential of this drug as a diagnostic radiopharmaceutical in advanced breast cancer. We have labeled 5FU by using the stannous chloride reduction method with 555MBq of technetium-99m (^{99m}Tc). The ^{99m}Tc -5FU was injected intravenously in 4 patients having advanced breast cancer. Dynamic and static images were taken at various time intervals till 2h. Whole body images were used to calculate the percentage of the injected dose, in each organ. Target to non target ratio was calculated to find out the optimum time for imaging. *In conclusion*, our study showed that ^{99m}Tc -5FU was a promising agent for diagnosing advanced breast cancer with optimum visualization at 1h.

Hell J Nucl Med 2012; 15(1): 43-47

Published on line: 9 March 2012

Introduction

Cancer causes abnormal growth of cells by multiple changes in gene expression leading to deregulated balance of cell proliferation, cell death and ultimately evolving into a population of cells that can invade tissues and metastasize to distant sites, causing significant morbidity and, if untreated, death of the host [1]. The drug 5-fluorouracil (5FU) is a chemotherapeutic agent for pancreatic, stomach, breast, bowel and oesophagus cancer [2]. In 1957, Heidelberger et al. [3] synthesized 5FU as an antimetabolite agent. The replacement of hydrogen atom at position 5 of uracil molecule by fluorine forms the 5FU. The molecule blocks the metabolism of malignant cells by occupying the active site of enzyme targets.

Although, 5-FU is toxic by nature, it is effective as an antimetabolite treatment agent against solid tumors [4-8]. The ideal radiopharmaceutical should convey its radioactive nuclide, quantitatively, to the tumor tissue, but not to normal tissues [9]. This drug is involved in the metabolic activation of RNA to 5-fluoro-2'-deoxyuridine-5-monophosphate principally and inhibits the enzymatic activity of thymidylate synthetase that is an important enzyme for DNA synthesis [10]. Thymidylate synthase methylates deoxyuridine monophosphate (dUMP) into thymidine monophosphate (dTMP). Thus, administration of 5FU blocks the synthesis of pyrimidine thymidine, a nucleoside required for DNA replication and inhibits RNA replication enzymes as well, thereby eliminating RNA synthesis. It is also transformed into various types of cytotoxic metabolites inside the cell which are then incorporated into RNA and DNA and induce cell cycle arrest and apoptosis by inhibiting the cell's ability for synthesizing DNA. Exosome complex activity which is essential for cell survival is stopped [11]. Through blood supply, 5FU penetrates the extra vascular space to cause lethal toxicity. Drug distribution of 5FU in tumors is influenced by the metabolic properties of the drug, the rate of diffusion through tissues, tissue binding and mitotic activity of the tumor cells. Due to the higher mitotic activity of the tumor cells versus the inflammatory cells, 5FU can show tumors much better than inflammation [12-14]. In 2008, 5FU was radiolabeled with technetium-99m (^{99m}Tc) and its biodistribution was studied in animals. The authors have previously studied ^{99m}Tc -5FU as a selective agent towards solid tumors [15]. On the basis of these findings, we present this study, which is the first clinical trial of ^{99m}Tc -5FU application to diagnose advanced breast cancer patients.

Patients and methods

All chemicals used for this research were analytically derived from the following sources: 5-fluorouracil, stannous chloride and L-cysteine hydrochloride monohydrate were pur-

chased from Aldrich, USA. Technetium-99m generator was purchased from Pakistan Institute of Nuclear Science and Technology (PINSTECH), Pakistan and saline from Ostuka, Pakistan.

Radiopharmaceutical kit formulation of the compound

Ten mg of 5FU were dissolved in 10mL of distilled water with continuous stirring. Five mg of L-cysteine hydrochloride monohydrate were then added. Afterwards, 2mg SnCl₂·2H₂O were added and pH was maintained at pH 7 by using 5N NaOH, 1N NaOH and 0.1N NaOH. The resultant solution was passed through a 0.22µm membrane filter. One mL/ kit of resultant solution was dispensed in sterilized serum vials.

Radiolabeling and quality control

Three hundred and seventy MBq/0.5mL of Na^{99m}TcO₄ were eluted from ⁹⁹Mo-^{99m}Tc generator, added to the kit and incubated at room temperature for 15min. Radiochemical purity of the complex was determined by chromatographic techniques. Radiochemical purity of the ^{99m}Tc-5FU was studied by using two simple chromatographic techniques, e.g., instant thin layer chromatography (ITLC) and paper chromatography (PC) with 3MM Whatman paper, and these were employed to find out the percentage of hydrolyzed, (radionuclide bound to ligand) and of free pertechnetate. Acetone was used as a mobile phase for paper chromatography and saline was used for ITLC. Small aliquots from the reconstituted kit were spotted on the respective strips. The strips, after elution, were cut in fractions of 1cm and counted for radioactivity in a well type scintillation gamma counter (Scaler Timer-ST7, Thorn EMI-Nuclear Enterprises, United Kingdom). The entire vial content was taken into a 3mL syringe and injected intravenously (i.v.) to the patient.

Safety of ^{99m}Tc-5FU

The pharmaceutical kit was synthesized under sterilized conditions. Laminar flow hood was sterilized with spirit under UV light exposure for 24h. Apparatus used for the kit formulation was sterilized in a preheated oven at 200°C for 2h. Before applying the drug to the patients, the drug was tested in animal models. There were no signs of toxicity in animals till 72h of post injection (p.i.). The dose-related toxicity was investigated in a group of five rabbits for three consecutive days by injecting 100µg/kg of ^{99m}Tc complex. No signs of tox-

icity were observed till 72h after the last i.v. injection. The animal toxicity study was performed in accordance with the current rules of Institute of Nuclear Medicine and Oncology (INMOL) Hospital, Lahore, Pakistan.

Patient selection

Four female patients with advanced breast cancer were selected for this study. The mean age of the patients was 31 years ranging from 24 years to 36 years. The selected patients were already receiving chemotherapeutic or radiotherapeutic treatments. None of the patients had history of allergy. Each patient gave her written consent after being fully informed about the procedure and about ^{99m}Tc-5FU. Patients' history is shown in Table 1.

Study protocol

Before starting imaging studies, routine pathology lab tests of all patients like complete blood count, liver function tests, urea, and creatinine were determined. Besides these clinical laboratory investigations, the blood pressure and blood sugar level of all patients were also monitored. Urine samples were collected for routine chemical and microscopic examination. All these investigations were considered as baseline. A dose of 555MBq of ^{99m}Tc-5FU was given i.v. in 30sec to acquire dynamic images of both breasts including axilla. During the study, vital signs of the patients were monitored for any significant change from baseline. Scintigraphic results were co-evaluated with ultrasonography (USG) of the breasts (data from USG are not shown). Diagnosis was verified by biopsy of the cancerous specimen.

Imaging protocol

The dynamic acquisition comprised of 10 frames of 60sec each. Anterior and posterior whole body images were acquired at 0, 60, and 120min, post injection (p.i.). Images were recorded by using a large field of view (LFOV) dual head gamma camera (Infinia II with Hawkeye option, GE, USA) equipped with a low-energy, all-purpose collimator for acquisition. Data processing was done on the ICON8.5 Macintosh System (USA) interfaced with the camera.

Pharmacokinetics and biodistribution

Imaging studies were performed with the 4 patients. To obtain clear visualization of the tumor, images were acquired in various positions, e.g., anterior, posterior, left lateral,

Table 1. Patient history

Patient ID	History
Patient 1	34 years old with right breast CA, on neo adjuvant chemotherapy, stage IV (tumor extends more than 2cm into liver, and/or into 2 or more adjacent organs). (Here, stage IV, means tumor invasion to adjacent organs). No distant metastasis was observed and the patient showed mild response to FAC: 5FU, adriamycin (doxorubicin) and cyclophosphamide.
Patient 2	36 years old with left breast CA, stage IV with osseous and lung metastases. Patient was receiving palliative treatment of chemotherapy.
Patient 3	29 years old with right breast CA, stage IV with metastases in the left breast and the scalp. The patient had received complete TAC: taxotere (docetaxel), adriamycin (doxorubicin), and cyclophosphamide chemotherapy treatment X 6 and RT X 21 (radiation therapy) in 2004. Presently, the patient was on palliative chemotherapy.
Patient 4	36 years old with left breast CA, stage IV- Invasive ductal carcinoma of 3cm and distant metastases. After four cycles of neo adjuvant chemotherapy, breast lump and axillary nodes regressed significantly.

right lateral and whole-body. A region of interest (ROI) was drawn on the whole body anterior and posterior views, and counts calculated by the geometric mean were considered as percentage of the injected dose at that particular time. Regions of interest were also drawn around other important organs like tumor, kidney, heart and bladder. The background regions were placed close to the ROI for background correction. Scans were analyzed semiquantitatively by calculating the injected dose per organ at 0h, 1h and 2h. Target to nontarget ratios (T/NT) of images were also calculated at 0h, 1h and 2h. Percentage injected dose (PID) at these time intervals was calculated using the following formula:

$$PID = 100 \times (\text{organ counts at particular time}) / (\text{total-body counts at that time})$$

Semi-quantitative analysis

Scans with positive findings were analyzed semi-quantitatively by calculating T/NT for the 0-, 1h- and 2h images (Fig. 1). Tight placement of the ROI around the area of increased accumulation of the tracer (target) was followed by mirroring of the ROI over the contralateral site (nontarget).

Statistical analysis

Patients were only 4, thus no statistical results, such as sensitivity, specificity and accuracy could be determined. Nevertheless, correlation with the diagnostic results from radiology and pathology were of some value.

Results

Safety in human

All patients remained well with no adverse reactions after the i.v. injection of ^{99m}Tc-5FU. Patients' vital signs, like blood pressure, heart and respiratory rate and body temperature were examined before and at 4h post injection of ^{99m}Tc-5FU. White and red blood cells counts and other laboratory tests as mentioned before were also performed after the scanning procedure. All tests, both clinical and laboratory investigations, after the ^{99m}Tc-5FU matched well with the baseline tests data.

Quality control tests

During labeling of 5FU with ^{99m}Tc- besides the bound ^{99m}Tc to 5FU complex, free pertechnetate (^{99m}TcO₄⁻) and reduced or hydrolyzed ^{99m}TcO₂ were also formed as separated by PC and ITLC. In PC, ^{99m}TcO₄⁻ had an Rf of 0.8-0.9, while the ^{99m}Tc-5FU and the reduced or hydrolyzed ^{99m}TcO₂ appeared at Rf=0.00-0.01. The reduced or hydrolyzed fraction was separated from the other two fractions by using saline, in which case the ^{99m}Tc-5FU complex and the free ^{99m}TcO₄⁻ appeared at Rf=0.9-1.0, and the ^{99m}TcO₂ was detected at Rf=0.00-0.01. The overall labeling yield of the ^{99m}Tc-5FU complex as calculated by these methods, was more than 98.1±1.2%.

Imaging and pharmacokinetics

The ^{99m}Tc-5FU was injected to the patients, lying under the single photon emission tomography (SPET) gamma camera

Table 2. Biodistribution data of ^{99m}Tc-5fluorouracil in the 4 breast cancer patients, expressed as percentage of the injected dose

Patient	%ID Tumor			%ID Right kidney			%ID Left kidney			%ID Heart			%ID Bladder		
	0h	1h	2h	0h	1h	2h	0h	1h	2h	0h	1h	2h	0h	1h	2h
1	8.57	8.30	7.03	2.85	4.86	4.65	2.79	3.30	4.04	2.75	2.24	1.40	6.68	13.4	20.2
2	2.86	2.72	1.63	3.01	3.48	6.3	3.03	3.23	6.37	2.60	2.24	1.80	10.7	14.8	9.5
3	3.80	3.50	2.58	3.01	3.43	5.34	3.03	4.86	4.42	3.97	3.53	3.38	10.7	12.1	20.6
4	1.84	1.44	1.32	2.35	2.80	5.34	2.23	2.72	4.42	2.82	2.17	3.38	6.52	11.9	20.6
Mean	5.01	4.74	3.80	2.88	3.88	5.57	2.86	3.76	5.07	3.19	2.71	2.66	9.29	13.4	19.1
±SD	±	±	±	±	±	±	±	±	±	±	±	±	±	±	±
	2.97	2.99	2.64	0.31	0.90	0.67	0.37	0.92	1.05	0.63	0.65	0.94	2.4	1.31	5.5

ID: injected dose

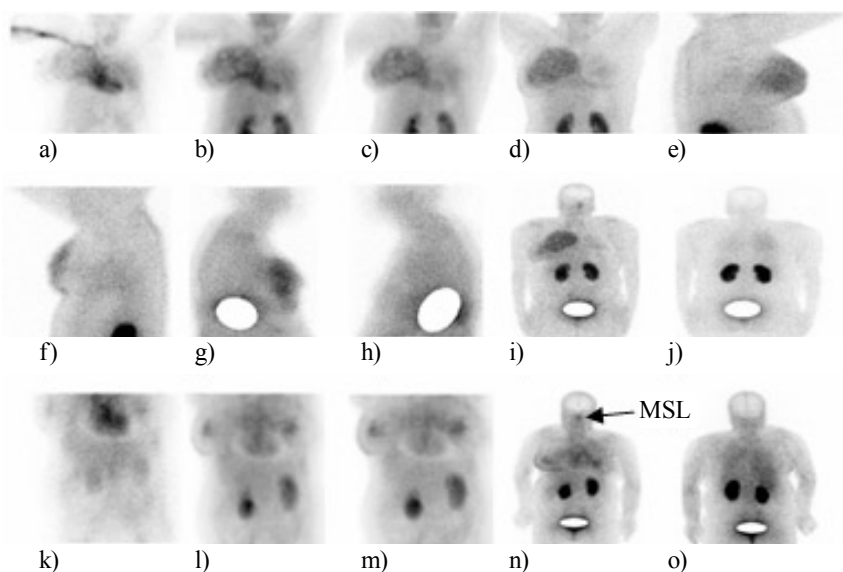


Figure 1. Biodistribution of ^{99m}Tc-5FU in patient 1, where a), b) and c) dynamic images were taken at 1min, 10min and 15min p.i., d), e) and f) show the static views at 1h p.i., in anterior, right and left lateral views, g) and h) show static views at 2h p.i., in the right and left lateral views and i) and j) show whole-body scans at 1h p.i., in the anterior and posterior views, respectively. Images (k-o) are from patient 3, in which images (k, l, m) present the dynamic study at 1min, 10min and 15min, and (n, o) the whole body scans at 1h p.i., in anterior and posterior posture views, respectively. In patient 3, the metastatic scalp lesion (MSL) is also visible in image (n), which is an anterior posture from a whole body view.

(Infinia II with Hawkeye option, GE, USA) to study the flow of the drug. Dynamic and delayed images taken at various time intervals are shown in Fig. 1.

The biodistribution was calculated by using whole body images. Percentage of the injected dose in each organ is given in Table 2 and Figure 2.

The above data show that uptake of ^{99m}Tc-5FU in the primary tumor was maximum at 0h, i.e., 5.01±2.97% and gradually decreased at 1h (4.74±2.99%) and 2h (3.80±2.64%) similar was the heart uptake. The opposite pattern of uptake was observed in all other organs studied (Table 2 and Fig. 2). An excretion of the radiolabeled drug through kidneys and bladder was noticed. Due to logistic reasons, the study did not include the 10min interval as the patients' turnover was high at that time.

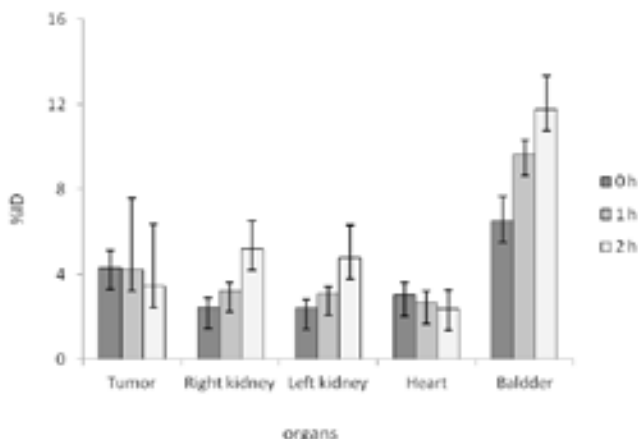


Figure 2. Scintigraphic biodistribution of ^{99m}Tc-5FU. The values of percentage of the injected dose (% ID) for organs of interest are mean of the 4 patients' data, taking whole body counts as 100% of the injected dose at each interval.

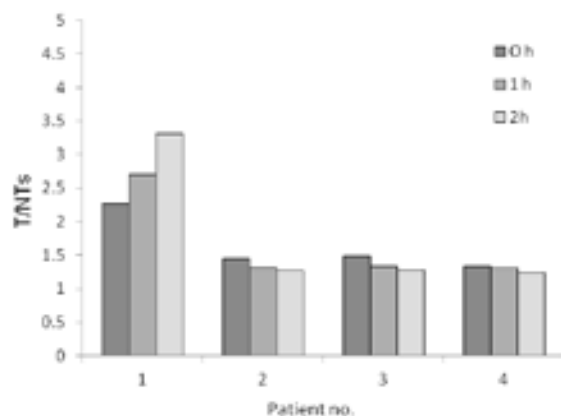


Figure 3. T/NT at 0h, 1h and 2h in 4 patients using uptake from tumor as targeted data while uptake in the rest of the organs as nontargeted uptake.

Table 3. Tumor to not tumor uptake at 0h, 1h and 2h

Patient	T/NT		
	0h	1h	2h
1	2.26	2.71	3.01
2	1.74	1.62	1.27
3	1.48	1.34	1.28
4	1.33	1.30	1.24
Mean±SD	1.71±0.40	1.74±0.66	1.7±0.87

Target to nontarget ratios were calculated to evaluate the optimum visualization time of the image. The counts in T/NT tissues of the 4 patients were used for studying the

T/NT ratio. These data indicated that T/NT ratio was maximum at 1h, i.e., 1.74±0.66%. T/NT at 0h was 1.71±0.41% and 1.70±0.87% at 2h. These data are given in Table 3 and Figure 3, respectively.

Discussion

Our study provides the first clinical evidence for ^{99m}Tc-5FU as a possible cancer imaging agent in advanced breast carcinoma. We have modified the radiolabeling procedure, previously reported by others in animal models [15], by using 1mg 5FU/kit, rather than 2mg/kit. Secondly, the previous study [15], used 75mg/kit of SnCl₂·2H₂O, for reducing ^{99m}Tc, while we have decreased this amount to only 0.2mg/kit. The safety experiments were performed by using 370MBq of Na^{99m}TcO₄ for radiolabeling of 5FU. The quality control of ^{99m}Tc-5FU, which was performed by using paper and instant thin layer chromatography, showed that 98±1% of the drug was radiolabeled. The scintigraphic procedure was used to evaluate biodistribution and biokinetics of the radiopharmaceutical. For this purpose, 555MBq of ^{99m}Tc-5FU was injected i.v., to the patient.

Safety clinical trial tests are essential for any drug before it is widely used. These tests include preparation of drug under sterile conditions and applying it to an animal for a study lasting for 72h. After applying the above we proceeded to the present study. All animal and human studies were performed at the INMOL, Lahore, Pakistan, according to the local rules and regulations of the country (INMOL 53/07). Human studies were performed by their informed written consent about the new drug and the whole procedure. Earlier studies with ¹⁸F-5FU showed 'entrapment' inside the tumor cell [16-18]. Our ^{99m}Tc-5FU also showed maximum tumor uptake immediately after injection which decreased with time as other studies have shown in animals [19] and in colorectal carcinoma patients using PET [20].

The optimum time for imaging was 1h. Others [12] showed in animals a high T/NT ratio of 2h.

Previous studies showed that 5FU is more specific to solid tumors rather than inflammatory lesions [12]. We observed very high target to background ratios in ^{99m}Tc-5FU scans with negligible activity in the liver and heart. These findings support the fact that ^{99m}Tc-5FU is a tumor specific agent that can safely be used for diagnostic imaging, and possibly for treatment follow-up. However, since our preliminary study included only 4 patients, further investigations are necessary to introduce the use of ^{99m}Tc-5FU in routine clinical practice, to determine tumor chemosensitivity and to compare the present technique with other similar breast imaging techniques.

In conclusion, the above data indicated that ^{99m}Tc-5FU had a sufficient uptake in tumoral cells of patients with advanced breast cancer with very low uptake in normal tissues, and had the potential to be used as an imaging agent for breast carcinoma. Furthermore, this technique was easy to perform.

Acknowledgements

This research work was carried out and financially supported by the Institute of Nuclear Medicine and Oncology (INMOL), Lahore, Pakistan. The authors acknowledge the services of Mr. K. Mahmood, Sr. Technologist, INMOL, for performing the imaging studies.

The authors declare that they have no conflicts of interest.

Bibliography

1. Ruddon RW. Cancer biology, 4th edition, *Characteristics of human cancer*. Oxford University Press; p 4.
2. Gunnar B, Mat EB, Uwe H et al. Assessment of the biodistribution and metabolism of 5-fluorouracil as monitored by ¹⁸F PET and ¹⁹F MRI: A comparative animal study. *Nucl Med & Biol* 1996; 23: 897-906.
3. Heidelberger C, Chaudhuri NK, Danneberg PB et al. Fluorinated pyrimidines, a new class of tumor-inhibitory compounds. *Nature* 1957; 179: 663-6.
4. Heidelberger C, Danenberg PV, Moran RG. Fluorinated pyrimidines and their nucleosides. In: Meister A, Ed. *Advances in Enzymology and Related Areas of Molecular Biology*. New York: John Wiley & Sons, 1983; 57-121.
5. Grem JL. 5-fluorouracil: forty-plus and still ticking. A review of its preclinical and clinical development. *Invest New Drugs* 2000; 18: 299-313.
6. Daher GC, Harris BE, Diasio RB. Metabolism of pyrimidine analogs and their nucleosides. *Pharmacol Ther* 1990; 48: 189-222.
7. Parker WB, Cheng YC. Metabolism and mechanism of action of 5-fluorouracil. *Pharmacol Ther* 1990; 48: 381-95.
8. Weckbecker G. Biochemical pharmacology and analysis of fluoropyrimidines alone and in combination with modulators. *Pharmacol Ther* 1991; 50: 367-424.
9. Misara H, Muhammad AK, Roudayna D, Hatem F. Radionuclides delivery systems for nuclear imaging and radiotherapy of cancer. *Advanced Drug Delivery Reviews* 2008; 60: 1329-46.
10. Heidelberger C. On the rational development of a new drug: The example of the fluorinated pyrimidines. *Cancer Treat Rep* 1981; 65: 3-9.
11. Jain RK. Delivery of molecular and cellular medicine to solid tumors. *Microcirculation* 1997; 1: 1-23.
12. F-18 labeled 5-fluorouracil is a useful radiotracer for differentiation of malignant tumors from inflammatory lesions: *Ann Nucl Med* 2008; 22: 65-72.
13. Jain RK. Vascular and interstitial barriers to delivery of therapeutic agents in tumors. *Cancer Metastasis Rev* 1990; 9: 253-66.
14. Wilson WR, Hicks KO. Measurement of extravascular drug diffusion in multicellular layers. *Br J Cancer* 1999; 79: 1623-26.
15. Santosh K, Anil KM, Bhupender S et al. Preparation and pharmacological evaluation of a new radiopharmaceutical, technetium-99m-5-fluorouracil, for tumor scintigraphy. *Hell J Nucl Med* 2008; 11: 91-5.
16. Brix G, Bellemann ME, Ghalch L et al. Direct detection of intratumoral 5-fluorouracil trapping using metabolic ¹⁹F-MR imaging. *Magn Reson Imaging* 1999; 1: 151-5.
17. Abe Y, Fukuda H, Ishiwata K et al. Studies on ¹⁸F-labeled pyrimidines. Tumor uptake of ¹⁸F-5-fluorouracil, ¹⁸F-5-fluorouridine, and ¹⁸F-5-fluorodeoxyuridine in animals. *Eur J Nucl Med* 1983; 6: 258-61.
18. Aboagye EO, Saleem A, Cunningham VJ et al. Extraction of 5-fluorouracil by tumor and liver: a noninvasive positron emission tomography study of patients with gastrointestinal cancer. *Cancer Res* 2001; 61: 4937-41.
19. Visser GW, van der Wilt CL, Wedzinga R et al. ¹⁸F-radiopharmacokinetics of [¹⁸F]-5-fluorouracil in a mouse bearing two colon tumors with different 5-fluorouracil sensitivity: a study for a correlation with oncological results. *Nucl Med Biol* 1996; 23: 333-42.
20. Markus M, Antonia D, Frank G et al. ¹⁸F-labeled fluorouracil Positron Emission Tomography and the prognoses of colorectal carcinoma patients with metastases to the liver treated with 5-fluorouracil. *Cancer* 1998; 83: 245-53.

