

Role of ^{18}F -fluorodeoxyglucose positron emission tomography imaging in the management of primary cutaneous lymphomas

Natalie Spaccarelli¹ MD,
 Mohammad Gharavi² MD,
 Babak Saboury² MD MPH,
 Gang Cheng³ MD, PhD,
 Alain H. Rook⁴ MD,
 Abass Alavi^{1,2} MD, MD (Hon),
 PhD (Hon), DSc (Hon)

1. Perelman School of Medicine,
 University of Pennsylvania,
 Philadelphia, PA, USA

2. Department of Radiology,
 Hospital of the University
 of Pennsylvania, Philadelphia,
 PA, USA

3. Philadelphia Veteran Affairs
 Medical Center, Philadelphia,
 PA, USA

4. Department of Dermatology,
 Hospital of the University
 of Pennsylvania, Philadelphia,
 PA, USA

Keywords: Lymphoma
 - Skin cancer - ^{18}F -FDG-PET
 - Staging lymphoma
 - Lymphoma response to therapy
 - Recurrence

Correspondence address:

Abass Alavi MD, MD (Hon),
 PhD (Hon), DSc (Hon)
 Hospital of the University
 of Pennsylvania,
 3400 Spruce Street 4283,
 Philadelphia, Pennsylvania,
 19104, USA.

E-mail:
 abass.alavi@uphs.upenn.edu.
 Telephone: 215-662-3069
 Fax: 215-349-5843

Received:
 2 June 2014
 Accepted:
 10 June 2014

This article is dedicated to Professor Alavi for his sustained and relentless efforts for promoting molecular imaging with PET as a potent and essential component of modern medicine. His leadership in research and clinical applications of PET is truly commendable and reflects his sincere dedication to this discipline. Throughout his career as an innovator and creative PET researcher, he has been able to demonstrate the critical role of this approach in minimizing human suffering worldwide.

Abstract

Primary cutaneous lymphomas (PCLs) include both cutaneous T-cell and B-cell lymphomas and comprise the second most common type of extra-nodal non-Hodgkin's lymphomas. The treatment and prognosis of PCLs typically depend on the extent of disease. In evaluating extent of disease in oncological processes, computed tomography (CT) provides a purely anatomical assessment of disease. In comparison, [^{18}F]-fluorodeoxyglucose positron emission tomography (^{18}F -FDG PET) both visualizes and quantifies the biological processes occurring in the disease at the cellular level. This paper reviews the available literature addressing the clinical role of ^{18}F -FDG PET both alone and in combination with CT in PCLs and draws several conclusions. While ^{18}F -FDG PET seems superior to CT in its detection of nodal and cutaneous PCL lesions, ^{18}F -FDG PET does not seem to adequately detect erythroderma, plaque, or patch cutaneous PCL lesions. In addition, several case series have demonstrated that physicians may be able to use the semi-quantitative measurement of ^{18}F -FDG uptake provided by ^{18}F -FDG PET to predict which lesions are most aggressive. Other case series have shown that the integrated ^{18}F -FDG PET/CT may provide an objective measure of treatment response in patients with PCLs.

Hell J Nucl Med 2014; 17(2): 78-84

Epub ahead of print: 5 July 2014

Published online: 7 August 2014

Introduction

Primary cutaneous lymphomas (PCLs) are rare conditions comprising 2% of all lymphomas with an annual incidence of 0.3 to 1 per 100,000. Primary cutaneous lymphomas are the second most common type of extra-nodal non-Hodgkin's lymphomas (NHLs) after gastrointestinal NHL [1]. Cutaneous T-cell lymphoma (CTCL) is the most common PCL subtype, accounting for 71% of all PCL cases [2].

Cutaneous T-cell lymphoma has a myriad of clinical presentations including thin patches, thick plaques, and tumors located in all layers of the skin and subcutaneous tissue. It can also have extra-cutaneous manifestations including lymph node (LN), blood, and visceral organ involvement [2]. Mycosis fungoides (MF) associated with patches, plaques, and/or tumors comprises 54% of all CTCL, making it the most common type [3]. Sézary syndrome (SS) is the second most common type and is typically characterized by erythroderma and the presence of Sézary cells in the peripheral blood. Given the array of presentations, diagnosing CTCL is not always straight-forward and requires consideration of clinical evidence, histological findings, and peripheral blood studies [2]. Treatment of CTCL depends on the stage of disease (Table 1) [4, 5]. That the management of CTCL is stage-dependent underscores the importance of accurately gauging the extent of disease. Also, because extent of disease is one of the most important prognostic factors in CTCL [6], accurate staging enhances the physician's ability to predict clinical outcome.

Staging lymphomas has long relied on radiological imaging. While computed tomography (CT) has served as the primary modality to image lymphomas, [^{18}F]-fluorodeoxyglucose positron emission tomography (^{18}F -FDG PET) has become increasingly important. Several studies have shown that ^{18}F -FDG PET is highly sensitive in the detection of both nodal and extra-nodal lesions in lymphomas [7-9]. Similarly, studies have demonstrated that ^{18}F -FDG PET detects lymphomas at a greater number of sites, particularly extra-nodal locations, than CT alone [8, 10, 11]. Other studies assert that ^{18}F -FDG PET is highly sensitive, specific, and accurate when used in the initial staging of lymphomas [12] and additional studies have found that ^{18}F -FDG PET can provide accurate follow-up and prognostic information in lymphomas [13, 14]. However, in contrast to the extensive literature on the use of ^{18}F -FDG PET in lymphomas in general, the literature regarding the roles of ^{18}F -FDG

Dedicated Review Article

PET imaging in PCLs specifically is less extensive and is reviewed here.

Visualizing cutaneous and extra-cutaneous lesions

Delineating both cutaneous and extra-cutaneous disease is crucial to staging PCLs and providing patients with the best prognosis and treatment recommendations. Several studies have analyzed the role of ^{18}F -FDG PET, CT, and integrated ^{18}F -FDG PE-T/CT in cutaneous and extra-cutaneous involvement in PCLs (Table 2).

Table 1. International Society for Cutaneous Lymphomas (ISCL) and European Organization of Research and Treatment of Cancer (EORTC) revision to the classification of mycosis fungoides and Sézary syndrome [5]

Skin	
T1	Limited patches, papules, and/or plaques covering <10% of the skin surface
T2	Patches, papules, or plaques covering \geq 10% of the skin surface
T3	One or more tumors \geq 1cm diameter
T4	Confluence of erythema covering \geq 80% body surface area
Node	
N0	No clinically abnormal peripheral lymph nodes
N1	Clinically abnormal peripheral lymph nodes with NCI histopathology of LN0-2
N2	Clinically abnormal peripheral lymph nodes with NCI histopathology of LN3
N3	Clinically abnormal peripheral lymphnodes with NCI histopathology of LN4
Visceral	
M0	No visceral organ involvement
M1	Visceral organ involvement
Blood	
B0	Absence of significant blood involvement defined as \leq 5% of peripheral blood lymphocytes being atypical (Sézary cells)
B1	Low blood tumor burden defined as >5% of peripheral blood lymphocytes being atypical (Sézary cells) and <1000 Sézary cells per μ L of blood
B2	High blood tumor burden defined as \geq 1000 Sézary cells per μ L of blood

* LN histopathologic classification is based on NCI criteria. LN0: no atypical lymphocytes. LN1: occasional and isolated atypical lymphocytes not arranged in clusters. LN2: many atypical lymphocytes or atypical lymphocytes in 3-6 cell clusters. LN3: aggregates of atypical lymphocytes and nodal architecture preserved. LN4: partial/complete effacement of nodal architecture by atypical lymphocytes or frankly neoplastic cells.

Table 2. Studies reviewed in this article including at least 9 patients with primary cutaneous lymphomas

Study, year	Design	Number of patients	Results	Conclusions
Feeney et al., 2010 [16]	Retrospective analysis of initial stage and re-staging integrated ^{18}F -FDG-PET/CT scans	135 patients with T-cell lymphomas (44 with PCL (31 with MF/SS, 9 with SPTCL, 4 with C-ALCL))	Cutaneous lesions of patients with MF with large-cell transformation had average SUV_{max} of 11.3. Cutaneous lesions of patients with MF without large-cell transformation had average SUV_{max} of 3.8. Integrated ^{18}F -FDG PET/CT detected some plaque and tumor cutaneous lesions in patients with MF, was unable to detect patch cutaneous lesions in patients with MF, and detected pattern of diffusely increased cutaneous uptake in 2 of 6 patients with SS and erythroderma.	Patients with T-cell lymphomas should undergo integrated ^{18}F -FDG PET/CT at initial staging. ^{18}F -FDG PET/CT may guide biopsies to the most ^{18}F -FDG-avid lesions if large-cell transformation is suspected.
Kako et al., 2007 [15]	Retrospective analysis of pre-treatment ^{18}F -FDG PET scans	41 patients with T/NK cell neoplasms (9 with PCL (3 with MF/SS, 5 with C-ALCL, and 1 with SPTCL))	^{18}F -FDG PET identified extra-cutaneous lesions confirmed by physical, CT, and/or bone marrow exam in 5 of 5 patients with PCL with such lesions. ^{18}F -FDG PET identified biopsy-confirmed cutaneous lesions (each tumorous) in 3 of 9 patients with PCL with such lesions. ^{18}F -FDG PET was unable to identify patches, plaques, or erythroderma in any of 14 patients with T or NK-cell neoplasms with these cutaneous lesions.	T/NK cell neoplasms were typically ^{18}F -FDG-avid with the exceptions of cutaneous and bone marrow lesions.

Dedicated Review Article

Kumar et al., 2006 [23]	Retrospective analysis of initial staging and re-staging ^{18}F -FDG PET and CT scans	19 patients with PCL (15 with CTCL and 4 with cutaneous B-cell lymphomas)	Initial staging ^{18}F -FDG PET had sensitivities of 82% in detection of cutaneous disease and 80% in detection of extra-cutaneous disease. Initial staging CT had sensitivities of 55% in detection of cutaneous disease and 100% in detection of extra-cutaneous disease. Re-staging ^{18}F -FDG PET had sensitivity of 86% and specificity of 92% in detection of cutaneous disease and sensitivity and specificity of 100% in detection of extra-cutaneous disease. Re-staging CT had sensitivity of 50% and specificity of 83% in detection of cutaneous disease and sensitivity of 100% and specificity of 67% in detection of extra-cutaneous disease.	^{18}F -FDG PET was more accurate than CT in detecting both cutaneous and extra-cutaneous disease in PCL.
Tsai et al., 2006 [24]	Prospective analysis of integrated ^{18}F -FDG PET/CT scans	13 patients with PCL (13 with MF/SS)	CT component of integrated ^{18}F -FDG PET/CT scan identified positive LNs in 5 of 13 patients. ^{18}F -FDG PET component of integrated ^{18}F -FDG PET/CT scan identified positive LNs in 13 of 13 patients. LN 1-4 nodes without large-cell transformation had mean SUV of 2.9 and LN 4 nodes with large-cell transformation had mean SUV of 6.1.	Integrated ^{18}F -FDG PET/CT was more sensitive in its detection of involved LNs than CT alone. Intensity of ^{18}F -FDG avidity in a positive LN correlated with the histologic grade of the LN.
Valencak et al., 2004 [22]	Cross-sectional analysis of initial staging ^{18}F -FDG PET scans	13 patients with PCL (13 with CTCL (11 with MF/SS, 2 with CD30 ⁺ T-cell lymphoma))	4 of 4 patients found to have stage IV CTCL by conventional staging methods (physical exam, chest radiography, sonography, and CT in patients with internal organ involvement) had positive ^{18}F -FDG PET scans at the sites of CTCL. 0 of 9 patients found to have stage Ia CTCL by conventional staging methods had positive ^{18}F -FDG PET scans at the sites of CTCL.	^{18}F -FDG PET did not improve routine staging of CTCL, but might add valuable clinical information, help locate biopsy sites, and/or aid therapy planning in patients with advanced disease.

PCL: Primary cutaneous lymphoma; MF/SS: Mycosis fungoides / Sézary syndrome; SPTCL: subcutaneous panniculitis-like T-cell lymphoma; C-ALCL: cutaneous anaplastic large-cell lymphoma

Kako et al. (2007) [15] retrospectively analyzed the pretreatment ^{18}F -FDG PET scans of 41 patients with T or natural killer (NK) cell neoplasms, including 9 patients with PCLs (5 with primary cutaneous anaplastic large-cell lymphoma (C-ALCL), 3 with MF/SS, and 1 with subcutaneous panniculitis-like T-cell lymphoma (SPTCL)). Fluorine-18 FDG PET positively identified extra-cutaneous lesions also confirmed by physical, CT, and/or bone marrow examinations in 5 of 5 patients with PCLs (3 with C-ALCL, 1 with SPTCL, and 1 with MF/SS). However, they found that ^{18}F -FDG PET positively identified biopsy-confirmed cutaneous lesions in only 3 of 9 patients with PCLs (2 with C-ALCL and 1 with SPTCL) and that each of these 3 lesions was characterized clinically as a tumor. Fluorine-18-FDG PET was unable to identify patches, plaques, or erythroderma in any of the 14 patients with T or NK-cell neoplasms with such cutaneous lesions.

In contrast, a retrospective analysis [16] found that integrated ^{18}F -FDG PET/CT scans were unable to detect patch cutaneous lesions, but positively identified plaque cutaneous lesions in some patients with MF and detected a pattern of diffuse increased cutaneous ^{18}F -FDG uptake in 2 patients with SS and erythroderma. However, ^{18}F -FDG PET/CT scans did not detect a similar pattern in 4 other patients with SS and erythroderma.

Bishu et al. (2007) [17] retrospectively analyzed the accuracy of ^{18}F -FDG PET and CT in 24 patients with peripheral T-cell lymphoma (PTCL), including 5 patients with stage Ia CTCL (4 with primary cutaneous PTCL and 1 with C-ALCL). CT images did not identify any of the 4 biopsy-confirmed cutaneous lesions. However, ^{18}F -FDG PET positively identified 1 of these 4 cutaneous lesions. This study also summed the results of 4 studies evaluating CT in PCL [18-21] and found that none of the 72 patients with stage I disease had positive CT scans and that CT identified cutaneous lesions in only 8 of 158 patients. Interestingly, each of these 8 patients had at least stage 2 disease. The paper also pooled the results of 3 studies that evaluated ^{18}F -FDG PET in PCLs [22-24] and dis-

covered that ^{18}F -FDG PET or ^{18}F -FDG PET/CT scans were positive in 4 of 16 patients with stage I disease. These findings suggest that ^{18}F -FDG PET and ^{18}F -FDG PET/CT are better than CT alone at detecting lesions in patients with stage I disease and the majority of patients with early stage CTCL seem to have unremarkable imaging studies.

Kumar et al. (2006) [23] also compared CT and ^{18}F -FDG PET in the evaluation of PCLs. They retrospectively analyzed 31 pairs of ^{18}F -FDG PET and CT scans performed within 1 month of each other in 19 patients with PCLs (15 with CTCL and 4 with cutaneous B-cell lymphoma) and compared the results to a reference standard established by clinical parameters (change in lactate dehydrogenase level and in symptomatic disease) and/or biopsy. The 11 ^{18}F -FDG PET scans for initial staging had a sensitivity of 82% in the evaluation of cutaneous disease and a sensitivity of 80% for extra-cutaneous involvement. The 11 initial staging CT scans had a sensitivity of 55% in cutaneous disease and a sensitivity of 100% in extra-cutaneous involvement. In the 20 follow-up ^{18}F -FDG PET scans performed for re-staging, ^{18}F -FDG PET had a sensitivity of 86% and specificity of 92% for cutaneous disease and sensitivity and specificity of 100% in extra-cutaneous involvement. In the 20 follow-up CT scans performed for re-staging, CT had a sensitivity of 50% and specificity of 83% for cutaneous disease and a sensitivity of 100% and specificity of 67% for extra-cutaneous involvement. Finding ^{18}F -FDG PET more accurate than CT in detecting both cutaneous and extra-cutaneous disease, the authors concluded that ^{18}F -FDG PET is valuable for both initial staging and re-staging in patients with PCLs. They also suggested that CT might provide inadequate post-treatment assessment because it takes longer for extra-nodal and nodal lesions to normalize in size than in metabolic activity.

While most of the literature investigated ^{18}F -FDG PET alone in PCLs, few studies have looked at the role of the integrated ^{18}F -FDG PET/CT scan in PCLs. Tsai et al. (2006) [24] analyzed how ^{18}F -FDG PET/CT imaging impacted the accuracy of staging in 13 patients with MF/SS considered to be at high risk for secondary LN involvement. The LN with the highest ^{18}F -FDG uptake was then excised, biopsied, and assigned a National Cancer LN histopathologic stage (LN1-4) (Table 1). While readers of ^{18}F -FDG PET scans generally deem LNs positive when they show hyper-metabolic activity, readers of CT use size of LNs to deem them positive. Only 5 patients had LNs enlarged enough to be considered positive by CT. In contrast, ^{18}F -FDG PET revealed hyper-metabolic LNs in all 13 patients. Biopsies of these hyper-metabolic LNs showed a wide range of histopathologic stages (2 with LN1, 3 with LN2, 1 with LN3, 2 with LN4, and 5 with LN4 and large-cell transformation). In addition, the LN biopsies of 2 patients with positive LNs on ^{18}F -FDG PET but without palpable lymphadenopathy or positive LNs on CT were found to have large-cell transformation (considered a more aggressive form of MF). They concluded that the ^{18}F -FDG PET/CT scan is more sensitive in detection of involved LNs than CT alone and, thus, may provide more accurate staging and prognosis in patients with MF/SS.

A case series by Kuo et al. (2008) [25] compared the information provided by ^{18}F -FDG PET/CT scans in 7 patients with varying stages of CTCL to data from CT scan and physical ex-

amination. The authors suggested that ^{18}F -FDG PET/CT can distinguish reactive LNs from malignancy because it visualizes more LN features than CT or ^{18}F -FDG PET alone. Specifically, CT can show fatty hila in LNs and ^{18}F -FDG PET can demonstrate faint ^{18}F -FDG uptake, both characteristics that are more typical of reactive LNs. The authors also concluded that ^{18}F -FDG PET/CT was better at detecting subcutaneous lesions than physical examination and demonstrated that ^{18}F -FDG PET/CT can illustrate visceral involvement. A case report [26] similarly claimed that both CT and ^{18}F -FDG PET scans are valuable for determining the distribution, morphological patterns, and metabolic activity of subcutaneous lesions in subcutaneous panniculitis-like T-cell lymphoma (SPTCL). In addition, two recent case reports [27, 28] further demonstrated the usefulness of ^{18}F -FDG PET/CT imaging in assessing disease activity and treatment response in patients with SPTCL lesions.

Few studies have thoroughly compared staging techniques utilizing ^{18}F -FDG PET to those that do not. The most comprehensive analysis comparing staging with ^{18}F -FDG PET to conventional staging methods was conducted by Valencak et al. (2004) [22]. They staged 13 patients with CTCL prior to treatment using ^{18}F -FDG PET alone and compared the results to the reference values established by conventional staging methods (physical exam, chest radiography, sonography, and CT in patients with internal organ involvement). While all 4 patients found to have high stage (IV) CTCL by conventional staging methods also had positive ^{18}F -FDG PET scans at the sites of disease involvement, none of the 9 patients with low stage (Ia) CTCL by conventional staging methods had positive ^{18}F -FDG PET scans at the disease sites. Thus, the authors did not recommend the use of ^{18}F -FDG PET in routine staging of CTCL. However, they noted that in patients with advanced disease, ^{18}F -FDG PET may add valuable clinical information, help locate biopsy sites, and/or aid the planning of therapy.

Evaluating tumor biology and behavior

Assessing ^{18}F -FDG PET's ability to characterize the biology and predict the behavior of tumors has been the subject of much research. Studies have indicated that ^{18}F -FDG uptake is less in low-grade than high-grade lymphomas [29, 30]. Feeny et al. (2010) [16] evaluated the ^{18}F -FDG uptake on ^{18}F -FDG PET/CT scans of 135 patients with T-cell lymphoma, including 44 with PCLs (31 with MF/SS, 9 with SPTCL, and 4 with C-ALCL). Results showed that ^{18}F -FDG uptake was significantly higher in MF lesions with than without large-cell transformation. Similarly, Tsai et al. (2006) [24] found that the LNs demonstrating MF/SS with large-cell transformation had higher SUVs and concluded that more malignantly graded LNs had higher maximum SUVs (SUVmax).

Briefly reviewing literature which analyzed the use of ^{18}F -FDG PET in evaluating the biology of other types of neoplasms may underscore its potential role in PCLs. A study by Basu et al. (2008) [31] showed that ^{18}F -FDG uptake as measured by SUVmax is higher in more aggressive than less aggressive types of breast cancer. Kidd et al. (2009) showed that ^{18}F -FDG uptake as measured by SUVmax was higher in individuals with poorly differentiated than well-differentiated cervical

Dedicated Review Article

cancers [32] and that pre-treatment ^{18}F -FDG uptake measured by SUVmax was higher in cervical cancers with LN metastases at diagnosis than those without LN metastases [33]. Similarly, a multivariate analysis [34] showed that the strongest predictor of survival in patients with thyroid cancer was volume of ^{18}F -FDG-avid disease. A retrospective study [35] on thyroid cancer patients demonstrated inverse relationships between survival and both the number of ^{18}F -FDG-avid lesions and the glycolytic rate of the most active lesion.

Assessing response and outcome

Several case series have used ^{18}F -FDG PET to assess treatment response in patients with PCLs. Kuo et al. (2008) [36] evaluated the response of 3 patients with CTCL of stage $\geq 2b$ to a histone deacetylase inhibitor Vorinostat by analyzing disease activity on ^{18}F -FDG PET/CT scans taken both immediately before therapy initiation and 5 months after starting therapy. Comparison of ^{18}F -FDG PET/CT scans before and during treatment identified lesions that improved and failed to respond to treatment. These findings were consistent with changes in physical exam. They concluded that ^{18}F -FDG PET/CT could serve as an objective measure of both cutaneous and nodal response to therapy.

Another series by Kuo et al. (2008) [25] included a patient with CTCL whose pre and post-radiotherapy ^{18}F -FDG PET/CT images showed significant decreases in both SUV and lesion thickness following treatment. This objectively demonstrated a favorable treatment response consistent with improved clinical status. Shapiro et al. (2002) [37] documented the resolution of cutaneous and visceral lesions on ^{18}F -FDG PET following the initiation of treatment in a patient with SPTCL and in another with primary cutaneous follicle center B-cell lymphoma. Figure 1 shows consecutive ^{18}F -FDG PET images obtained at the Hospital of the University of Pennsylvania of a patient with CTCL. The decrease in the patient's lower extremity global metabolic burden (GMB) of disease, a value directly proportional to the summed SUVs of all lesions in the lower extremities, was consistent with the patient's favorable response to chemotherapy.

There is more research addressing the use of integrated ^{18}F -FDG PET/CT in assessing the treatment response in other types of lymphomas. A review by Mato et al. (2012) [38] analyzed the literature regarding the potential role of ^{18}F -FDG PET/CT in providing personalized therapy for diffuse large B-cell lymphoma (DLBCL), the most common subtype of NHLs. This review concluded that the available literature has not definitively determined that mid-therapy ^{18}F -FDG PET/CT imaging provides improved prognostic information to patients with DLBCL undergoing front-line chemotherapy. However, it also suggests that the use of ^{18}F -FDG PET/CT following immunochemotherapy may improve the identification of patients with DLBCL who have a favorable prognosis or high likelihood of relapse.

Radiation exposure

There is some concern over the amount of radiation exposure incurred by patients undergoing ^{18}F -FDG PET and CT

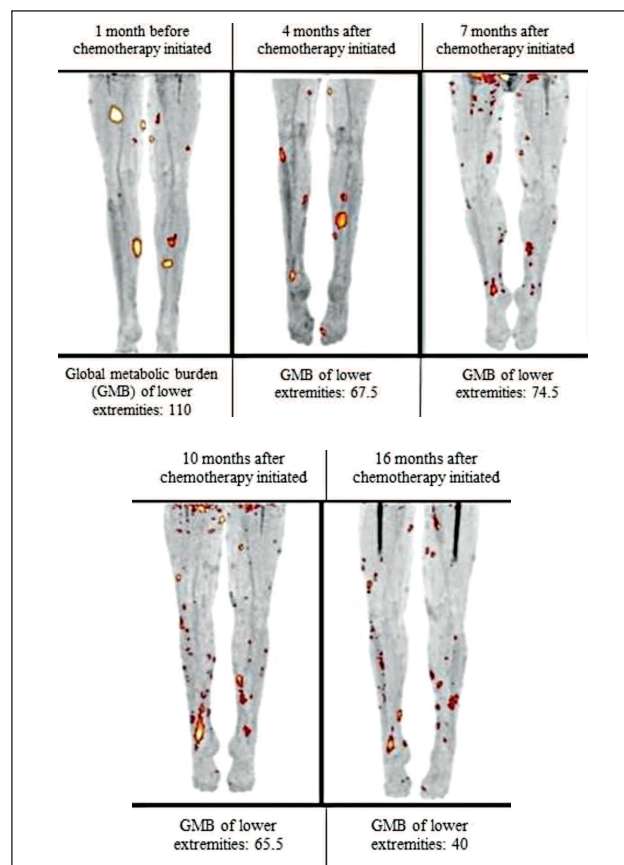


Figure 1. Consecutive ^{18}F -FDG PET images of a 43 years old patient with cutaneous T-cell lymphoma treated with chemotherapy. A global metabolic burden (GMB) of the lower extremities is directly proportional to the summed standardized uptake values (SUVs) of all lesions in the lower extremities. Decrease in the patient's lower extremity GMB was consistent with her favorable clinical response to chemotherapy.

scans. Thus, it is helpful to review estimations of the effective radiation doses. Mettler et al. (2008) [39] approximated the average effective radiation doses to be 7.0 millisievert (mSv) (with other literature reporting a range of 4.0–18.0mSv) in the chest CT, 8.0mSv (others reporting a range of 3.5–25.0mSv) in the abdominal CT, and 6.0mSv (others reporting a range of 3.3–10) in the pelvic CT. They also estimated the average effective radiation dose of the tumor ^{18}F -FDG PET to be 14.1mSv. Although the integrated ^{18}F -FDG PET/CT requires both PET and CT images, the type of CT scan used in the ^{18}F -FDG PET/CT has a lower effective radiation dose than the stand-alone CT. A study conducted by Huang et al. (2009) [40] assessed the effective radiation doses of 3 whole-body ^{18}F -FDG PET/CT protocols differing in their tube potentials, tube currents, and noise levels. The effective radiation doses for the whole-body ^{18}F -FDG PET/CT scans used in this study ranged from 13.45mSv to 31.91mSv in females and 13.65mSv to 32.18mSv in males. Thus, although the whole-body ^{18}F -FDG PET/CT does not necessarily expose the patient to significantly more radiation than a stand-alone CT of the chest, abdomen, and pelvis or a tumor ^{18}F -FDG PET scan, a physician considering use of the ^{18}F -FDG PET/CT scan must carefully weigh its risks and benefits.

In conclusion, the literature reviewed here suggests that ^{18}F -FDG PET is superior to CT in detection of nodal and cutaneous PCL lesions, but that ^{18}F -FDG PET does not ade-

Dedicated Review Article

quately detect erythroderma, plaque, or patch cutaneous lesions. Several series have demonstrated that SUV may predict the presence of particularly aggressive disease and that the integrated ^{18}F -FDG PET/CT may eventually provide a valuable, objective measure of treatment response in patients with PCLs. However, this literature has limited value since it mostly relies on retrospective analyses and case series. While ^{18}F -FDG PET/CT is a powerful imaging modality that holds promise in assessing PCLs, further large-scale prospective studies are necessary to define its role in clinical practice. PET/MRI may also have a potential role in nodal and cutaneous PCL lesions since MRI provides better delineation of anatomical structure than CT.

The authors declare that they have no conflicts of interest.


Bibliography

- Groves FD, Linet MS, Travis LB, Devesa SS. Cancer surveillance series: non-Hodgkin's lymphoma incidence by histologic subtype in the United States from 1978 through 1995. *J Natl Cancer Inst* 2000; 92: 1240-51.
- Burg G, Kempf W, Cozzio A et al. Cutaneous malignant lymphomas: update 2006. *J Dtsch Dermatol Ges* 2006; 4: 914-33.
- Kim YH, Chow S, Varghese A, Hoppe RT. Clinical characteristics and long-term outcome of patients with generalized patch and/or plaque (T2) mycosis fungoides. *Arch Dermatol* 1999; 135: 26-32.
- Prince HM, Whittaker S, Hoppe RT. How I treat mycosis fungoides and Sézary syndrome. *Blood* 2009; 114: 4337-53.
- Olsen E, Vonderheid E, Pimpinelli N et al. Revisions to the staging and classification of mycosis fungoides and Sézary syndrome: a proposal of the International Society for Cutaneous Lymphomas (ISCL) and the cutaneous lymphoma task force of the European Organization of Research and Treatment of Cancer (EORTC). *Blood* 2007; 110: 1713-22.
- Agar NS, Wedgeworth E, Crichton S et al. Survival outcomes and prognostic factors in mycosis fungoides/Sézary syndrome: validation of the revised International Society for Cutaneous Lymphomas/European Organisation for Research and Treatment of Cancer staging proposal. *J Clin Oncol* 2010; 28: 4730-9.
- Moog F, Bangerter M, Diederichs CG et al. Lymphoma: role of whole-body 2-deoxy-2-[^{18}F]fluoro-D-glucose (FDG) PET in nodal staging. *Radiology* 1997; 203: 795-800.
- Moog F, Bangerter M, Diederichs CG et al. Extranodal malignant lymphoma: detection with FDG PET versus CT. *Radiology* 1998; 206: 475-81.
- Elstrom R, Guan L, Baker G et al. Utility of FDG-PET scanning in lymphoma by WHO classification. *Blood* 2003; 101: 3875-6.
- Moog F, Bangerter M, Kotzerke J et al. ^{18}F -fluorodeoxyglucose-positron emission tomography as a new approach to detect lymphomatous bone marrow. *J Clin Oncol* 1998; 16: 603-9.
- Jerusalem G, Beguin Y, Fassotte MF et al. Whole-body positron emission tomography using ^{18}F -fluorodeoxyglucose for post-treatment evaluation in Hodgkin's disease and non-Hodgkin's lymphoma has higher diagnostic and prognostic value than classical computed tomography scan imaging. *Blood* 1999; 94: 429-33.
- Kumar R, Maillard I, Schuster SJ, Alavi A. Utility of fluorodeoxyglucose-PET imaging in the management of patients with Hodgkin's and non-Hodgkin's lymphomas. *Radiol Clin North Am* 2004; 42: 1083-100.
- Zinzani PL, Stefoni V, Tani M et al. Role of [^{18}F]fluorodeoxyglucose positron emission tomography scan in the follow-up of lymphoma. *J Clin Oncol* 2009; 27: 1781-7.
- Fruchart C, Reman O, Le Stang N et al. Prognostic value of early ^{18}F -fluorodeoxyglucose positron emission tomography and gallium-67 scintigraphy in aggressive lymphoma: a prospective comparative study. *Leuk Lymphoma* 2006; 47: 2547-57.
- Kako S, Izutsu K, Ota Y et al. FDG-PET in T-cell and NK-cell neoplasms. *Ann Oncol* 2007; 18: 1685-90.
- Feeney J, Horwitz S, Gonen M, Schoder H. Characterization of T-cell lymphomas by FDG PET/CT. *Am J Roentgenol* 2010; 195: 333-40.
- Bishu S, Quigley JM, Schmitz J et al. F-18-fluoro-deoxy-glucose positron emission tomography in the assessment of peripheral T-cell lymphomas. *Leuk Lymphoma* 2007; 48: 1531-8.
- Howlett DC, Wong WL, Smith NP, Ayers AB. Computed tomography in the evaluation of cutaneous T-cell lymphoma. *Eur J Radiol* 1995; 20: 39-42.
- Bass JC, Korobkin MT, Cooper KD et al. Cutaneous T-cell lymphoma: CT in evaluation and staging. *Radiology* 1993; 186: 273-8.
- Miketic LM, Chambers TP, Lembersky BC. Cutaneous T-cell lymphoma: value of CT in staging and determining prognosis. *Am J Roentgenol* 1993; 160: 1129-32.
- Kulin PA, Marglin SI, Shuman WP et al. Diagnostic imaging in the initial staging of mycosis fungoides and Sézary syndrome. *Arch Dermatol* 1990; 126: 914-8.
- Valencak J, Becherer A, Der-Petrossian M et al. Positron emission tomography with [^{18}F] 2-fluoro-D-2-deoxyglucose in primary cutaneous T-cell lymphomas. *Haematologica* 2004; 89: 115-6.
- Kumar R, Xiu Y, Zhuang HM, Alavi A. ^{18}F -fluorodeoxyglucose-positron emission tomography in evaluation of primary cutaneous lymphoma. *Br J Dermatol* 2006; 155: 357-63.
- Tsai EY, Taur A, Espinosa L et al. Staging accuracy in mycosis fungoides and Sézary syndrome using integrated positron emission tomography and computed tomography. *Arch Dermatol* 2006; 142: 577-84.
- Kuo PH, McClennan BL, Carlson K et al. FDG-PET/CT in the evaluation of cutaneous T-cell lymphoma. *Mol Imaging Biol* 2008; 10: 74-81.
- Schramm N, Pfluger T, Reiser MF, Berger F. Subcutaneous panniculitis-like T-cell lymphoma with breast involvement: functional and morphological imaging findings. *Br J Radiol* 2010; 83: 90-4.
- Kim JS, Jeong YJ, Sohn MH et al. Usefulness of F-18 FDG PET/CT in subcutaneous panniculitis-like T cell lymphoma: disease extent and treatment response evaluation. *Radiol Oncol* 2012; 46(4): 279-83.
- Mitsuhashi K, Momose M, Masuda A, Tsunemi Y et al. Positron emission tomography revealed diffuse involvement of the lower legs and occult extracutaneous lesions in subcutaneous panniculitis-like T-cell lymphoma. *Clin Nucl Med* 2013; 38(3): 209-11.
- Schöder H, Noy A, Gonen M et al. Intensity of ^{18}F -fluorodeoxyglucose uptake in positron emission tomography distinguishes between indolent and aggressive non-Hodgkin's lymphoma. *J Clin Oncol* 2005; 23: 4643-51.
- Ngeow JY, Quek RH, Ng DC et al. High SUV uptake on FDG-PET/CT predicts for an aggressive B-cell lymphoma in a prospective study of primary FDG-PET/CT staging in lymphoma. *Ann Oncol* 2009; 20: 1543-7.
- Basu S, Chen W, Tchou J et al. Comparison of triple-negative and estrogen receptor-positive/progesterone receptor-positive/HER2-negative breast carcinoma using quantitative fluorine-18 fluorodeoxyglucose/positron emission tomography imaging parameters: a potentially useful method for disease characterization. *Cancer* 2008; 112: 995-1000.
- Kidd EA, Spencer CR, Huettner PC et al. Cervical cancer histology and tumor differentiation affect ^{18}F -fluorodeoxyglucose uptake. *Cancer* 2009; 115: 3548-54.
- Kidd EA, Siegel BA, Dehdashti F, Grigsby PW. The standardized uptake value for F-18 fluorodeoxyglucose is a sensitive predictive biomarker for cervical cancer treatment response and survival. *Cancer* 2007; 110: 1738-44.
- Wang W, Larson SM, Fazzari M et al. Prognostic value of [^{18}F]fluorodeoxyglucose positron emission tomographic scanning in patients with thyroid cancer. *J Clin Endocrinol Metab* 2000; 85: 1107-13.
- Robbins RJ, Wan Q, Grewal RK et al. Real-time prognosis for metastatic thyroid carcinoma based on 2-[^{18}F]fluoro-2-deoxy-D-glucose-positron emission tomography scanning. *J Clin Endocrinol Metab* 2006; 91: 498-505.
- Kuo PH, Carlson KR, Christensen I et al. FDG-PET/CT for the evaluation of response to therapy of cutaneous T-cell lymphoma to vorinostat (suberoylanilidehydroxamic acid, SAHA) in a phase II trial. *Mol Imaging Biol* 2008; 10: 306-14.
- Shapiro M, Yun M, Junkins-Hopkins JM et al. Assessment of tumor burden and treatment response by ^{18}F -fluorodeoxyglucose injection and positron emission tomography in patients with cutaneous T- and B-cell lymphomas. *J Am Acad Dermatol* 2002; 47: 623-8.



Dedicated Review Article

38. Mato AR, Goy A. Role of positron emission tomography with fluoro-deoxyglucose F-18 in personalization of therapy in patients with lymphoma. *PET Clinics: PET Imaging of Lymphoma* 2012; 7: 57-65.
39. Mettler FA, Jr, Huda W, Yoshizumi TT, Mahesh M. Effective doses in radiology and diagnostic nuclear medicine: a catalog. *Radiology* 2008; 248: 254-63.
40. Huang B, Law MW, Khong PL. Whole-body PET/CT scanning: estimation of radiation dose and cancer risk. *Radiology* 2009; 251: 166-74.
-



Albrecht Dürer (1471-1528). The painter sent this sketch of himself to his physician. In this sketch he pointed to his physician where he felt a painful tumor and asked: "What is it?" It was an enlarged painful spleen due to malaria.

