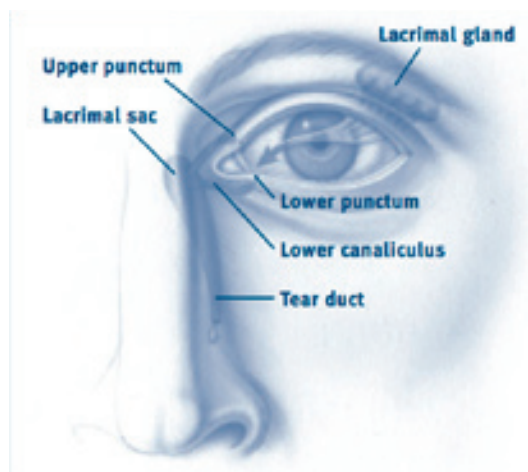


# Dacryoscintigraphy for the detection of ocular drainage system stenosis induced by docetaxel and fluorouracil

**To the Editor:** Docetaxel (D) is an antineoplastic agent of the taxane group produced by fir needles and is used in the treatment of breast, lung, prostate, stomach as well as of head and neck cancers [1-4]. It is usually administered in weekly or 3-weekly regimens [5]. Some side-effects of D are neutropenic fever, anemia, fluid retention, hypersensitivity reactions, anorexia, myalgias, mucositis, mild alopecia, skin and nail toxicity, peripheral neuropathy [6], canalicular stenosis and/or obstruction, epiphora and tearing [7-8]. Extensive fibrotic changes in the stroma of the lacrimal sac and the nasal mucosa are the prominent histologic features of the canalicular narrowing and nasolacrimal duct obstruction. Furthermore, studies in patients receiving D treatment showed that after intravenous infusion, D was usually secreted in tears causing ocular irritation [9]. The histologic evidence of keratinization with marked epidermalization of the surface epithelium, thickening, and parakeratosis of the squamous epithelium, confirms fibrosis [10].

Epiphora is a greek word meaning that the line of tears (phora) runs over the eye (epi). Epiphora is a clinical sign or condition, in which tears drain down the face rather than through the nasolacrimal system. Epiphora may also be due to ocular irritation and inflammation or to obstruction of tear outflow tract (Fig.1), ie. ectropion, punctal, canalicular or nasolacrimal obstruction. For punctal stenosis punctoplasty is performed, for subtotal stenosis a permanent silicone tube is advocated and for total stenosis a permanent bypass is required [11]. Dacryoscintigraphy is a well established diagnostic tool for the eye drainage apparatus, and its importance in diagnosing functional lacrimal duct obstruction and even classifying the types of obstruction to predict postoperative results of silicone tube insertion has been reported by others [12].



The eye's tear draining system

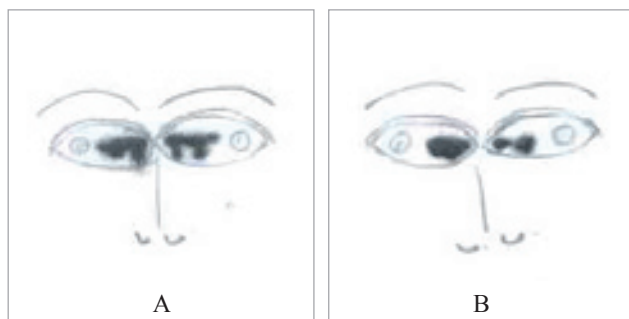**Figure 1.** A figure of the canaliculi area and the blockage area as may be shown in dacryoscintigraphies.

Chemotherapeutic drugs like D tend to be especially toxic to normal tissues and usually interfere with cell growth or proliferation. Thus, excessive tear production and epiphora, occur as a side effect of D, as the afflicted fibrosis disrupts the continuation of the membranous channel [13]. Although the severity and frequency of epiphora is less with the 3-weekly dosing schedule of D, an incidence of almost 40% has been reported even for this schedule, especially during the longer treatment regimens for metastatic breast cancer [14].

We report on two patients with epiphora and canalicular stenosis developed while on a 3-weekly D treatment regime. Both our patients agreed to be monitored with dacryoscintigraphy. The patients were seated in front of the low energy high resolution (LEHR) collimator of the gamma camera, and after applying 0.1mL of  $^{99m}\text{Tc}$ -pertechnetate of 3.7MBq on the conjunctiva near the internal canthus of each eyeball we recorded bilateral eyeball images. A dynamic scintigraphy of the area was obtained (9 frames of 1min duration each, followed by one 5min frame, matrix 64x64, LEHR collimator and no zoom), as the  $^{99m}\text{Tc}$ -pertechnetate flows along the tear strips, through the nasolacrimal drainage system, into the nasal fossa. By using LEHR collimator, the canaliculi, the lacrimal sac, the nasolacrimal duct and the Hasner's valve area [15] are normally visualized. When the flow in the lacrimal apparatus is impaired, dacryoscintigraphy will demonstrate the blockage and may also identify the site of obstruction. A follow-up with a second dacryoscintigraphy, a month after the end of D treatment, was performed.

The first patient, a 59 years old woman was treated for metastatic breast cancer with D. She received a 3-weekly treatment regime of 75mg/m<sup>2</sup> (130mg in total) intravenously, with dexamethasone coverage for a total of 6 cycles. She reported extensive tearing 2 weeks after the second cycle, which did not improve after discontinuation of the drug. She was advised to use artificial tears and visit the ophthalmology clinic. She had been reluctant to undergo any procedures but at least she agreed to be monitored with dacryoscintigraphy [16, 17]. Initial imaging of the drainage apparatus by dacryoscintigraphy, when symptoms appeared, showed complete bilateral blockage at the lower canaliculus (Fig. 2A and B).

The second patient, a 54 years old male with metastatic gastric carcinoma received a combination of docetaxel 75mg/m<sup>2</sup> (120mg in total), carboplatin 450mg and 6 pills capecitabine (xeloda) of 500mg each, in a weekly treatment regime (3 weeks treatment and one week intermission), with dexamethasone coverage for a total of 6 cycles. This patient had also refused to visit an ophthalmology clinic but followed our instructions to use artificial tears. The first dacryoscintigraphy was performed as soon as epiphora appeared, a few days after the first cycle of D treatment and the second, a month after the end of 6 cycles of



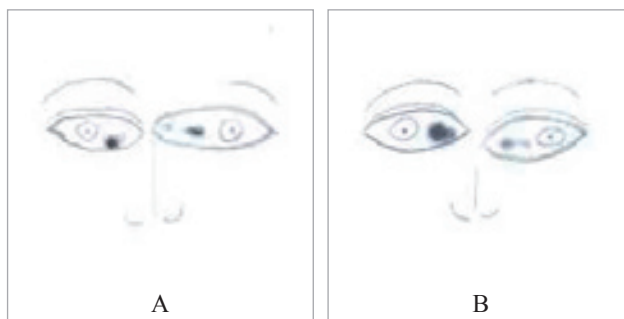
**Figure 2. A.** Patient with breast cancer during D treatment. **B.** One month after D treatment.

D treatment. Both dacryoscintigraphies, showed a bilateral total blockage of the drainage apparatus in the area of the lower canaliculus (Fig. 3A and B). Despite his complaints and discomfort, this patient was also reluctant to undergo any other procedures.

Capecitabine is a prodrug converted into fluorouracil (5FU) in the tissues [17]. This combination may increase the possibility of dacryostenosis. The cytotoxic metabolites of 5FU interfere with DNA replication and RNA synthesis in rapidly proliferating tear duct cells and may occasionally cause canalicular stenosis with intractable epiphora and even fibrosis, which is difficult to manage [18]. Furthermore, 5FU is also known to cause mucosal inflammation, conjunctivitis and GI tract inflammations. It may also be hypersecreted from the lacrimal gland, thus tears gaining access over the ocular surface may cause ocular surface toxicity and reflex tearing. The development of cicatricial ectropion further exacerbates the situation. The possibility that the above stenoses could be partly due to viral infection in an immunocompromised patient cannot be excluded [18]. The incidence and severity of lacrimation correlates with the concentration of 5FU in tears but is not directly related to its plasma levels [19].

Epiphora can have a negative impact on the quality of life, because it induces inability to read, drive, put on make up and gives the false impression of emotional tearing. If left untreated, epiphora may have a negative impact on visual function, with significantly lower visual acuity scores [20]. Artificial tears and/or eye drops containing corticosteroids are suggested for treatment [21]. Patients receiving D and/or 5FU should be closely followed by an ophthalmologist for an early diagnosis and treatment of epiphora that may prevent closure of ocular canaliculi [21]. Nuclear dacryoscintigraphy is simple, fast, cheap, and harmless technique for this diagnosis [16] and may replace a more uncomfortable and not so specific technique like the Schirmer's test, in which a filter paper is placed in the lower lid of the eye and the amount of tears is measured [22]. It would be valuable to add the importance of dacryoscintigraphy in the differential diagnosis of pseudoepiphora, which encompasses reflex tearing caused by inflammation or dry eyes, nasal disease, like allergic rhinitis, polyps, tumors or rhinoplasty [23]. It has been suggested that dacryoscintigraphy is the best method for measuring the dynamics of tear drainage especially in the canaliculi [24], although some prefer the CT dacryocystography, which gives a much higher radiation dose to the patient [25].

*In conclusion*, we have described one patient with epiphora after docetaxel treatment and another after both docetaxel and 5FU treatment and emphasize the diagnostic value of dacryoscintigraphy.



**Figure 3. A.** Patient with gastric carcinoma during D and 5FU treatment. **B.** A month after D and 5FU treatment.

The authors declare that they have no conflicts of interest.

### Bibliography

1. Valero V. Docetaxel as single-agent therapy in metastatic breast cancer: clinical efficacy. *Semin Oncol* 1997; 24(4 Suppl 13): 11-8.
2. Picus J, Schultz M. Docetaxel (Taxotere) as monotherapy in the treatment of hormone-refractory prostate cancer: preliminary results. *Semin Oncol* 1999; 26(5 Suppl 17): 14-8.
3. Nakamura T, Fuwa N, Takayama K et al. Phase I study of weekly docetaxel and cisplatin arterial infusion for recurrent head and neck cancer. *Head Neck* 2011. doi: 10.1002/hed.21983. [Epub ahead of print].
4. Khokhar NZ, Jiang Y, Benson AB 3rd et al. Refining docetaxel-containing therapy for gastric cancer. *Gastrointest Cancer Res* 2011; 4(3): 96-105.
5. Bedard PL, Di Leo A, Piccart-Gebhart MJ. Taxanes: optimizing adjuvant chemotherapy for early-stage breast cancer. *Nat Rev Clin Oncol* 2010; 7(1): 22-36.
6. Ferraresi V, Milella M, Vaccaro A et al. Toxicity and activity of docetaxel in anthracycline-pretreated breast cancer patients: a phase II study. *Am J Clin Oncol* 2000; 23(2): 132-9.
7. Esmaeli B, Valero V, Ahmadi MA, Booser D. Canalicular stenosis secondary to docetaxel (taxotere): a newly recognized side effect. *Ophthalmology* 2001; 108(5): 994-5.
8. Calonge M. The treatment of dry eye. *Surv Ophthalmol* 2001; 45(Suppl 2): S227-39.
9. Esmaeli B, Ahmadi MA, Rivera E et al. Docetaxel secretion in tears: association with lacrimal drainage obstruction. *Arch Ophthalmol* 2002; 120(9): 1180-2.
10. Esmaeli B, Burnstine MA, Ahmadi MA, Prieto VG. Docetaxel-induced histologic changes in the lacrimal sac and the nasal mucosa. *Ophthal Plast Reconstr Surg* 2003; 19(4): 305-8.
11. Ahmadi MA, Esmaeli B. Surgical treatment of canalicular stenosis in patients receiving docetaxel weekly. *Arch Ophthalmol* 2001; 119(12): 1802-4.
12. Chung YA, Yoo leR, Oum JS et al. The clinical value of dacryoscintigraphy in the selection of surgical approach for patients with functional lacrimal duct obstruction. *Ann Nucl Med* 2005; 19(6): 479-83.
13. Eisner A, Luoh SW. Breast cancer medications and vision: effects of treatments for early-stage disease. *Curr Eye Res* 2011; 36(10): 867-85.
14. Esmaeli B, Amin S, Valero V et al. Prospective study of incidence and severity of epiphora and canalicular stenosis in patients with metastatic breast cancer receiving docetaxel. *J Clin Oncol* 2006; 24(22): 3619-22.
15. Weber RK, Keerl R, Schaefer SxD, Della Rocca RC. *Atlas of lacrimal surgery*. Springer, Berlin, 2007; 6.

16. Von Denffer H, Dressler J, Pabst HW. Lacrimal dacryoscintigraphy. *Semin Nucl Med* 1984; 14(1): 8-15.
17. Brown M, El Gammal TA, Luxenberg MN, Eubig C. The value, limitations, and applications of nuclear dacryocystography. *Semin Nucl Med* 1981; 11(4): 250-7.
18. Prasad S, Kamath GG, Phillips RP. Lacrimal canalicular stenosis associated with systemic 5-fluorouracil therapy. *Acta Ophthalmol Scand* 2000; 78(1): 110-3.
19. Christophidis N, Vajda FJ, Lucas I, Louis WJ. Ocular side effects with 5-fluorouracil. *Aust N Z J Med* 1979; 9(2): 143-4.
20. Bakri SJ, Carney AS, Robinson K et al. Quality of life outcomes following dacryocystorhinostomy: external and endonasal laser techniques compared. *Orbit* 1999; 18(2): 83-8.
21. Leysens B, Wildiers H, Lobelle JP et al. A double-blind randomized phase II study on the efficacy of topical eye treatment in the prevention of docetaxel-induced dacryostenosis. *Ann Oncol* 2010; 21(2): 419-23.
22. Gontier J, Fisch U. Schirmer's test: its normal values and clinical significance. *ORL J Otorhinolaryngol Relat Spec* 1976; 38(1): 1-10.
23. Lew H, Lee SY, Kim SJ: The clinical evaluation on the patients complaining of epiphora. *J Korean Ophthalmol Soc* 2000; (41): 1112-7.
24. Denffer H, Dressler J, Pabst HW. Lacrimal dacryoscintigraphy. *Seminars in Nuclear Medicine* 1984; 14 (1): 8-15.
25. Nagi KS, Meyer DR. Utilization patterns for diagnostic imaging in the evaluation of epiphora due to lacrimal obstruction: a national survey. *Ophthal Plast Reconstr Surg* 2010; 26(3): 168-71.

**Gregory I Tsoucalas<sup>1</sup> MD, Alexandros A Tzovaras<sup>2</sup> MD, Anna P Ntokou<sup>2</sup> MD, Lambros I Markos<sup>2</sup> MD, Eleni N Sarafianou<sup>1</sup> MD**

*1. Nuclear Medicine Department and 2. 1st Oncology-Pathology Clinic, "The Saint Savvas" Hospital, Athens, Greece.*

**Gregory Tsoucalas MD**

Kononos 62-64, P.C. 11633, Pagrati, Athens, Tel: 2107562016, Mobile: 6945298205, Email: gregorytsoucalas@yahoo.gr

*Hell J Nucl Med* 2012; 15(2): 159-161

*Published on line: 27 June 2012  
Epub ahead of print: 27 June 2012*