

## Two artifacts in the $^{131}\text{I}$ whole body post treatment scan in a thyroid cancer patient

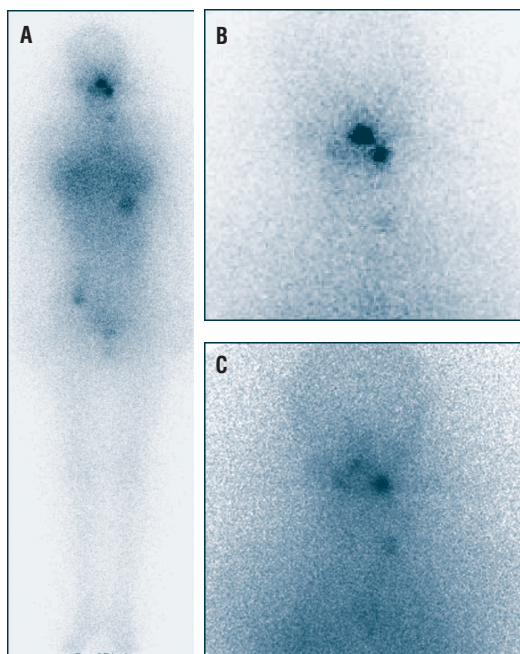
**To the Editor:** Although whole body scans with iodine-131 ( $^{131}\text{I}$ ) in patients with thyroid carcinoma are a routine examination, we consider of practical interest to bring to the attention of your readers, artifacts that may mimic metastases on the occasion of an usual case as follows: A 29 year old female underwent radioiodine treatment for papillary carcinoma of the thyroid gland with 4.44 GBq of  $^{131}\text{I}$ . Post treatment  $^{131}\text{I}$  whole body scan was performed 5 days after treatment. This scan showed two focal areas of abnormal tracer uptake in the head (Fig. 1A and 1B – anterior views). After eliciting the history of the patient, these “hot” areas were attributed to  $^{131}\text{I}$  accumulation in caries left sided molar tooth and around the nose pin that the patient who belonged to the Hindu religion wore in the nostrils. The patient vomited one hour after the administration of  $^{131}\text{I}$ . A second scan after removing the nose pin and cleaning the nostrils area, showed no activity in the nostrils. There was no change in caries tooth activity (Fig. 1C).

Whole body  $^{131}\text{I}$  post treatment scan is usually performed to see uptake of the tracer by normal thyroid tissue and possible metastatic sites that may be missed with the low dose whole body scan, performed before treatment. One should be careful while interpreting  $^{131}\text{I}$  post treatment scans, as there can be false positive results due to artifacts that may lead to improper treatment.

Artifacts in the whole body  $^{131}\text{I}$  scan as above, have been reported at various sites due to different reasons. Nineteen such artifacts mimicking bone metastases have been described and were shown to be due to external contamination as they disappeared on re-imaging after cleaning and garment change [1].  $^{131}\text{I}$  may accumulate at sites of lung inflammation or infection and can mimic pulmonary metastases [2]. In another case, iodine-123 was shown to be concentrated in the chest wall after needle biopsy of a lung nodule [3]. Breast uptake of  $^{131}\text{I}$  in the chest area, may appear even in non-lactating females [4]. Artifactual  $^{131}\text{I}$  activity in the cranial hair after thyroid remnant ablation has been reported due to sweating [5, 6]. Other important causes of false positive  $^{131}\text{I}$  artifacts have been also reported in esophageal and intestinal diverticuli and in other sites of the body [7-10]. The present case highlights unusual artifacts that may be revealed in the  $^{131}\text{I}$  whole body scans and may indicate the proper management of these patients.

### Bibliography

1. Bakheet SM, Hammami MM. Spurious thyroid cancer bone metastases on radioiodine scan due to external contamination. *Eur J Radiol* 1993; 16: 239-242.
2. Bakheet SM, Hammami MM, Powe J et al. Radioiodine uptake in inactive pulmonary tuberculosis. *Eur J Nucl Med* 1999; 26: 659-662.



**Figure 1.** A.  $^{131}\text{I}$  whole body post treatment scan showing two focal areas of abnormal tracer uptake with no other abnormal tracer uptake in the whole body. B. Anterior static image of the  $^{131}\text{I}$  post treatment scan shows two focal areas of abnormal tracer uptake. C. Anterior static image of the  $^{131}\text{I}$  post treatment scan after removal of the nose pin, showing no activity in the nostrils. However, there is still a single “hot” area projected in the left side of the mouth.

3. Naddaf SY, Akisik MF, Omar WS et al.  $^{123}\text{I}$  uptake in the chest wall after needle biopsy of a pulmonary nodule. A cause for false-positive  $^{123}\text{I}$  uptake. *Clin Nucl Med* 1997; 22: 572-573.
4. Hammami MM, Bakheet S. Radioiodine breast uptake in non-breastfeeding women: clinical and scintigraphic characteristics. *J Nucl Med* 1996; 7: 26-31.
5. Abdel-Dayem HM, Halker K, El Sayed M. The radioactive wig in iodine-131 whole body imaging. *Clin Nucl Med* 1984; 9: 454-455.
6. Bhargava P, Choi WS. Artifactual  $^{131}\text{I}$  activity in the hairs after thyroid remnant ablation. *Thyroid* 2006; 16: 1187-1189.
7. Rashid K, Johns W, Chasse K et al. Esophageal diverticulum presenting as metastatic thyroid mass on iodine-131 scintigraphy. *Clin Nucl Med* 2006; 31: 405-408.
8. McDougall IR. Whole-body scintigraphy with radioiodine-131. A comprehensive list of false-positives with some examples. *Clin Nucl Med* 1995; 20: 869-875.
9. Ash L, Bybel B, Neumann D, Beebe W. The helmet sign: Physiologic radioactive accumulation after  $^{131}\text{I}$  therapy—a case report. *J Nucl Med Technol* 2004; 32: 164-165.
10. Shapiro B, Rufini V, Jarwan A et al. Artifacts, anatomical and physiological variants, and unrelated diseases that might cause false-positive whole-body  $^{131}\text{I}$  scans in patients with thyroid cancer. *Semin Nucl Med* 2000; 30: 115-132.

**Ashwani Sood<sup>1</sup> MD, Rajeev K Seam<sup>1</sup> MD, Vikas Sood<sup>1</sup> MD, Rakesh Kumar<sup>2</sup> MD**

1. Nuclear Medicine Center, Department of Radiation Therapy, Indira Gandhi Medical College, Shimla – 171001, Himachal Pradesh, India.
2. Department of Nuclear Medicine, All India Institute of Medical Sciences, New Delhi – 110029, India.

**Rakesh Kumar MD, Associate Professor,**

Department of Nuclear Medicine, All India Institute of Medical Sciences, New Delhi-110029, India, Tel: 91-11-26594472, Fax: 91-11-26588663  
E-mail: rkphulia@hotmail.com

Published online: 19-11-2007

