Two cases of synovitis, acne, pustulosis, hyperostosis, osteitis - SAPHO syndrome

Trifon Spyridonidis, Costas Giannakenas, Nikos Papandrianos, Panagiota Barla, Dimitris J. Apostolopoulos

University of Patras Medical School, Department of Nuclear Medicine, Regional, University Hospital of Patras, Patras, Greece

Keywords: SAPHO syndrome – Bone scan imaging – Differential diagnosis

Correspondence address:
Trifon Spyridonidis, MD
University of Patras, Medical School, Department of Nuclear Medicine, Regional University Hospital of Patras, Rion, Patras, PC 26500, Greece
Tel: +30-2610-999210
Fax: +30-2610-994470
e-mail : *tspyr@med.upatras.gr*

Received:
22 March 2007
Accepted revised:
25 April 2007

Abstract

Synovitis, acne, pustulosis, hyperostosis, osteitis (SAPHO) syndrome is rare with yet unknown prevalence. The difficulty in recognizing the syndrome is due to the very wide diversity of its signs and symptoms, the lack of skin manifestations in many cases and to confusion in medical terminology in describing this syndrome. In this paper, we present two cases with characteristic bone lesions in bone scan and in radiology images that are considered to be SAPHO syndrome. In the first case the characteristic bone single photon emission tomography scan findings in a patient with spine involvement supposed by bone biopsy but were not followed by characteristic skin manifestations. The point of interest of this case lies on the significant improvement of both symptoms and scintigraphic findings after treatment with biphosphonates. In the second case the diagnosis was also based on the characteristic bone scan findings, although the patient referred to us for staging of prostate cancer. Detailed history and clinical examination revealed skin manifestations of the syndrome.

Hell J Nucl Med 2007; 10(2): 109-112

Introduction

Observations connecting synovitis, acne, pustulosis, hyperostosis, osteitis (SAPHO) syndrome to chronic cutaneous pustular lesions, such as palmar and plantar pustulosis, severe acne, pustular psoriasis, with bone lesions including a variety of osteoarticular manifestations from synovitis or/and arthritis to hyperostosis and aseptic osteitis, have been reported since early 60's [1-3]. The entity of chronic recurrent multifocal osteomyelitis (CRMO) was reported in 1972 [4] and an association between CRMO and palmoplantar pustulosis was described in 1978 [5]. Later, in 1987 Chamot et al proposed the term: SAPHO (synovitis, acne, pustulosis, hyperostosis, osteitis) as including many signs of this syndrome [6]. Kahn and Kahn [7] in 1994 determined the diagnostic criteria for the SAPHO syndrome. The syndrome is of unclarified aetiology, and by some rheumatologists is considered as a form of seronegative spodylarthropathy [8], while others relate this syndrome to the low virulence infectious agent propiobacterium acnes [9]. In adults, the most common sites of involvement are the joints of the anterior chest wall, followed by involvement of the axial skeleton, most frequently thoracic spine. Mandible is frequently involved [10].

Due to the diagnostic significance and the rarity of this syndrome, we report two cases with SAPHO syndrome, studied in our department during the last seven years.

Case 1

A 37 year-old man, worker in building constructions, was referred to our department in 1999, because of diffuse skeletal pain most prominent in the anterior chest wall and the clavicles and to a lesser degree in the thoracic spine. There was a suspicion of Paget's disease because of sclerosis and hyperostosis of the clavicles and the first ribs, suggested by the radiographs, the findings of the computerized tomography (CT) scan (Fig. 1) and the elevation of serum alkaline phosphatase. There was no history of trauma but there was a suspicion of occult injuries due to occupational exertion.

Bone scintigraphy performed by the intravenous (i.v.) injection of 740 MBq of technetium-99m medronate (^{99m}Tc) and single photon emission tomography-(SPET) demonstrated severely increased tracer uptake at the manubrium, the sternocalvicular joints, the medial segment of the clavicles, the first ribs bilaterally, and focally increased activity at the lower part of the sternum and the costochondral junction of the sixth right rib (Fig. 2A). There were foci of

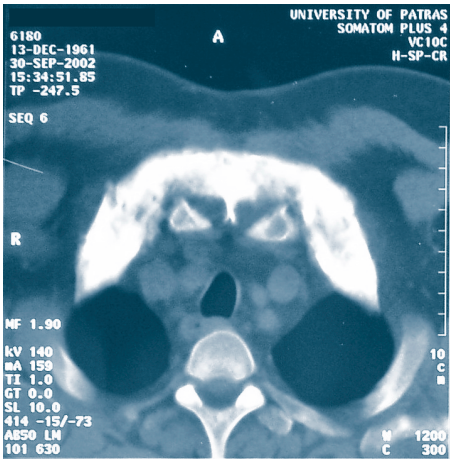

Figure 1. Case 1: Computerized tomography image of the chest at the level of the first costosternal joints. There is marked sclerosis of the manubrium and the costosternal portion of both first ribs.

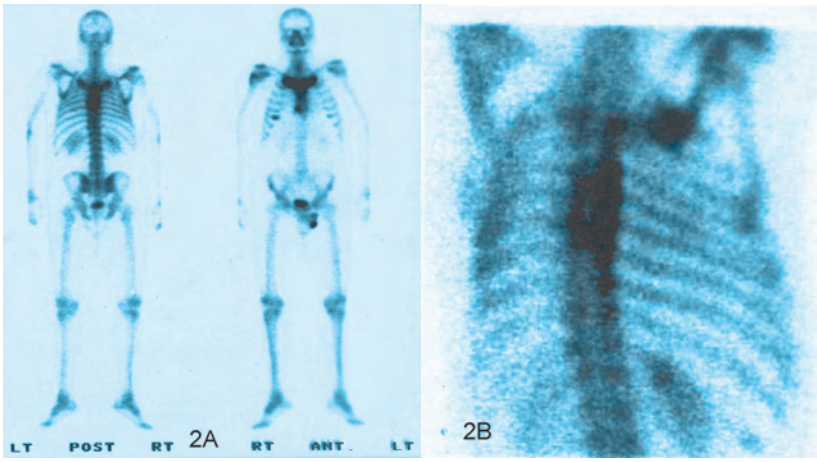

Figure 2. Case 1. A: The initial whole-body bone scan of case 2, showing multiple areas of increased uptake, at the manubrium, the medial segment of the clavicles and the first rib bilaterally, the lower part of the sternum, the costochondral junction of the 6th right rib and the right humerus. B: Right posterior oblique view of the thoracic spine, showing multiple foci of increased activity in the thoracic vertebrae.

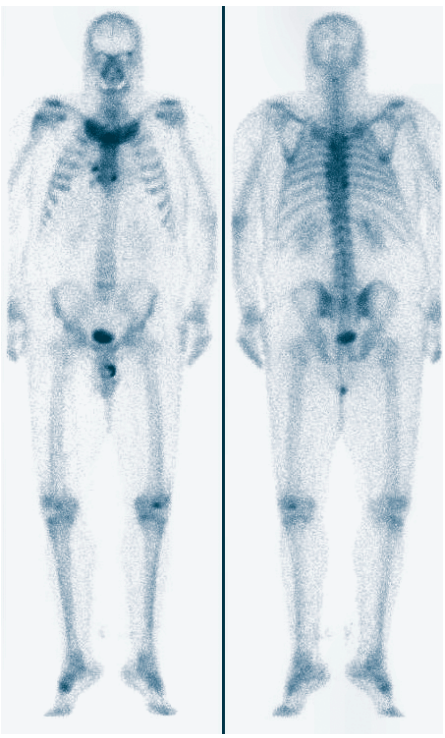

Figure 3. Bone scan of case 1 patient one year later and after treatment with pamidronate, showing vertebral lesion improvement.

increased tracer uptake in the thoracic spine (Fig. 2B), initially regarded as degenerative disease. Increased tracer uptake was also detected in the upper diaphysis of the right humerus, due to a lytic bone lesion with benign characteristics on further radiographic investigation. Patient's whole blood count was normal, and erythrocyte sedimentation rate slightly increased, 30 mm Hg. Biochemistry tests showed only an elevation of alkaline phosphatase: 158 IU/L (normal values 38-126 IU/L). No skin lesions were reported or found and treatment with non salycilate anti-inflammatory drugs (NSAID) was prescribed.

Two years later, because of bone pain localized in the anterior chest wall but most intensely in the thoracic spine, the patient was referred to us for another bone scan. Bone SPET revealed the same findings in the anterior chest wall as the first scan, but with more sternocostal and costochondral joints being involved. More extensive bone scan lesions were detected in the thoracic vertebrae T5-T7, involving mainly the body and the neck of these vertebrae. A magnetic resonance imaging scan of the thoracic spine, showed multiple vertebral body lesions of high signal intensity on both T1 and T2 weighted images, without contrast enhancement. Degenerative changes were also seen within the thoracic discs with loss of water component. Because of the extent of the bone lesions and for diagnostic purposes, a bone biopsy was performed which disclosed thickened and sclerotic bone trabeculae, with fibrotic marrow and foci of chronic inflammatory response. No pathogen was isolated from biopsy specimens.

The diagnosis of SAPHO syndrome was assumed, despite the lack of skin manifestations and the patient was scheduled to receive pamidronate treatment. The patient had a favorable clinical course with symptom remission. A bone scan repeated one year later, revealed no new findings, while the extent of the spinal lesions as well as the degree of osteoblastic activity, were reduced (Fig. 3).

Case 2

An 82 year-old man, retired farmer, was referred to our department for bone scintigraphy, for staging of prostate cancer. The patient complained of diffuse bone pain at the anterior chest wall and the sternoclavicular joints for at least 15 years, with exacerbations and remissions, treated occasionally with NSAID. No chest trauma was reported. He was pain free for the last 14 months before the present onset of pain for which he sought medical advice and thus the diagnosis of prostate cancer was made. Because of the diagnosis of prostate cancer a typical bone scan was performed for the detection of possible bone metastases. Imaging at 3 h post the i.v. injection of 740 MBq of ^{99m}Tc-MDP, revealed increased tracer uptake in the manubrium and in both sternoclavicular joints, showing the characteristic for SAPHO syndrome, 'bull's head' sign (Fig. 4). There was increased uptake in all costosternal and costochondral

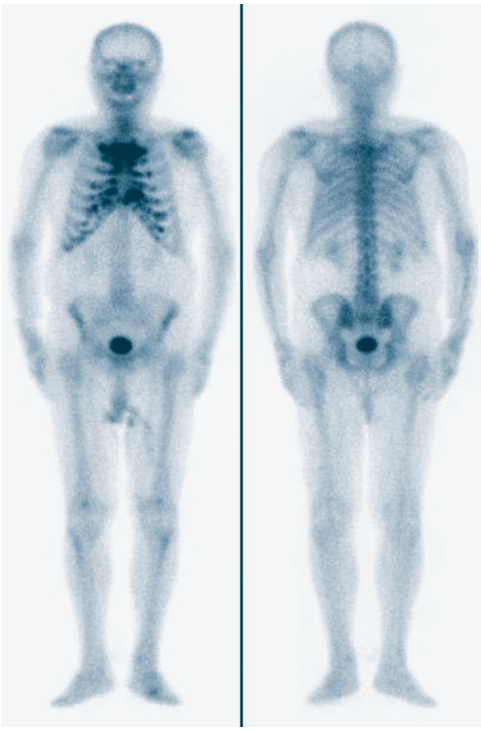

Figure 4. The whole-body bone scan of case 2 patient. There is increased tracer uptake in the manubrium, in both sternoclavicular joints ('bull's head' sign) and in all costosternal and costo-chondral joints.

joints, consistent with the above syndrome. In the rest of the skeleton there were no noticeable findings. A more detailed history and clinical examination, revealed mild edema and tenderness in both sternoclavicular joints. There were skin manifestations in the right palmar and plantar surfaces. During the last 10 years the patient suffered from a remittent palmar and plantar 'eczema', treated with local corticosteroids. A dermatologist described these skin lesions as typical palmoplantar pustulosis. White blood cells count normal. Blood biochemistry tests were normal. The patient's erythrocyte sedimentation rate was 60 mm Hg and the prostate specific antigen value was 10 ng/ml. Chest radiographs showed expansion and sclerosis of the anterior ribs and medial clavicles, with bone hypertrophy and cortical thickening most prominent in the medial end of both clavicles. Sternoclavicular hyperostosis was also profound.

The diagnosis of SAPHO syndrome was based on history, characteristic scintigraphic findings, radiological findings and skin manifestations of the disease. The patient was examined a year later. The scintiscan findings were unchanged, bone pain was mild and not consistent, and the patient was treated occasionally with NSAID. In the meanwhile only one relapse of skin manifestations was reported, treated with local corticosteroids.

Discussion

SAPHO syndrome is considered a rare entity with yet unknown prevalence. There are however indications that it is more common than initially expected, and that it is often under-diagnosed. Underestimation of the syndrome can also be inferred by the fact that the diagnosis may be delayed up to 9 years [11]. In our case 2, the syndrome was not even suspected, but only after the characteristic findings of bone scan. A detailed history is also important to identify the skin changes, as in our case 2. The difficulty in recognizing the syndrome is due to a very wide diversity of symptoms, the lack of skin manifestations in many cases and confusion in medical terminology in describing the syndrome. More than 50 different names for this syndrome have been reported [12]. Also skin and bone-articular manifestations are not necessarily parallel [13]. Absence of skin manifestation does not exclude SAPHO syndrome, since most series report skin involvement in approximately 60% of cases [14]. Our patient case 1 has not developed skin lesions to date, but had the characteristic manifestations of osteoarticular lesions in the anterior chest wall, together with evolving thoracic spine lesions. The bone scan helped in evaluation of the extent of the disease and revealed the thoracic spine involvement before significant symptoms developed. Inflammatory enteropathy can also be a feature of the syndrome [14, 15]. The most common sites of involvement are the joints of the anterior chest wall and the spine, although there are reports describing bone involvement throughout the skeleton. Bone scan is also sensitive for spine lesions but it is difficult to characterize the lesions if the characteristic pattern of the anterior wall involvement is absent. The characteristic sign of 'bull's head' is typical for SAPHO syndrome. In a study of 49 patients with the syndrome, 44 patients had the characteristic 'bull's head' sign [16]. Both our patients had this characteristic bone scan.

Case 2 is one of the oldest patients reported with this syndrome. In case 1 it is interesting, that bone scan findings were concordant with symptoms improvement, after successful treatment with bisphosphonates, that is considered nowadays the only effective treatment in SAPHO syndrome both in adults and in children [17, 18]. Because of the variety of signs and symptoms of the syndrome, its true incidence is not known, although a recent report from Japan indicates that SAPHO syndrome accounts for 4% of all patients with seronegative spondylarthropathies [19].

In conclusion, both our cases had a delayed diagnosis, AND were presented with the characteristic "bull's head" bone scan sign. Case no 1 was confirmed by a bone biopsy and had clinical and scintigraphic response to pamidronate treatment, while case no 2 had the characteristic skin findings and is one of the oldest in SAPHO syndrome cases.

Bibliography

1. Windom RE, Sanford JP, Ziff M et al. Acne conglobata and arthritis. *Arthritis Rheum* 1961; 4: 632-651.
2. Sasaki T. A case with osteomyelitis of the bilateral clavicles associated with pustulosis palmaris et plantaris. *Rinsho Sei Keigara* 1967; 2: 333-337.
3. Kormano M, Karvonen J, Lassus A. Psoriatic lesion of the sternal synchondrosis. *Acta Radiol Diagn* 1975; 16: 463-468.
4. Gideon A, Holthusen W, Masel L. Sub-acute and chronic symmetrical osteomyelitis. *Ann Radiol* 1972; 15: 329-342.

5. Bjorksten B, Gustavson KH, Erikson B et al. Chronic recurrent multifocal osteomyelitis and pustulosis palmoplantaris. *J Pediatr* 1978; 932: 227-231.
6. Chamot AM, Benhamou CL, Kahn MF et al. Le syndrome acne pustulose hyperostose osteite (SAPHO). Results d' une unquete nationale. 85 observations. *Rev Rhum* 1987; 54: 187-196.
7. Kahn MF, Kahn MA. The SAPHO syndrome. *Baillieres Clin Rheumatol* 1994; 8: 333-362.
8. Steinoff J, Kilursu A, Falasa G et al. A study of musculoskeletal manifestations in 12 patients with SAPHO syndrome. *J Clin Rheumatology* 2002; 8: 13-22.
9. Kirchhoff T, Merkesdal S, Rosenthal H et al. Diagnostic management of patients with SAPHO syndrome: use of MRI to guide bone biopsy at CT for microbiological and histological work-up. *Eur Radiol* 2003; 13: 2304-2308.
10. Suei Y, Tagushi A, Tanimoto K. Diagnostic points and possible origin of osteomyelitis in synovitis, acne, pustulosis, hyperostosis, and osteitis (SAPHO) syndrome.a radiographic study of 77 mandibular osteomyelitis cases. *Rheumatology* 2003; 42: 1398-1403.
11. Hayem G, Bouchaud-Chabot A, Benali K et al. SAPHO syndrome: along term follow up of 120 cases. *Semin Arthritis Rheum* 1999; 293: 159-171.
12. Chamot AM, Kahn MF. Das SAPHO syndrom. *Z Rheumatol* 1994; 53: 234-242.
13. Boutin RD, Resnik D. The SAPHO syndrome: an evolving concept for unifying several idiopathic disorders of bone and skin. *AJR* 1998; 170: 585-591..
14. Kahn MF, Bouvier MB, Palazzo E et al. Sternoclavicular pustulotic osteitis (SAPHO): 20 year interval between skin and bone lesions. *J Rheumat* 1991; 18: 1104-1108.
15. Skoura E, Giannopoulou C, Zaromytidou E et al. A case of non-malignant multifocal lesions on the methyl diphosphonate technetium-99m bone scan with enteropathy. SAPHO syndrome. *Hell J Nucl Med* 2007; 10: 26-28.
16. Freyschmidt J, Sternberg A. The bullhead sign: scintigraphic pattern of sternoclavicular hyperostosis and pustulotic arthroosteitis. *Eur Radiol* 1998; 8: 807-812.
17. Amital H, Applbaum Y, Aamar S et al. SAPHO syndrome treated with pamidronate: an open-label study of 10 patients. *Rheumatology* 2004; 43: 658-661.
18. Kerrison C, Davidson A, Cleary A et al. Pamidronate in the treatment of childhood SAPHO syndrome. *Rheumatology* 2004; 43: 1246-1251.
19. Hukuda S, Minami M, Saito T et al. Spondylarthropathies in Japan: nationwide questionnaire survey performed by the Japan Ankylosing Spondylitis Society. *J Rheumatol* 2001;28:555-559.