Transthyretin (Pro24Ser) variant amyloidosis: A case report of the first patient in Greece

Ioannis Panagiotopoulos[1] MD, Efstathios Papatheodorou[2] MD, Aris Anastasakis[2] MD, Eustathios Kastritis[3] MD, Polyxeni Gourzi[4] MD, Zoi Kontogeorgiou[5] MD, Georgios Koutsis[5] MD, Georgia Karadima[5] MD, Maria Koutelou[6] MD

1. Department of Cardiology, Onassis Cardiac Surgery Center, Athens, Greece
2. Department of Hereditary Diseases, Onassis Cardiac Surgery Center, Athens, Greece
3. Department of Plasma Cell Disorders, Alexandra General Hospital, Athens, Greece
4. Department of Molecular Immunopathology and Histocompatibility, Division of Molecular Genetics, Onassis Cardiac Surgery Center, Athens, Greece
5. Neurogenetics Unit, 1st Department of Neurology, Eginition Hospital, School of Medicine, National and Kapodistrian University of Athens, Athens, Greece
6. Department of Nuclear Medicine, Onassis Cardiac Surgery Center, Athens, Greece

Keywords: Amyloidosis
- Cardiac amyloidosis
- Carpal tunnel syndrome
-hATTR - Pro24Ser TTR variant

Corresponding author:
Ioannis Panagiotopoulos MD,
Onassis Cardiac Surgery Center
jpanagiotopoulos@outlook.com

Received:
7 June 2023
Accepted revised:
7 August 2023

Abstract

Objective: Transthyretin cardiac amyloidosis (ATTR-CA) is a rare and potentially fatal disease caused by the accumulation of insoluble transthyretin (TTR) amyloid fibrils in the heart. The symptoms of ATTR-CA are often non-specific, often leading to underdiagnosis. Early diagnosis and treatment have a significant impact on disease progression and mortality. **Case presentation:** In this case we report a 73-year-old male presented with dyspnea on exertion. The patient had a medical history of peripheral neuropathy, bilateral carpal tunnel syndrome, spinal fusion, and a family history of coronary artery disease. Upon his presentation at the Cardiology department, cardiac echo study revealed left and right ventricular hypertrophy with pulmonary hypertension, diastolic dysfunction and a restrictive pattern. Because of the high probability of amyloidosis, the patient underwent a technetium-99m-3,3-diphosphono-1,2-propanodicarboxylic acid (^{99m}Tc-DPD) bone scintigraphic study, which confirmed the diagnosis of ATTR-CA. Transthyretin gene sequencing analysis revealed the rare p. Pro24Ser pathogenic variant. Final diagnosis was ATTR-CA associated with the proline replaced by serine at position 24 (Pro24Ser) TTR variant, which is rare and only a few cases have been reported worldwide. The patient was treated with tafamidis and inotersen and followed up. **Conclusion:** This case highlights the importance of considering amyloidosis as a differential diagnosis for non-specific symptoms and the need for early diagnosis and management of ATTR-CA.

Hell J Nucl Med 2023; 26(2): 145-149 *Published online: 28 August 2023*

Introduction

Transthyretin cardiac amyloidosis (ATTR-CA) is an infiltrative cardiomyopathy caused by extracellular deposition of insoluble transthyretin (TTR) amyloid fibrils in the myocardium [1]. Normally, transthyretin is a protein mainly produced in the liver and functioning as a transporter of thyroxine and retinol. The result of TTR pathogenic variants are amyloid fibrils that are deposed in various organs and cause amyloidosis [2]. There are more than 120 known pathogenic variants of TTR [3], with diverse prevalence depending on population and considerable phenotypic heterogeneity [4]. Variants such as valine replaced by methionine at position 24 (Val30Met), tend to cause peripheral neuropathy more frequently, while others, like threonine replaced by alanine at position 24 (Thr60Ala), mostly lead to infiltrative cardiomyopathy [1]. Cardiac manifestations in general seem to be more severe in males [5].

Transthyretin cardiac amyloidosis signs and symptoms are often non-specific and may firstly be attributed to other causes. Transthyretin cardiac amyloidosis basically affects the heart and the peripheral nervous system. Patients with cardiac ATTR usually present with dyspnea on exertion, palpitations, or peripheral edema. Signs include elevated jugular venous pressure, changes in the electrocardiogram (ECG), diastolic dysfunction and ultimately heart failure with preserved ejection fraction (HFpEF) [2].

Diagnosis of ATTR amyloidosis can be confirmed by biopsy or imaging studies and especially nuclear scintigraphy. 3,3-diphosphono-1,2-propanodicarboxylic acid (DPD) single photon emission computed tomography (SPECT) accurately identifies amyloid load and has an excellent correlation with echo parameters and N-terminal pro-brain natriuretic peptide (NT-proBNP) in ATTR-CA [6]. However, ATTR remains under diagnosed and there is still an unmet need in disease monitoring and progression [7]. Management includes U.S. Food and Drug Administration (FDA) approved medical therapy (i.e. tafamidis) and surgery, depending on extracardiac and extranervous involvement (i.e. carpal tunnel

syndrome) [2]. Early diagnosis and treatment of amyloidosis has a significant impact on disease progression and mortality [8].

Hereditary ATTR amyloidosis is considered a rare disease and approximately 50,000 people suffer from it worldwide [9]. In particular, only a few cases of ATTR-CA associated with Pro24Ser transthyretin variant have been reported worldwide [4, 10] and only one identified in Greece [11]. Here we present the first diagnosed case in the Greek population.

Case Report

Presentation

A 73-year-old male with Asia Minor ancestry presented with dyspnea on exertion (NYHA class III).

Medical history

His medical history included erectile dysfunction (aged 61), bilateral carpal tunnel syndrome (aged 64), distal lower limb numbness (aged 66), spinal fusion for lumbar stenosis (aged 68), two episodes of surgically treated inguinal hernia. There was family medical history of coronary artery disease. One year prior to his visit on our center the patient had been investigated for symptoms of peripheral neuropathy (Stage I). Diabetes had been ruled out. Head magnetic resonance imaging (MRI) had shown non-specific findings of white matter lesions. The patient had also undergone an abdominal computed tomography (CT) scan in search of a neoplasm, as the working diagnosis at the time was paraneoplastic syndrome. However, no tumor was found. Nine months later, the patient underwent fluorine-18-fluorodeoxyglucose (^{18}F-FDG) positron emission tomography (PET)/CT study which excluded hypermetabolic sites and only revealed a small pleural effusion on the right lung. One year later and with dyspnea persisting, the patient underwent a new PET study which revealed an increase in the right pleural effusion with low-grade metabolic activity.

Status upon admission

Upon his arrival on our center, physical examination revealed normal S1 and S2 cardiac tones and leg and abdomen edema. Electrocardiogram findings were a normal axis, sinus rhythm, incomplete left bundle branch block (LBBB), qS V1-V2, negative T waves I, II, III, aVF, aVL, V5-V6, sings of LV strain (Figure 1). Cardiac echo study revealed left (concentric type) and right ventricular hypertrophy with concomitant pulmonary hypertension, (RVSP 50mmHg), EF ≥50% and diastolic dysfunction (restrictive pattern). Aortic valve was tricuspid and mitral, tricuspid and pneumonic valves were mildly regurgitant. Pericardium was free of effusion (Figure 2). At presentation, laboratory findings included TnI=0.143 ng/mL (normal range <0.056ng/mL), B-type natriuretic peptide (BNP)=230pg/mL (normal range <160pg/mL), urea 81 mg/dL, creatinine 1.34mg/dLand c-reactive protein (CRP) 1.8mg/dL (normal range <0.5mg/mL). Serum protein electrophoresis, serum protein immunoprecipitation and serum urine electrophoresis were all negative for paraproteinemia (Figure 3). Antinuclear antibodies (ANA) and antineutrophil cytoplasmic antibodies (ANCA) were within normal range. The patient also underwent a 24h rhythm Holter monitoring which revealed minimum HR=57 bmp, maximum HR=78 bpm, along with 50 ventricular and 153 supraventricular extrasystoles. There were no pauses or atrioventricular blocks.

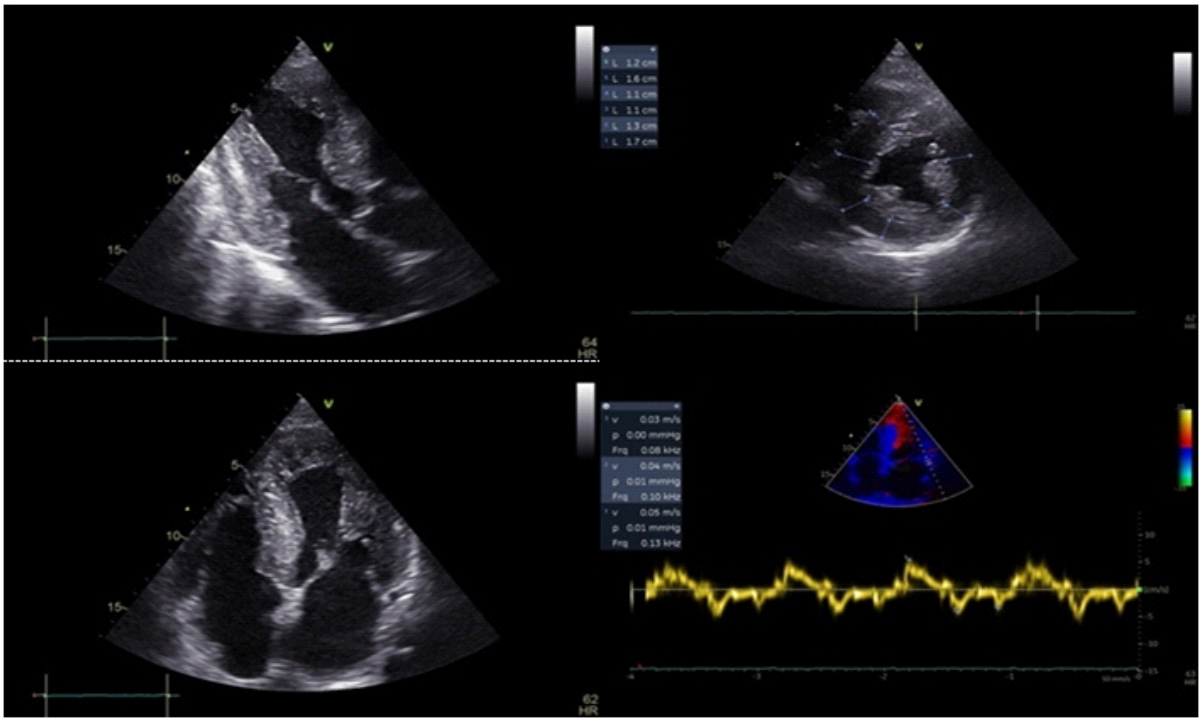

Figure 1. Ultrasound images of the patient's heart at presentation.

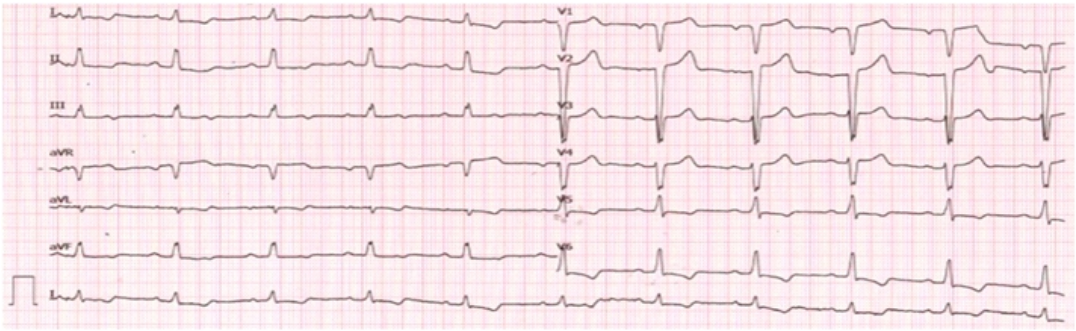

Figure 2. Patient's ECG. Negative or biphasic T waves can be seen in leads I, II, III, V5, V6.

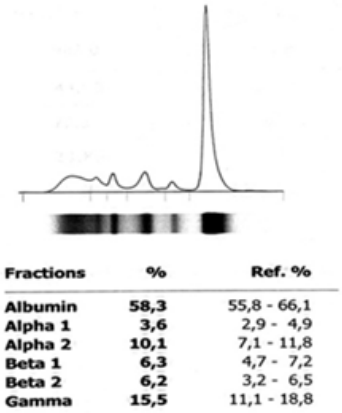

Fractions	%	Ref. %
Albumin	58,3	55,8 - 66,1
Alpha 1	3,6	2,9 - 4,9
Alpha 2	10,1	7,1 - 11,8
Beta 1	6,3	4,7 - 7,2
Beta 2	6,2	3,2 - 6,5
Gamma	15,5	11,1 - 18,8

Figure 3. Serum protein electrophoresis.

Examinations

Because of the persisting symptoms of heart failure and the peripheral neuropathy, suspicion for amyloidosis was set. The patient underwent a technetium-99m (^{99m}Tc)-DPD bone scintigraphic study 3 hours post injection (Whole body, Planar images of the thorax and myocardial SPECT imaging), which revealed increased uptake in the heart muscle (>>>ribs), indicative of ATTR-CA (grade III) according to Perugini visual score (Figure 4). Soft tissues had significant uptake, which matches bibliographic reports of ATTR amyloidosis with neurological involvement [12]. There was also uptake by the lungs. Serum protein electrophoresis showed A/G ratio 1.4 and κ/λ ratio 1.83 (normal values 0.26-1.65). Quantitatively, κ chains=23.8mg/L (normal values 3.3-19.4), λ chains=13.0mg/L (normal values 5.71-26.3). Serum immunoelectrophoresis (SIEP) showed mild IgA increase, without qualitative change. Transthyretin cardiac amyloidosis was suspected.

Diagnosis

Finally, the diagnosis was hATTR. Transthyretingene sequencing analysis revealed the rare p.Pro24Ser pathogenic variant and final diagnosis was set (Figure 5). His family members were also screened for this particular TTR variant, one of his sons was found to be an asymptomatic carrier in his forties.

Management and follow-up

The patient was initially treated with tafamidis, furosemide 20mg, eplerenone 25mg, ramipril 2.5mg, bisoprolol 1.25mg, vitamin B1 and B12, duloxetine 60mg and followed up regularly. A few months later inotersen was added to his medical therapy due to the progression of peripheral neuropathy, mainly regarding his lower limbs and his ability to walk. Because of the side effects and degradation of patient's general status, tafamidis was discontinued eight months later. Currently, peripheral neuropathy has worsened (Grade II) and an assistant device is needed for the patient to walk. The latest echocardiography assessment showed slight thickening of mitral leaflets with mild mitral valve regurgitation and thickening of the intraventricular septum, along with sparkling appearance. Speckle tracking revealed apical sparing pattern ("cherry on top" pattern). GLS was -10.3%.

Discussion

Herein, we report a patient with p.Pro24Ser TTR amyloidosis who presented to cardiologists with dyspnea on exertion, but revealed a multitude of pre-existing symptoms suggestive of neurological system involvement at presentation. His

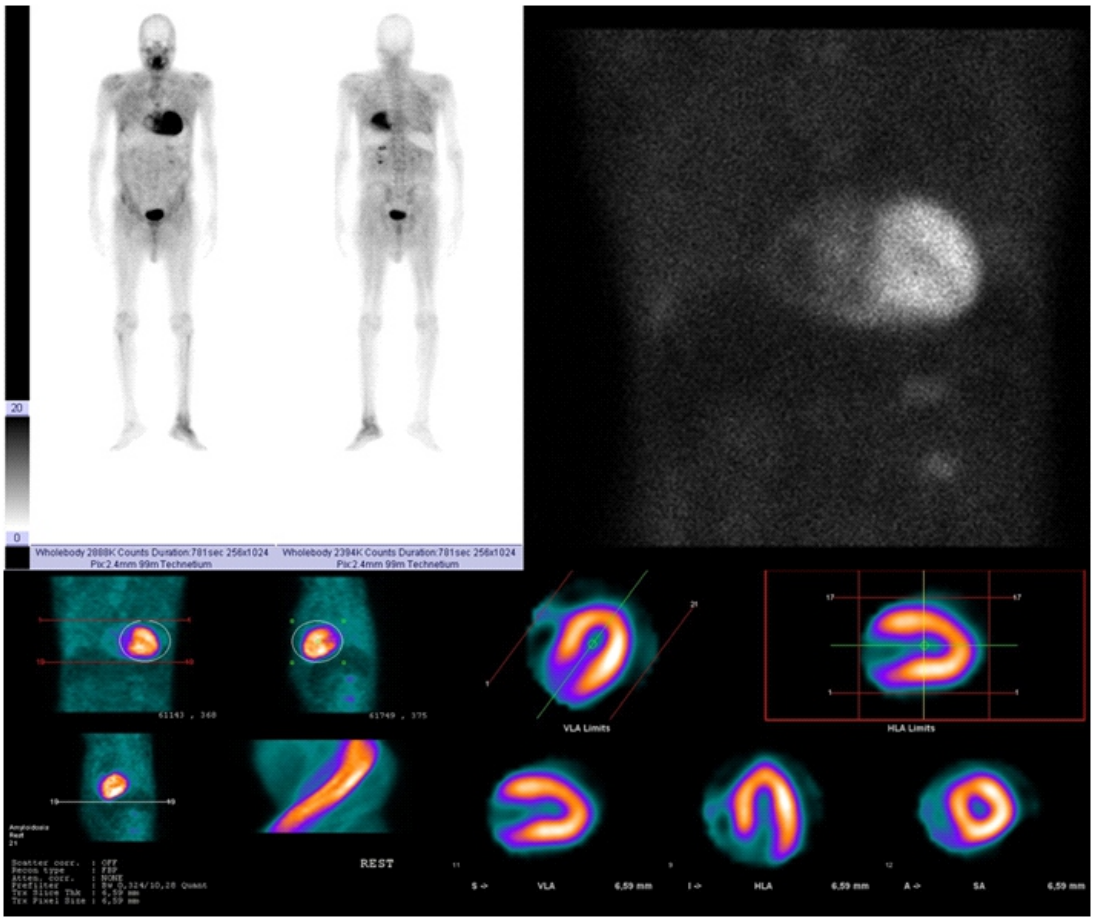

Figure 4. Technetium-99m-DPD bone scintigraphic study 3 hours post injection increased uptake in the heart muscle (>>>ribs).

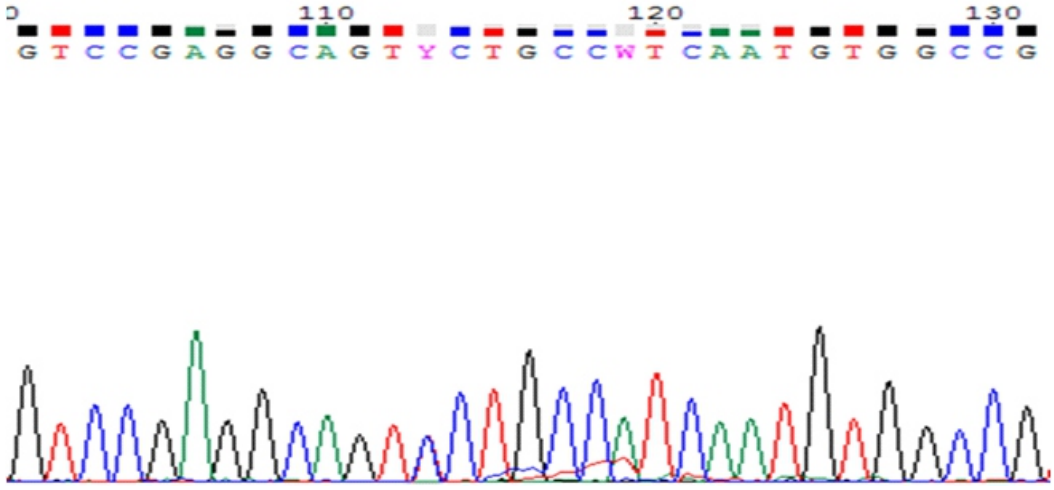

Figure 5. Gene analysis. Confirmation of c.130C>T (p.Pro44Ser) in TTR gene with Sanger.

phenotype, although typical of hATTR amyloidosis, was easy to miss if one failed to take into account the characteristic multisystem involvement. This can be the case in several multisystemic disorders, and patients tend to experience substantial delay until the definitive diagnosis. This delay may have an impact on their quality of life, as well as their life expectancy. It is important to note that cases with symptoms from both the heart and the nervous system should yield high suspicion of amyloidosis. As with the a forementioned case, ^{99m}Tc-DPD SPECT scintigraphy is extremely useful in this setting by confirming or ruling out the diagnosis in such cases fast, accurately and with minimal nuance for the patient, as opposed to other modalities like biopsy.

In conclusion, we report the first diagnosed patient in the Greek population with Pro24Ser hATTR. His symptoms are multisystemic with predominance on the nervous system. Technetium-99m DPD SPECT scintigraphy shows excellent correlation with other biomarkers in diagnosing ATTR amyloidosis.

Bibliography

1. Yamamoto H, Yokochi T. Transthyretin cardiac amyloidosis: an update on diagnosis and treatment. *ESC Heart Failure* 2019; 6(6): 1128-39.
2. Roberts J. Transthyretin-Related Amyloidosis: Practice Essentials, Back ground, *Pathophysiology* 2023.
3. Mutations in Transthyretin Gene (TTR) 2023 [Available from: http://amyloidosismutations.com/mut-attr.php.
4. Yamamoto H, Hashimoto T, Kawamura S et al. Hereditary cardiac amyloidosis associated with Pro24Ser transthyretin mutation: a case report. *J Med Case Rep* 2018; 12(1): 370.
5. Caponetti AG, Rapezzi C, Gagliardi C et al. Sex-Related Risk of Cardiac Involvement in Hereditary Transthyretin Amyloidosis: Insights From THAOS. *JACC: Heart Failure* 2021; 9(10): 736-46.
6. Löfbacka V, Axelsson J, Pilebro B et al. Cardiac transthyretin amyloidosis ^{99m}Tc-DPD SPECT correlates with strain echocardiography and biomarkers. *Eur J Nucl Med Mol Imaging* 2021; 48(6): 1822-32.
7. Adams D, Algalarrondo V, Polydefkis M et al. Expert opinion on monitoring symptomatic hereditary transthyretin-mediated amyloidosis and assessment of disease progression. *Orphanet J Rare Dis* 2021; 16(1): 411.
8. Ioannou A, Patel RK, Razvi Y et al. Impact of Earlier Diagnosis in Cardiac ATTR Amyloidosis Over the Course of 20 Years. *Circulation* 2022; 146 (22): 1657-70.
9. Waddington-Cruz M, Ackermann EJ, Polydefkis M et al. Hereditary transthyretin amyloidosis: baseline characteristics of patients in the NEURO-TTR trial. *Amyloid* 2018; 25(3): 180-8.
10. Uemichi T, Gertz MA, Benson MD. A new transthyretin variant (Ser 24) associated with familial amyloid polyneuropathy. *J Med Genet* 1995; 32(4): 279-81.
11. Koutsis G, Kastritis E, Kontogeorgiou Z et al. Variant transthyretin amyloidosis (ATTRv) polyneuropathy in Greece: a broad overview with a focus on non-endemic unexplored regions of the country. *Neuromuscul Disord* 2021; 31(12): 1251-8.
12. Wollenweber T, Kretschmer-Chott E, Wurm R et al. Does [^{99m}Tc]-3,3-diphosphono-1,2-propanodicarboxylic acid (DPD) soft tissue uptake allow the identification of patients with the diagnosis of cardiac transthyretin-related (ATTR) amyloidosis with higher risk for polyneuropathy? *J Nucl Cardiol* 2023; 30: 357-67.