Diagnostic compatibility of V/Q SPECT and CTPA, which are non-invasive diagnostic methods, for the detection of CTEPH, which is a treatable cause of pulmonary hypertension

Farise Yilmaz[1] MD, Abdullah Tunçez[2] MD, Hasan Önner[1] MD, Gonca Kara Gedik[1] MD, Emine Uysal[3] MD, MusluKazım Körez[4] PhD

1. SelcukUniversity Medical Faculty, Department of Nuclear Medicine, Konya
2. Selcuk University Medical Faculty, Department of Cardiology, Konya
3. SelcukUniversity Medical Faculty, Department of Radiology, Konya
4. Selcuk University Medical Faculty, Department of Biostatistics and Medical Informatics, Konya

Keywords: Chronic thromboembolic pulmonary hypertension - Ventilation/perfusion scintigraphy - CTPA - Pulmonary hypertension

Corresponding authors:
Farise Yılmaz MD,
Associate Professor of Nuclear Medicine
Selcuk University Medical Faculty,
Department of Nuclear Medicine,
Konya, Turkey
Tel: +903322244077
Fax: +903322416065
drfarise@hotmail.com

Received:
4 April 2022
Accepted revised:
30 June 2022

Abstract

Objective: To evaluate the compatibility between ventilation/perfusion (V/Q) single photon emission computed tomography (SPECT) scintigraphy and computed tomography pulmonary angiography (CTPA) in diagnosing chronic thromboembolic pulmonary hypertension (CTEPH). **Subjects and Methods:** Twenty cases of CTEPH, out of 98 patients with pre-diagnosis of pulmonary hypertension (PH), who was diagnosed with CTEPH with a multidisciplinary approach and a council decision, were included in the study retrospectively. The diagnostic performances of V/Q SPECT and CTPA, which are used as noninvasive methods in diagnosing CTEPH, and the compatibility between them were calculated statistically. **Results:** Of 20 patients diagnosed with CTEPH, 12 were female, and 8 were male; the mean age was 59.1 (range: 36-79). The sensitivity of V/Q SPECT scintigraphy of imaging methods used to diagnose CTEPH was 90%, CTPA was 80%, specificities were 88% and 92%, respectively, and accuracy was 88% in both cases methods. According to the reference standard, the kappa value for V/Q scintigraphy was calculated as 0.765 and 0.678 for CTPA. These values were statistically significant (P<0.01), and there was a substantial concordance between them. **Conclusions:** There is significant compatibility between V/Q SPECT scintigraphy and CTPA in diagnosing CTEPH, whose differential diagnosis is essential because of its high cure potential due to PH causes.

Hell J Nucl Med 2022; 25(2): 168-176 *Epub ahead of print: 3 August 2022* *Published online: 29 August 2022*

Introduction

Chronic thromboembolic pulmonary hypertension (CTEPH) is a disease classified in group IV of the causes of pulmonary hypertension (PH), which results in pulmonary hypertension as a result of fibrotic thrombus formation in the pulmonary vessels and increased pulmonary vascular resistance [1, 2]. According to The Fifth World Symposium on Pulmonary Hypertension, PH is divided into five groups: Type I, pulmonary arterial hypertension (PAH); Type II, PH due to left heart disease; Type III, PH due to lung disease; Type IV, chronic thromboembolic PH (CTEPH); Type V, a miscellaneous group of PH with unclear or multifactorial mechanisms [3].

For the diagnosis of CTEPH, it is necessary to detect resting pulmonary artery pressure (PAP) of 25mmHg and above with right heart catheterization, pulmonary arterial wedge pressure less than or equal to 15mmHg, and pulmonary vascular resistance (PVR) greater than 3 wood units, despite optimal anticoagulant treatment for at least 3 months after an acute pulmonary embolism, and to detect mismatch segmental perfusion defect in ventilation/perfusion scintigraphy and chronic thromboembolism findings by computed tomography pulmonary angiography (CTPA) [4]. Although the incidence of CTEPH varies between 2% and 4% after an acute pulmonary embolism, a significant number of CTEPH cases develop in the absence of acute pulmonary embolism history. Therefore, CTEPH should be considered in any patient with unexplained PH [5-9]. The importance of differential diagnosis of CTEPH from other PH causes is the high potential for cure with surgical treatment in patients with CTEPH [10].

Invasive PA is considered the gold standard in diagnosing acute or chronic emboli, but non-invasive methods are preferred today. Thus, ventilation/perfusion (V/Q) scintigraphy is recommended as a first-line modality in diagnostic algorithms [11]. At least one segmental mismatched perfusion defect (areas where perfusion is impaired and ventilation is preserved) may be sufficient for diagnosing CTEPH. At the same time, normal findings may

practically exclude the diagnosis of CTEPH [12]. However, pathological lesions that may mimic thromboembolism in V/Q scintigraphy (pulmonary artery tumors, fibrous mediastinitis, fibrosis secondary to radiotherapy, vasculitis, etc.) may lead to false-positive interpretation. Computed tomography pulmonary angiography provides a closer look into the pulmonary arteries, collaterals, lung parenchyma, and mediastinal structures. However, evaluation of thromboembolism in the distal arteries often leads to false-negative interpretations. For this reason, perfusion disorders at the subsegmental level cannot be evaluated most of the time.

Although V/Q single photon emission computed tomography (SPECT) scintigraphy in the diagnosis of CTEPH was initially recommended as a screening test due to its high sensitivity in the differential diagnosis of causes of PH, we aimed to evaluate the diagnostic performance and compatibility of its evaluation with CTPA to have the potential for surgical cure in CTEPH and to save time in the diagnosis process.

Subjects and Methods

Patients

Ninety-eight patients who underwent V/Q SPECT scintigraphy with a preliminary diagnosis of PH in our institution between January 2015 and May 2020 were retrospectively analyzed. Patients were evaluated with the CTEPH diagnostic algorithm published in the 2015 ESC/ERS guideline for the diagnosis and treatment of pulmonary hypertension [11]. Patients with mean pulmonary artery pressure (mPAP) above 25mmHg with transthoracic echocardiography or right heart catheterization and patients with a maximum interval of two weeks between V/Q SPECT scintigraphy and CTPA were included in the study. Twenty-nine patients who did not meet these criteria were excluded.The council decisions of the remaining 69 patients, taken with a multidisciplinary approach, were analyzed. These decisions were used as a reference method for our study(council: consists of cardiology-cardiovascular surgery-chest diseases-radiology and nuclear medicine departments). In addition, clinical and laboratory data (D-dimer, invasive pulmonary angiography, etc.) of these patients were obtained from the internet address of the hospital or general health information system (https://enabiz.gov.tr).The study protocol was approved by the local institutional ethics committee decision (no.2020-225).

V/Q SPECT scintigraphy protocol

A two-day protocol was applied for V/Q scintigraphy. Ventilation scintigraphy was performed the day after perfusion. Perfusion SPECT and then ventilation SPECT (128, 360° each for 12 seconds) images were taken on the patients. A MedisoAnyscan S (Mediso Medical Diagnostics Equipment, Budapest, Hungary) low energy high resolution (LEHR) collimator (140keV, 20% window gap) and dual detector gamma camera were used for planar and SPECT images. For perfusion, technetium-99m (^{99m}Tc)-macro aggregated albumin (MAA) 4-5 millicurie (mCi) (148-185 megabecquerel)(MBq) was given intravenously slowly. In a supine position, 300.000 counts per visual were obtained with a 256x256-pixel matrix in six projections (anterior, posterior, left and right posterior oblique, and left and right anterior oblique). Ventilation was evaluated on the 2nd day. With the "TechnegasPlus" generator (Cyclomedica Australia Pty Ltd., Australia), 12-15mCi (444-555MBq) ^{99m}Tc was given to patients by inhalation, and images were taken with the same methods as perfusion. The mean radiation dose received by the patient with V/Q scintigraphy ranged from 1.2 to 2mSv (millisievert) [14]. The images were analyzed under "Gestalt Principles" by two nuclear medicine specialists with 10 and 12 years of experience, unaware of the CTPA results. In controversial cases, opinions were exchanged between the two physicians, and a consensus was reached. The diagnosis of pulmonary embolism (PE) was made according to the 2019 European Nuclear Medicine Association (EANM) guideline, as "the areas where perfusion is reduced completely or significantly but ventilation is preserved were interpreted as mismatch defect" [15]. At least one segmental or two subsegmental mismatch perfusion defects compatible with pulmonary vascular anatomy were evaluated as positive for PE, and reverse mismatch defects matching normal perfusion patterns were considered negative. Defects that did not match the vascular distribution of the lung were defined as non-segmental or non-diagnostic.

CTPA protocol

Vascular access was established through an 18G catheter in the right antecubital vein. All shots were taken with a 128 detector CT device (Somatom Definition Flash, Siemens Medical Solutions, Germany). Computed tomography examination was performed with the patient in the supine position and holding both arms above the head level to prevent artifact formation. Acquisition parameters were set as 100 kVp, 125mAs, 0.6mm collimation, pitch value as 1.0, gantry turn time as 0.28sec, and slice thickness as 1mm. Images were acquired during inspiration or, for uncooperative patients, during shallow breathing in the craniocaudal direction. Computed tomography scan was started 7 seconds after the contrast agent injection started. Radiologists interpreted the evaluation of the images with at least eightyears of radiology experience and were unaware of the results of V/Q scintigraphy. In these evaluations, reformat images in the coronal and sagittal planes, and axial source images were examined using standard window width and level (soft tissue, 400 and 40HU; pulmonary embolism, 450 and 100 HU; lung, 1500 and -600). Pulmonary embolism: thrombus, calcified thrombus, recanalization, sudden change in vessel caliber, strictures, dilatation, or perfusion abnormalities after stenosis was recorded as "defect compatible with CTE (chronic thromboembolism)."

Statistical analysis

All statistical analysis was performed using R version 3.6.0 (The R Foundation for Statistical Computing, Vienna, Austria; https://www.r-project.org). A P-value less than 5% was considered statistically significant. The Cohen's kappa coeffici-

ent (κ) with a 95% confidence interval was calculated to assess the agreement between V/Q scintigraphy and CTPA methods in diagnosing CTEPH. Kappa was used to define the level of agreement obtained: κ<0 poor agreement; 0.01-0.20, slight agreement; 0.21-0.40, fair agreement; 0.41-0.60, mo-derate agreement; 0.61-0.80, substantial agreement; 0.81-1.00, almost agreement. The sensitivity, specificity, positive (PPV) and negative (NPV) predictive values, positive (LR+) and negative (LR-) likelihood ratios, accuracy, and proportion of false-positive and negative values were computed to evaluate the diagnostic performance of the V/Q scintigraphy and CTPA methods in identifying patients with CTEPH. The sensitivity and specificity values of the methods were compared with the McNemar test, and also negative and positive predictive values were compared with Weighted generalized score statistics. The confidence intervals were calculated via Clopper-Pearson method.

Results

It was determined that 20 of 69 patients were diagnosed with CTEPH by the council. Of 20 patients diagnosed with CTEPH (Type IV PH), 12 were female, and 8 were male. The mean age was 59.1(range:36-79, SD:15.1). Right heart catheterization (RHC) was performed in all 20 patients, and the mean mPAP was 63.9±16.6mmHg. The PVR values of these patients were obtained, and the mean value was calculated as 7.89±4.70 Wood Unıt. Invasive pulmonary angiography was performed in 12 patients during RHC, and chronic thrombus, vessel occlusion, or web-like lesion formations were detected as the cause of obstruction. The mean D-Dimer of patients with CTEPH was calculated as 1133.98±1298.48 ng/dL. Pulmonary endarterectomy (PEA) was recommended to 8 of these patients, but 4 refused the treatment and received medical treatment. The remaining four patients (21%) were referred to a specific and experienced center for PEA, and PEA was performed. Riociguat (guanylate cyclase stimulator), the only licensed drug for CTEPH, was started in 16 patients (80%). In 4 of 20 patients, CTPA was interpreted as normal, and V/Q scintigraphy was considered a mismatch defect compatible with pulmonary thromboembolism. And in 2 patients, V/Q scintigraphy was interpreted as a match defect, and the CTPA of these patients was evaluated as consistent with chronic thromboembolism (CTE) (Table 1). Distribution of other PH patients diagnosed with the council; Type I PH:33, Type II PH:7, Type III PH:8, Type V PH :1 (Table 2).Mismatch perfusion defect in the scintigraphy of 5 of 33 patients in the type 1PH group and chronic thromboembolism in 3 patients were noted. Although the findings of 2 patients were compatible with the diagnosis of CTEPH, they were diagnosed with type 1 PH.

Regarding the diagnostic performance, V/Q SPECT scintigraphy was found to have a sensitivity of 90 (68-99), with a positive predictive value of 75 (53-90), and have a specificity of 88 (75-95), with a negative predictive value of 96 (85-99) to detect a CTEPH. The diagnostic accuracy was 88 (78-95), with a proportion of false-positive of 12 (5-25) and a proportion of false-negative of 10 (1-32). Computed tomography pulmonary angiography was found to have a sensitivity of 80 (56-94), with a positive predictive value of 80 (56-94), and have a specificity of 92 (80-98), with a negative predictive value of 98 (80-98) to detect a CTEPH. The diagnostic accuracy was 88 (78-95), with a proportion of false-positive of 8 (2-20) and a proportion of false-negative of 20 (6-44). There was no statistically significant difference between the AUC (Z=0.455, P=649), sensitivity (McNemar χ^2=0,067, P=0.414), specificity (McNemar χ^2=1,001, P=0.317), positive predictive value (Wald=0.444, P=0.504), negative predictive value (Wald=0,578, P=0.447) positive likelihood ratio (LR=0.75, P=0.506), negative likelihood ratio (LR=0.523, P=0.455) between the V/Q scintigraphy and CTPA methods to diagnose a CTEPH (Figure 3). Cohen's kappa (κ) was computed to assess the agreement between the reference standard and V/Q and CTPA in diagnosing the CTEPH. The kappa value was 0.734 (95% CI, 0.563-0.905), which suggests a substantial agreement between the reference standard and V/Q scintigraphy, and this value of kappa is significantly different from zero (Z=6.150, P<0.001). The kappa value was 0.718 (95% CI, 0.536-0.900), which suggests a substantial agreement between the reference standard and CTPA, and this value of kappa is significantly different from zero (Z= 5.970, P<0.001). Moreover, the agreement levels of the V/Q SPECT scintigraphy and CTPA methods for diagnosing the CTEPH were similar, as the confidence intervals for the kappa values overlapped (Table 3). Representative situations are shown in Figures 1 and 2.

Discussion

Ventilation/perfusion, SPECT scintigraphy, and CTPA provide information about the obstruction of vascular structures in the lung. While CTPA shows the thrombus directly, V/Q scintigraphy indirectly indicates the area affected by the thrombus by defining it as a mismatch defect. CTPA can also provide information about bronchial arteries, parenchyma, and mediastinum [16].

Ventilation/perfusion scintigraphy is recommended as a screening test rather than radiological methods at the first stage in diagnostic algorithms because normal V/Q scintigraphy can exclude CTEPH (high negative predictive value) and exposes patients to lower radiation doses and has no contrast effect. However, V/Q scintigraphy alone may not be sufficient since different pathologies may mimic the scintigraphic findings of obstruction in the diagnosis.

Although many publications in the literature compare these two methods in diagnosing acute pulmonary embolism, it is minimal in CTEPH [17, 18]. In our study, we compared the two imaging methods, using the reference method for patients with a pre-diagnosis of PH who were diagnosed with CTEPH with the decision of the council, we obtained the following results in V/Q scintigraphy; sensitivity was 90%, specificity was 88%, PPV was 75%, and NPV was 96% and the following results in CTPA; sensitivity was 80%, specificity was 92%, PPV was 80%, and NPV was 98%. The difference between these values was not significant (P>0.01). However, the Kappa value being different from zero for both

Table 1. *Characteristics of patients diagnosed with CTEPH participating in the study.*

	Sex	Age	mPAP (mmHg)	PVR (WU)	D-dimer	İnvasive PA	SPECT V/Q	CTPA	Treatment
1	M	45	50	13,10	492	+	MM	CTE	Medical
2	F	36	55	9,20	1577	NR	MM	CTE	Medical
3	F	47	76	11,60	389	NR	MM	CTE	Medical
4	M	57	66	21	985	+	MM	CTE	Medical
5	M	72	80	4,30	354	+	MM	CTE	Medical
6	M	52	73	7,75	800	+	MM	CTE	Medical
7	F	47	47	4,50	858	+	MM	CTE	Medical
8	M	79	65	5,80	1046	NR	MM	CTE	Medical
9	M	41	40	2,45	5500	+	M	CTE	PEA
10	F	60	100	3,42	463	+	MM	CTE	Medical
11	F	43	45	1,42	153	+	MM	CTE	PEA
12	M	44	85	7,80	100	NR	MM	CTE	PEA
13	M	76	95	7,42	2139	+	MM	N	Medical
14	F	46	105	15	361	+	MM	CTE	Medical
15	F	50	95	10,5	1440	+	MM	CTE	Medical
16	F	75	65	6,75	355	NR	MM	N	Medical
17	F	43	75	8,50	330	NR	MM	CTE	Medical
18	F	65	50	3,80	982	+	MM	N	PEA
19	F	66	70	4,80	1040	NR	M	CTE	Medical
20	F	67	76	8,85	1301	NR	MM	N	Medical

MM: Mismatch, M: Match, CTE: Chronic Thromboembolism, N: Normal, NR: Not Reached, PEA: pulmonary endarterectomy, M: Male, F: Female

Table 2. *Distribution and clinical features of patients with other PH.*

PH type I	PH type I	PH type II	PH type III	PH type VI	PH type V
Total number	33	7	8	20	1
Female	25	7	8	12	1
Male	8	0	0	8	0
Age (mean-SD)	59.2±15.3	60.3±14.9	60.1±15.5	59.1±15.1	62
mPAP (mmHg)			65.1±16.9	63.9±16.6	42
mD-dimer		3202.22	1137.23	1133.98	254
RHC	31	2	-	20	-
MM-V/Q	5	-	-	18	-
CTE-CTPA	3	-	-	16	-

PH: Pulmonary Hypertension, RHC: Right Heart Catheterization, MM-V/Q: Mismatch defect in Ventilation/Perfusion scintigraphy, CTE-CTPA: Chronic Thromboembolism in Computed Tomography Pulmonary Angiography mPAP: mean pulmonary artery pressure, mD-dimer: mean D-dimer

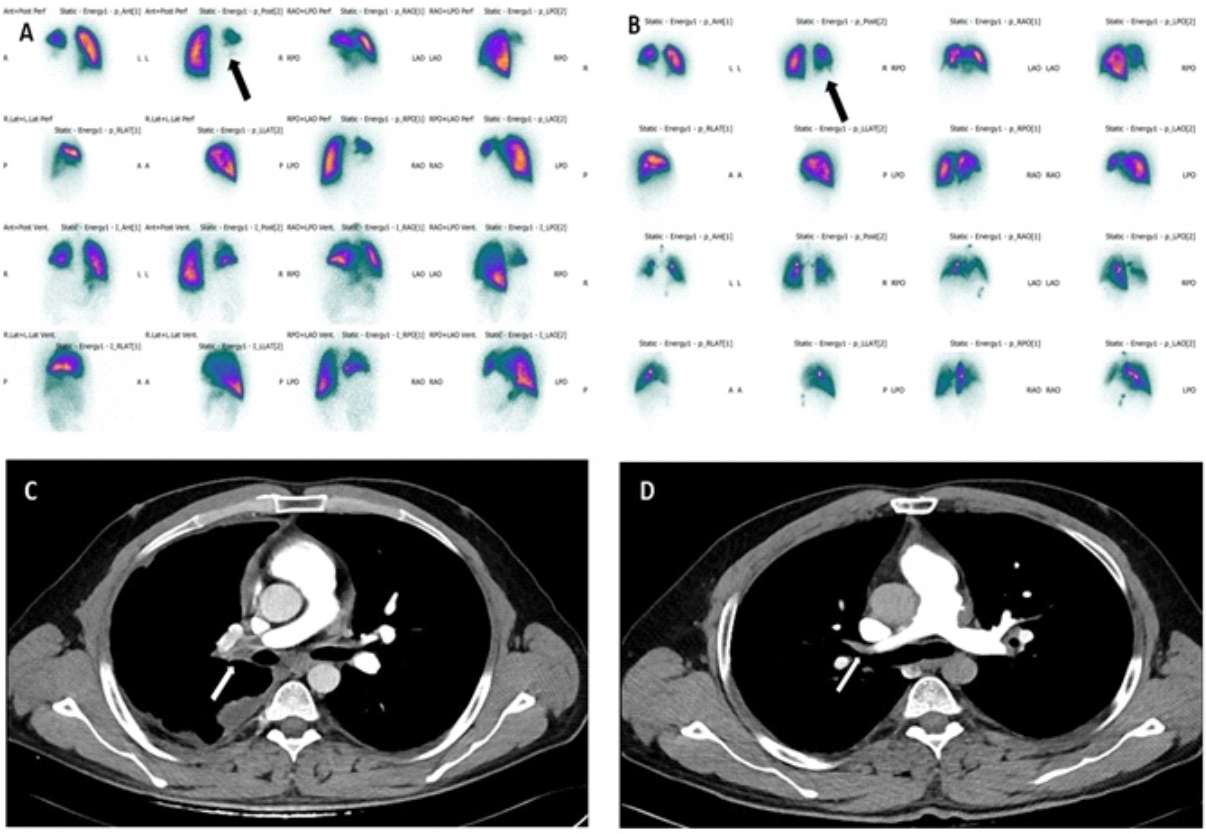

Figure 1. Pre and postoperative V/Q planar images (A: preoperative mismatch defect, B: postoperative match defect, black arrow) and CTPA (C: thrombus showing filling defect in the right main and interlobar artery of the right lung, D: normal flow after PEA in the right main pulmonary artery, white arrow) of a patient with CTEPH who underwent PEA surgery.

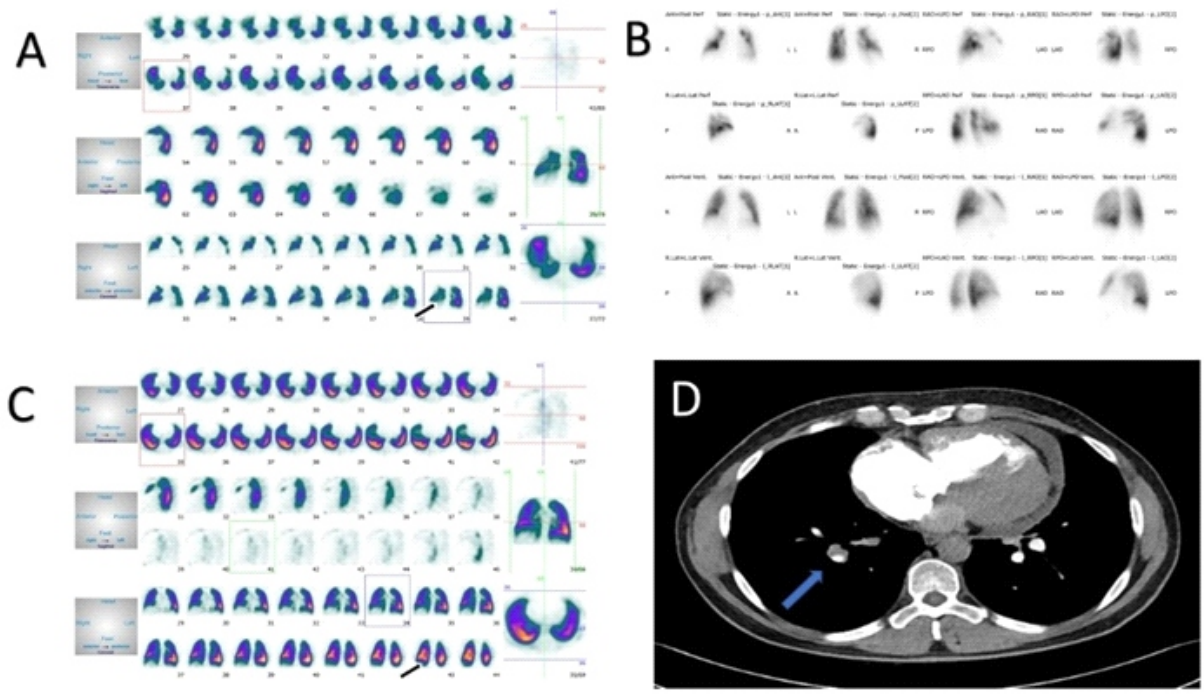

Figure 2. Ventilation/perfusion (V/Q) single-photon emission computerized tomography (SPECT) in A, B, C images and 'mismatched' perfusion defect in the lower lobe of the right lung (black arrow) (A, SPECT perfusion, B, planar ventilation/perfusion, C, ventilation SPECT) and D, CTPA (computed tomography pulmonary angiography) image of the thrombus showing a filling defect allowing partial passage in the right lung lower lobe segmentary artery (blue arrow).

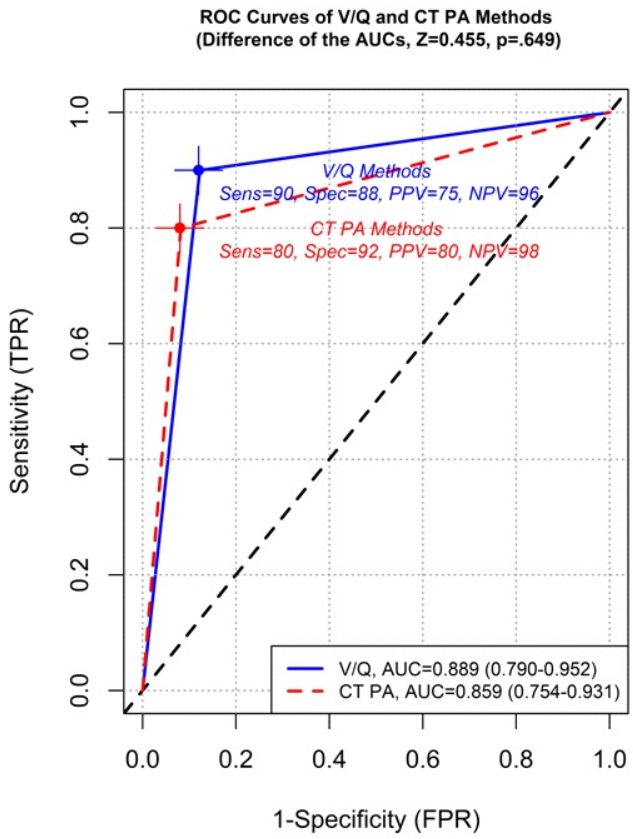

Figure 3. Sensitivity and specificity with ROC curve.

Table 3. *The confusion matrix, statistical diagnostic measures and agreement statistics of the V/Q scintigraphy and CTPA methods to diagnose the CTEPH.*

	V/Q SPECT		CTPA		
	CTEPH	NoCTEPH	CTEPH	NoCTEPH	Total
CTEPH	18	2	16	4	20 (29)
No CTEPH	6	43	4	45	49 (71)
Total	24(34.8)	45(65.2%)	20(29)	49 (71%)	
Statistical diagnostic measures (%)					
AUC (95% CI)	0.889 (0.790-0.952)		0.859 (0.754-0.931)		P=0.649[1]
Sensitivity, (95% CI)	90 (68-99)		80(56-94)		P=0.414[2]
Specificity (95% CI)	88 (75-95)		92 (80-98)		P=0.317[2]
PPV, (95% CI)	75 (53-90)		80(56-94)		P=0.504[3]
NPV, (95% CI)	96 (85-99)		98 (80-98)		P=0.447[3]
LR+, (95% CI)	7.35 (3.42-15.77)		9.80 (3.74-25.71)		P=0.506
LR – (95% CI)	0.11 (0.03-0.48)		0.22 (0.09-0.53)		P=0.455
Accuracy (95% CI)	88 (78-95)		88 (78-95)		
Prop. of false positive, (95% CI)	12 (5-25)		8 (2-20)		
Prop. of false negative, (95% CI)	10 (1-32)		20 (6-44)		
Agreement statistics					
κ, (95% CI)	0.734 (0.563-0.905)		0.718 (0.536-0.900)		

[1] DeLong's test, [2] McNemar test, [3] Weighted generalized score test, PPV: positive predictive value, NPV: negative predictive value, LR+: positive likelihood ratio, LR –: negative likelihood ratio, 95% CI: 95% confidence interval, V/Q SPECT: ventilation-perfusion Single Photon Emission Computed Tomography, CTPA: Computed Tomography pulmonary angiography, CTEPH: chronic thromboembolic pulmonary hypertension, κ: Cohen's kappa coefficient.

examinations (VQ: 0.765 and CTPA: 0.678) and this difference being significant (P<0.001) showed that there was a substantial concordance between the two methods. Wang et al. (2020) compared V/Q scintigraphy and CTPA, which took prospective and digital subtraction angiography (DSA) as a reference and found high sensitivity in both of them in diagnosing CTEPH. While there was no significant difference between them in the diagnosis, similar to ours, they found V/Q scintigraphy more sensitive in detecting pulmonary artery obstructions at the segmental level [19]. Invasive pulmonary angiography was used as the reference value in another prospective study. The sensitivity was 100% and 92.2%. The specificity was 93.7% and 95.2%, and the kappa values were 0.787 and 0.806 in V/Q and CTPA, respectively. They concluded a significant level of concordance between the two tests for diagnosing CTEPH, similar to our study [20].

Among the previous studies, Tunariu et al. (2007) retrospectively evaluated 78 patients with CTEPH, compared V/Q with CTPA, and found the sensitivity as 96.2% and 51.5%, and the specificity as 94.6% and 99.3% for V/Q and CTPA, respectively [13].The lower sensitivity results for CTPA from the recent studies, including ours, in the literature may be related to the old technological features of CT.

Soler et al. (2012) compared SPECT V/Q and CTPA to identify obstructive and non-obstructive segments in a pilot study using 12 patients undergoing pulmonary endarterectomy (PEA) and using surgical specimen and PA as a gold standard, and SPECT V/Q (62% vs. 48%) was more sensitive in detecting obstructive segments, and this result was statistically significant (P=0.03). There is no statistically significant difference between the two in specificity [21]. In a retrospective study conducted with 49 patients who underwent PEA, Grigic et al. (2016) suggested that both methods should be interpreted correctly and used to distinguish between operable and non-operable patients for CTEPH [22]. In a recent study investigating the contribution of the quantitative analysis of segmental defects with SPECT V/Q scintigraphy to the preoperative risk assessment of patients diagnosed with CTEPH, 87% sensitivity, 82% specificity, and 84% accuracy rates were found to be similar to our study in diagnosis. They also suggested that it could be used as a noninvasive imaging method [23].

In our study, a matching perfusion defect was detected in 2 patients with CTEPH. In a recent study, they compared SPECT/CT with a computer program that quantitatively evaluates perfusion (V/Q Quotient SPECT) for the diagnosis of CTEPH and found that V/Q SPECT/CT had high sensitivity and specificity. However, a match perfusion defect (diagnosis of CTEPH was confirmed by surgical specimen) was noted in 6 CTEPH patients. This situation occurred because of the increase in perfusion by recanalization of chronic thrombus, as in the literature and our cases, or because the lung responded with hypoventilation to chronic hypoperfusion caused by thrombus [24-26]. Ventilation/perfusion SPECT isinterpreted as false-negative about the mechanisms mentioned above. In CTPA, structural defects in the pulmonary artery or emboli in the distal pulmonary artery branches are not noticed (perfusion defects at the subsegmental level). Therefore, the compatibility and complementarity of V/Q SPECT scintigraphy and CTPA in diagnosing CTEPH are very important.

In recent years, MR studies have been carried out by suggesting that they will be exposed to less iodinated radiation as an alternative to V/Q scintigraphy, and although the sensitivity was 100% (SPECT-Q; 97%), the specificity was 81% (SPECT-Q; 81%); there was no statistically significant difference between them [27, 28]. Because the MR technique is expensive and difficult to use as a screening test in practice, it is challenging to replace V/Q scintigraphy.

In the 2015 ESC/ERS guideline and the literature, it was reported that mismatch perfusion defects could be seen in the type 1 PH group. It was emphasized that caution should be exercised when making the differential diagnosis. In our study, mismatch perfusion defect in V/Q scintigraphy and chronic thromboembolism findings in CTPA were observed in 2 patients with type 1 PH. Still, differential diagnosis was made with CTEPH, and they were included in the type 1 PH group [11, 29].

Limitations of our study include the inability to perform pulmonary angiography in all patients, the small number of patients to evaluate both methods, the retrospective nature of the study, and the acquisition of patients from a single center. Studies to be conducted to diagnose CTEPH will contribute more to this issue.

In conclusion, there is significant compatibility between V/Q SPECT scintigraphy and CTPA in the diagnosis of CTEPH, whose differential diagnosis is essential because of its high cure potential due to PH causes.

Bibliography

1. Fernandes T, Planquette B, Sanchez O, Morris T. From Acute to Chronic Thromboembolic Disease. *Ann Am Thorac Soc* 2016;13 Suppl 3: S207-S214.
2. Lang I. Chronic thromboembolic pulmonary hypertension: a distinct disease entity. *Eur Respir Rev* 2015; 24(136): 246-52.
3. Masy M, Giordano J, Petyt G et al. Dual-energy CT (DECT) lung perfusion in pulmonary hypertension: concordance rate with V/Q scintigraphy in diagnosing chronic thromboembolic pulmonary hypertension (CTEPH). *Eur Radiol* 2018; 28(12): 5100-10.
4. Albani S, Biondi F, Stolfo D et al. Chronic thromboembolic pulmonary hypertension (CTEPH): what do we know about it? A comprehensive review of the literature. *J Cardiovasc Med (Hagerstown)* 2019; 20(4): 159-68.
5. O'Connell C, Montani D, Savale L et al. Chronic thromboembolic pulmonary hypertension. *Presse Med* 2015; 44 (12 Pt 2): e409-e416.
6. Berghaus TM, Barac M, von Scheidt W, Schwaiblmair M. Echocardiographic evaluation for pulmonary hypertension after recurrent pulmonary embolism. *Thromb Res* 2011; 128(6): e144-e147.
7. Klok FA, van Kralingen KW, van Dijk AP et al. Prospective cardiopulmonary screening program to detect chronic thromboembolic pulmonary hypertension in patients after acute pulmonary embolism. *Haematologica* 2010; 95(6): 970-5.
8. Miniati M, Monti S, Bottai M et al. Survival and restoration of pulmonary perfusion in a long-term follow-up of patients after acute pulmonary embolism. *Medicine (Baltimore)* 2006; 85(5): 253-62.
9. Pengo V, Lensing AW, Prins MH et al. Incidence of chronic thromboembolic pulmonary hypertension after pulmonary embolism. *N Engl J Med* 2004; 350(22): 2257-64.
10. Moradi F, Morris TA, Hoh CK. Perfusion Scintigraphy in Diagnosis and Management of Thromboembolic Pulmonary Hypertension. *Radiographics* 2019; 39(1): 169-85.
11. Galiè N, Humbert M, Vachiery JL et al. 2015 ESC/ERS Guidelines for the diagnosis and treatment of pulmonary hypertension: The Joint Task Force for the Diagnosis and Treatment of Pulmonary Hypertension of the European Society of Cardiology (ESC) and the European Respiratory

Society (ERS): Endorsed by: Association for European Paediatric and Congenital Cardiology (AEPC), International Society for Heart and Lung Transplantation (ISHLT). *Eur Heart J* 2016; 37(1): 67-119.
12. Bajc M, Neilly JB, Miniati M et al. EANM guidelines for ventilation/ perfusion scintigraphy : Part 1. Pulmonary imaging with ventilation/perfusion single photon emission tomography. *Eur J Nucl Med Mol Imaging* 2009; 36(8): 1356-70.
13. Tunariu N, Gibbs SJ, Win Z et al. Ventilation-perfusion scintigraphy is more sensitive than multidetector CTPA in detecting chronic thromboembolic pulmonary disease as a treatable cause of pulmonary hypertension. *J Nucl Med* 2007; 48(5): 680-4.
14. Bajc M, Neilly JB, Miniati M et al. EANM guidelines for ventilation/perfusion scintigraphy : Part 2. Algorithms and clinical considerations for diagnosis of pulmonary emboli with V/P(SPECT) and MDCT. *Eur J Nucl Med Mol Imaging* 2009; 36(9): 1528-38.
15. Bajc M, Schümichen C, Grüning T et al. EANM guideline for ventilation/ perfusion single-photon emission computed tomography (SPECT) for diagnosis of pulmonary embolism and beyond. *Eur J Nucl Med Mol Imaging* 2019; 46(12): 2429-51.
16. Kim NH, Delcroix M, Jais X et al. Chronic thromboembolic pulmonary hypertension. *Eur Respir J* 2019; 53(1): 1801915.
17. Gutte H, Mortensen J, Jensen CV et al. Detection of pulmonary embolism with combined ventilation-perfusion SPECT and low-dose CT: head-to-head comparison with multidetector CT angiography. *J Nucl Med* 2009; 50(12): 1987-92.
18. Laurence IJ, Redman SL, Corrigan AJ, Graham RN. V/Q SPECT imaging of acute pulmonary embolus - a practical perspective. *Clin Radiol* 2012; 67(10): 941-8.
19. Wang M, Wu D, Ma R et al. Comparison of V/Q SPECT and CT Angiography for the Diagnosis of Chronic Thromboembolic Pulmonary Hypertension. *Radiology* 2020; 296(2): 420-9.
20. He J, Fang W, Lv B et al. Diagnosis of chronic thromboembolic pulmonary hypertension: comparison of ventilation/perfusion scanning and multidetector computed tomography pulmonary angiography with pulmonary angiography. *Nucl Med Commun* 2012; 33(5): 459-63.
21. Soler X, Kerr KM, Marsh JJ et al. Pilot study comparing SPECT perfusion scintigraphy with CT pulmonary angiography in chronic thromboembolic pulmonary hypertension. *Respirology* 2012; 17(1): 180-4.
22. Grgic A, Miodek F, Schäfers HJ et al. Assessment of operability by means of CTPA and perfusion SPECT in patients with chronic thromboembolic pulmonary hypertension. *Acta Radiol* 2016; 57(1): 33-40.
23. Ma RZ, Han PP, Tao XC et al. A Feasibility Study on Using Single-Photon Emission Computed Tomography Pulmonary Perfusion/Ventilation Imaging for the Diagnosis of Chronic Thromboembolic Pulmonary Hypertension and Patient Risk Assessment. *Int J Gen Med* 2021;14: 8029-38.
24. Alduraibi A, Fathala A. Normal ventilation/perfusion lung scan in patients with extensive chronic thromboembolism pulmonary hypertension: A case report. *Radiol Case Rep* 2019; 14(4): 510-3.
25. Nishiyama KH, Saboo SS, Tanabe Y et al. Chronic pulmonary embolism: diagnosis. *Cardiovasc Diagn Ther* 2018; 8(3): 253-71.
26. Ozguven S, Ones T, Bozkurtlar E et al. Chronic thromboembolic pulmonary hypertension: evaluation of V/Q SPECT/CT and V/Q Quotient SPECT findings with postoperative results of pulmonary endarterectomy. *Nucl Med Commun* 2021; 42(4): 369-77.
27. Johns CS, Swift AJ, Rajaram S et al. Lung perfusion: MRI vs. SPECT for screening in suspected chronic thromboembolic pulmonary hypertension. *J Magn Reson Imaging* 2017; 46(6): 1693-7.
28. Xu S, Yang J, Zhu Y et al. CTPA, DECT, MRI, V/Q Scan, and SPECT/CT V/Q for the noninvasive diagnosis of chronic thromboembolic pulmonary hypertension: A protocol for systemic review and network meta-analysis of diagnostic test accuracy. *Medicine (Baltimore)* 2019; 98(34): e16787.