^{18}F-FDG PET/CT texture analysis of anthracotic lymph nodes detected with EBUS and comparison with cytological findings

Fikri Okan Falay[1] MD,
Çisel Aydın Mericoz[2] MD,
Elif Demirtas[3] MD,
Pınar Bulutay[2] MD,
Hülya Seymen[1] MD,
Pınar Firat[2] MD,
Mehmet Onur Demirkol[1] MD,
Benan Caglayan[4] MD

1. Department of Nuclear Medicine and Molecular Imaging, School of Medicine, Koc University, Istanbul, Turkey
2. Department of Pathology, School of Medicine, Koc University, Istanbul, Turkey
3. School of Medicine, Koc University, Istanbul, Turkey
4. Department of Chest Diseases, School of Medicine, Koc University, Istanbul, Turkey

Keywords: ^{18}F-FDG - Anthracosis - PET/CT - Lung cancer - Endobronchial ultrasound

Corresponding author:
F. Okan Falay MD
Koç Universtiy School of Medicine, Department of Nuclear Medicine and Molecular Imaging
Tel: +905324329596,
Hospital tel:+908502508250
Fax: +902123381165
ofalay@kuh.ku.edu.tr

Received:
8 June 2022
Accepted revised:
13 July 2022

Abstract

Objective: Lymph node metastasis is the most important factor both in the selection of treatment since many alternatives have been created in recent years, and in the evaluation of prognosis in lung cancer. The most unpredictable cause of lymph node false positivity in fluorine-18-fluorodeoxyglucose (^{18}F-FDG) positron emission tomography/computed tomography(PET/CT) is anthracosis. The aim of this study is to compare ^{18}F-FDG PET/CT texture information of anthracotic (ALN) and metastatic (MLN) lymph nodes, after re-evaluation of the cytological samples obtained from anthracotic lymph nodes by EBUS-TBNA. **Subjects and Methods:** Ninety nine patients, 78 of whom had primary lung cancer were included in the study. Two hundred and three lymph nodes from 99 patients sampled by EBUS-TBNA and diagnosed cytologically as ALN or MLN were evaluated retrospectively. All ALN were classified as grades 1, 2 and 3 cytologically. Volume of interest (VOI) of 203 lymph nodes was re-drawn and maximum standardized uptake value (SUVmax), metabolic tumor volume (MTV) and total lesion glycolysis (TLG) values were recorded. **Results:** There was a statistically significant difference in MTV and TLG values in MLN and all ALN grades. However, only grade 1-2 ALN could be differentiated from MLN with SUVmax, and no statistically significant difference was found in grade 3 ALN and MLN. Metabolic tumor volume and TLG values over 4.10cm^3 and 26.57 showed 60% and 59% sensitivity and 83% and 94 specificity respectively for the identification of MLN. **Conclusions:** The contribution of MTV and TLG values of ^{18}F-FDG PET/CT to the differential diagnosis of ALN is much more valuable than SUVmax values, especially for grade 3 anthracosis. It was thought that cytological reporting of only grade 3 ALN could make a better contribution to the ^{18}F-FDG PET/CT evaluation analysis.

Hell J Nucl Med 2022; 25(2): 148-154 *Epub ahead of print: 3 August 2022* *Published online: 29 August 2022*

Introduction

Lung cancer is the 2nd most common type of cancer in men and women and has the highest mortality in both sexes with approximately 25% [1]. Lymph node metastasis in primary lung cancer staging provides the most definitive factor in terms of evaluating both treatment options and prognosis. Achieving the highest accuracy rate in preoperative clinical lymph node staging is so important in surgical approach which is standard treatment modality in early-stage lung cancer. In addition, accurate lymph node staging is also crucial for the correct indication of neoadjuvant treatment, which has recently become a part of the routine [2]. In lung cancer, clinical lymph node staging is performed with fluorine-18-fluorodeoxyglucose (^{18}F-FDG) positron emission tomography/computed tomography (PET/CT), which is the most sensitive non-invasive procedure, and it is also informative for distant metastasis. The evaluation is applied with quantitative (such as SUVmax>2.5-5.2, ≥25% increase in late image) and qualitative (such as uptake above mediastinal blood pool) properties of ^{18}F-FDG uptake in the lymph nodes, nevertheless the desired accuracy rate cannot be achieved due to the low specificity of around 70% [3]. For this purpose, the minimal invasive (endobronchial ultrasonography-EBUS, esophageal ultrasonography-EUS) and invasive (cervical or video-guided mediastinoscopy, left parasternal mediastinotomy, video assisted thoracoscopy (VATS)) techniques with higher accuracy rate are being applied. Accessible lymph node stations are 1, 2, 3p, 4, 7, 10, 11 and 12 by EBUS, 5, 7, 8 and 9 by EUS, 1, 2, 4 and 7 by mediastinoscopy and station 6 only by mediastinotomy. So, a single technique is not sufficient for the evaluation of all stations and the maximum number of stations can be sampled only if EBUS and EUS are performed together [4]. The accuracy rates of CT, PET and EBUS-TBNA in mediastinal and hilar lymph node staging are 60.8%, 72.5% and 98.0%, respectively. Endobronchial ultrasonography-TBNA has been proven to have higher sensitivity and specificity for mediastinal staging compared to CT or ^{18}F-FDG PET in potential resectable lung cancer cases [5, 6]. Clinical

lymph node staging is performed by sampling ^{18}F-FDG (+) or ^{18}F-FDG (-) pathological sized lymph nodes with minimally invasive or invasive methods in clinical necessity in stage 4 and routinely in all other stages except T1 tumors that have no hilar or >10mm mediastinal lymph node, and have no pathological ^{18}F-FDG involvement in lymphatic stations, and have located in the outer 1/3 parenchyma of the lung [7-9]. The cause of high sensitivity but lower specificity of ^{18}F-FDG PET is due to the ability of ^{18}F-FDG to enter any cell which has Glut-1 enzyme on its cell membrane or the activation rate of hexokinase/glucose 6 phosphatase enzymes or according to glycolysis level in the cell. In several non-malignant cases ^{18}F-FDG may accumulate within the cell by the activation of these processes. Anthracosis and granulomatous diseases (tuberculosis, sarcoidosis) in which granulocytes are abundant are the most common causes of false positives in ^{18}F-FDG PET due to the high Glut-1 enzyme level in granulocytes [8, 10].

We aimed to investigate the contribution of ^{18}F-FDG PET/CT texture findings of ALN and MLN to the differential diagnosis for a possibility of increasing ^{18}F-FDG PET/CT accuracy in clinical lymph node staging, which is the most important prognostic information in lung cancer.

Subjects and Methods

Between February 2014 and October 2019, 135 cancer cases, 118 of whom had lung cancer, had EBUS-TBNA and ^{18}F-FDG PET/CT performed up to 30 days ago as standard procedures, were evaluated. Ninety nine patients, 78 of whom had primary lung cancer, who had adequate ^{18}F-FDG PET/CT technical standards were included in the study after anonymizing their credentials and health records. Out of a total of 368 lymph nodes sampled by EBUS-TBNA in 99 patients, 203 lymph nodes with cytologically diagnosed of ALN and MLN were evaluated retrospectively. Volume of interest (VOI) of 203 lymph nodes were redrawn and maximum standardized uptake value (SUVmax), metabolic tumor volume (MTV) and total lesion glycolysis (TLG) values were recorded. All ALN's were classified as grades 1, 2 and 3 cytologically.

Fluorine-18-FDG PET/CT SUVmax, MTV and TLG values of grade 1, 2 and 3 ALN and MLN were statistically compared. $P<0.05$ was considered as a statistically significant difference.

^{18}F-FDG PET/CT

Fluorine-18-FDG PET/CT examination of 7-9 bed length vertex and mid-crus or vertex and mid-thigh imaging on GE Discovery IQ 5 ring or GE Discovery 710 PET/CT devices was included in the study 50-70 minutes after the 3.7-4.0MBq/kg ^{18}F-FDG given via intravenous. The resulting images were evaluated by PET Volume Computer Assisted Reading (VCAR) program at GE AW workstation. Maximum SUV, MTV and TLG values were recorded in VOI re-drawn from the lymph nodes observed on CT of mediastinal and hilar stations which were biopsied on EBUS-TBNA, and from the primary mass in lung cancer patients.

EBUS-TBNA

The EBUS-TBNA was performed via oral route with conscious or deep sedation/local anesthesia or under general anesthesia via endotracheal tube according to the patient or physician preference. For sedation, midazolam and/or fentanyl and/or propofol were used. The Convex probe-EBUS (BF-UC180F; Olympus Ltd., Tokyo, Japan) equipped with a linear probe on its tip was used to perform EBUS-TBNA. The ultrasound image was processed with a universal endoscopic ultrasound scanner (EU-ME2 Premier Plus, Olympus Ltd., Tokyo, Japan) at a frequency of 10MHz. Olympus ViziShot NA-SX 22-gauge needle was used. Cytological specimens were collected from different stations and rapidly evaluated on-site by pathologists (ROSE) throughout the entire procedure. Aspiration was terminated after the specimen was found to be sufficient for diagnosis by ROSE.

Pathology

Two hundred and three separate lymph node (92 ALN, 111 MLN) aspirations belonging to 99 patients were re-evaluated by two pathologists. The amount of anthracotic pigment/anthracosis within ALN aspirations was assessed and graded into three groups. It was evaluated as grade 1 (n: 38, 39%) if there was a trace amount on the slide, grade 2 (n:34, 33%) if there was a moderate amount and grade 3 (n:20, 28%) if the amount of anthracosis was extensive.

Statistical analysis

Descriptive statistics were used to identify continuous variables. (Average, standard deviation, minimum, median, maximum) Categorical variables are defined by frequency (n) and percentages (%). The suitability of continuous variables to normal distribution was examined by Shapiro wilks test. The comparison of the two variables, which are independent and not conforming to the normal distribution was made with the Mann-Whitney U test. More than two variables that do not conform to independent and normal distribution are compared with the Kruskal Wallis test. The Post Hoc binary comparison for parameters with significance was made with the Mann-Whitney U test with Bonferroni correction. The comparison between categorical variables was made using Ki-Square test (or Yates Continuity correction or Fisher Exact test where appropriate).

Results

In this study, 203 lymph nodes sampled by EBUS-TBNA from 99 patients, 78 of whom had primary lung malignancy and 21 had primary malignant tumors outside thorax, were evaluated (Table 1). Distribution of 3 histopathological subgroups of the primary lung malignancies were adenocarcinoma (n:30, 14.8%), squamous cell carcinoma (n:22, 10.8%) and small cell carcinoma (n:26, 12.8%). The correlations between ALN and MLN histological subtypes and the findings are shown in Table 2. While there were also significant differences

between the MTV and TLG values of all ALN and MLN, statistical significance observed only between grade 1-2 ALN and MLN for SUVmax values (P<0.05).When all ALN are evaluated as a single group, there is a significant difference with all ^{18}F-FDG PET/CT values between ALN and MLN.

Table 1. *Demographic characteristics of 99 patients.*

Variable	Number (%) (Total n:99)
Sex	
Male	58 (59)
Female	41 (41)
Age	
Mean±SD	64.1±10.5
Median (range)	65
Histology	
Adenocarcinoma	30 (31)
Squamous cell carcinoma	22 (22)
Small cell carcinoma	26 (26)
Other malignancies	21 (21)
Breast cancer	8 (8)
Colorectal cancer	5 (5)
Esophageal cancer	4 (4)
Other cancers	4 (4)
Lung Cancer Stage	
NSCLC*	
IA	2 (2)
IIA	4 (4)
IIB	10 (10)
IIIA	38 (39)
IIIB	14 (14)
IV	5 (5)
SCLC**	
Limited	11 (11)
Extensive	15 (15)

**NSCLC: non-small cell lung cancer; **SCLC: small cell lung cancer*

Table 2. *The correlations of ^{18}F-FDG PET/CT findings between ALN (grade 1-3, total) and MLN.*

		Grade 1 ALNs	Grade 2 ALNs	Grade 3 ALNs	Total ALNs	*p-value***	MLNs
SUVmax	Median	3.41	3.78	5.66	4.12	< 0.05	10.35
	İ.range*	2.33	3.24	5.97	7.71	≥ 0.05	10.07
MTV (cm^3)	Median	2.94	3.26	2.44	2.85	< 0.05	4.93
	İ.range	2.78	4.24	2.31	3.46		7.23
TLG	Median	7.56	8.98	8.54	8.22	< 0.05	30.72
	İ.range	9.68	17.06	12.08	15.76		56.14

**Interquartile range, ** < 0.05 significant, ≥ 0.05 non-significant*

It was observed that all correlations detected between ALN and MLN in lung cancer cases were independent of the localization of the primary focus or histological type.

The sensitivity and specificity values according to optimum cut-off values of ^{18}F-FDG PET/CT findings in ROC analysis where there is a significant difference between grade 1-3 ALN and MLN and between grade 3 and MLN are given in Figures 1 and 2.When all grades of ALN are considered, differential diagnosis can be made with a sensitivity of 74% and a specificity of 75%, when SUVmax is above 5.72. In addition, in cases where MTV was above 4.42cm^3 and TLG was above 12.49, sensitivity values of 58% and 80%, and specificity of 70% and 70%, were obtained, respectively (Figure 1). No statistically significant difference was found between MLN and Grade 3 ALN with SUVmax. However, 60% and 59% in sensitivity and 83% and 94% in specificity were achieved where MTV and TLG were above 4.10 cm^3 and 26.57, respectively (Figure 2).

Discussion

Lung cancer mostly spreads to lymph node before distant metastasis, so the most important prognostic information at the time of diagnosis obtained from the N staging [11]. Although many qualitative and quantitative parameters were added to the evaluation on ^{18}F-FDG PET/CT which has the highest non-invasive accuracy rate, the achievable N staging sensitivity was 58%-94%, and specificity 76%-96% [12]. More accurate mediastinal N staging is important not only for choosing the right treatment modality, but also for avoiding unnecessary surgical and invasive interventions. The clinical information of the mediastinal lymph node station 6, which cannot be reached by non-invasive interventional lymph node sampling, station 5, which is located lateral to the ligamentum arteriosum and is not preferred due to the

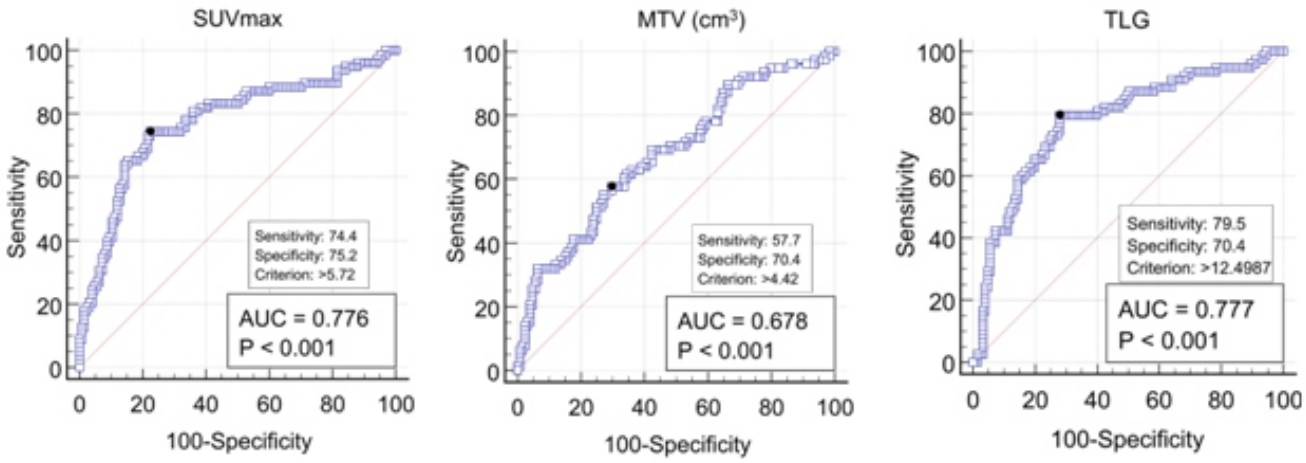

Figure 1. ROC curve analysis for optimum cut-off levels (SUVmax: 5.72, MTV: 4.42cm^3, TLG:12.50) of ^{18}F-FDG PET/CT findings in differentiating between grade 1-3 ALN and MLN.

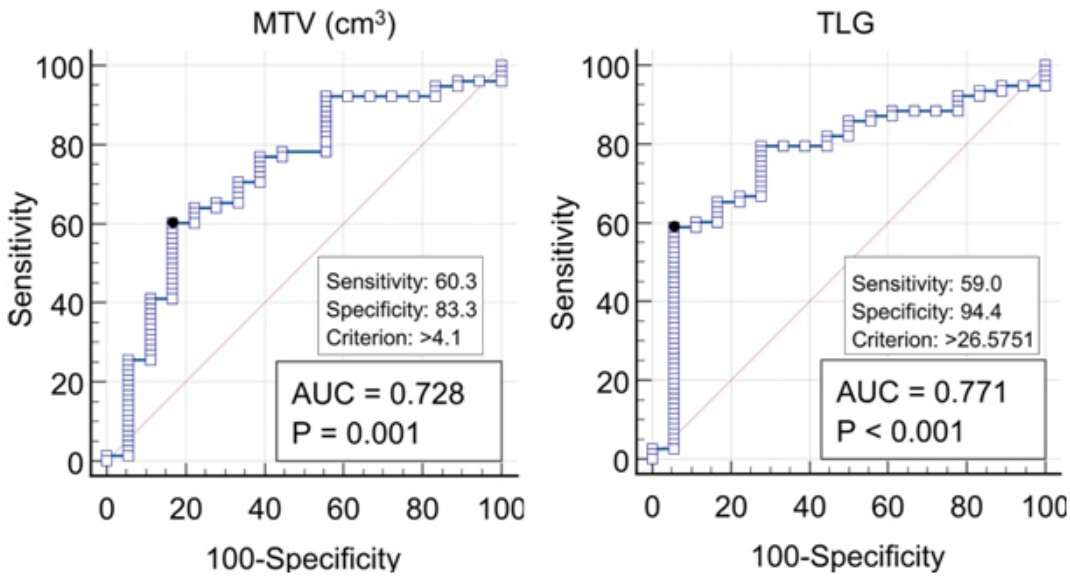

Figure 2. ROC curve analysis for optimum cut-off levels (MTV: 4.10cm^3, TLG: 26.57) of ^{18}F-FDG PET/CT findings in differentiating between grade 3 ALN and MLN.

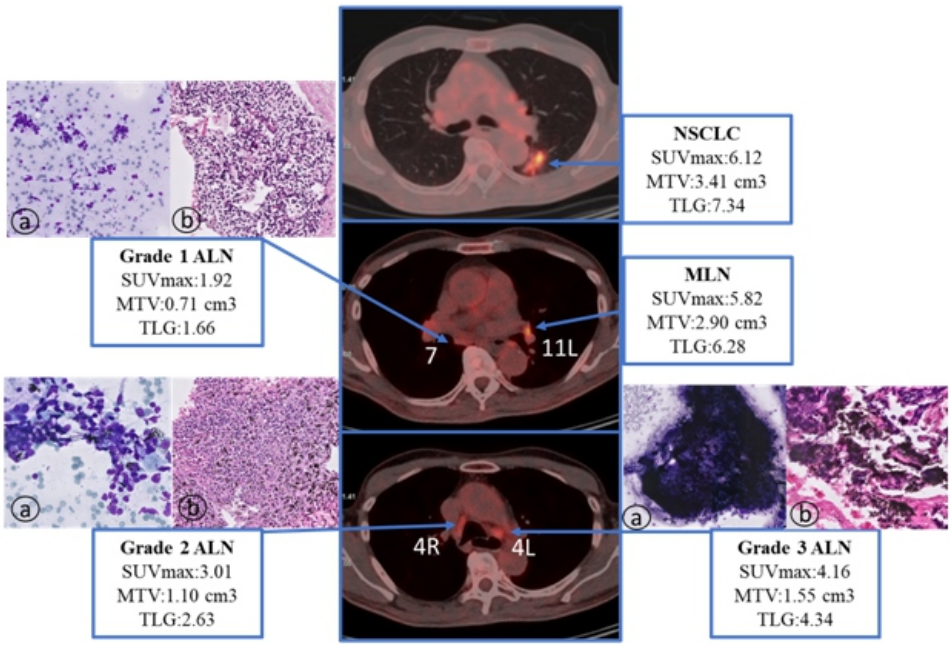

Figure 3. Fluorine-18-FDG PET/CT and cytological (a-smear b-cell block) findings in a 69-year-old NSCLC patient with MLN at station 11L, grade 3 (extensive anthracosis) ALN at station 4L, grade 2 (a moderate amount of anthracosis) ALN at station 4R, grade 1(a trace amount anthracosis on the slide) ALN at station 7, with a primary malignancy in the left lung lower lobe.

need for transvascular sampling with EBUS-TBNA and cannot be reached by EUS, and stations 13 and 14, which cannot be sampled by any method, can only be provided by ^{18}F-FDG PET/CT scan [13, 14].

Until about 5 years ago, knowledge of clinical N2 disease was important for systemic or multimodal treatment strategies, while the treatment approach between N1 and N0 was not different except for postoperative adjuvant chemotherapy, only surgery was applied. With the advances in radiation oncology and medical oncology in the last decade, multimodal treatment approaches have started to take place in the routine on all stages. Consequently complete therapy response can be seen after radiosurgery in stage I NSCLC patients for whom pathological information cannot be obtained by sampling, patients that are inoperable due to functional reasons or comorbidities, patients who do not want surgery and patients receiving neoadjuvant immunotherapy [15-17]. For these reasons N0 and N1 diseases should have different treatment strategies, the frequency of unexpected N2 lesions should be reduced. After these developments, the importance of accuracy in clinical staging for non-sampled lymph node stations has increased much more.

In the diagnosis of lymph node metastasis in ^{18}F-FDG PET/CT, evaluations on many studies were made according to whether the SUVmax value above 2.5 or 5.2 or above the mediastinal blood pool level in ^{18}F-FDG PET/CT. In the study of 400 NSCLC patients by Cerfolio et al. (2003), they reported that the diagnostic accuracy of N1 and N2 with ^{18}F-FDG PET in 2.5 threshold of SUVmax was not different (76% vs 78%) [18]. However, postoperative N1 positivity in 6%-34% of clinical N0 cases also reveals how low the sensitivity is in clinical staging [19-21].

Cases of anthracosis mimicking tuberculosis and malignancy have been reported in the literature; and it is a well-known cause of false positivity in the ^{18}F-FDG PET/CT interpretations in lung cancer patients [22, 23]. In our study, the rate of anthracosis in the sampled hilar and mediastinal lymph nodes in 99 patients who underwent EBUS-TBNA was 25% (92/368).

Lee et al. (2018), 58 of 338 ^{18}F-FDG (+) lymph nodes sampled with EBUS-TBNA in 247 NSCLC had false positive; these lymph nodes consisted of 11 tuberculosis, 7 pneumonia, 6 interstitial lung disease, 6 anthracosis and 5 pneumoconiosis [9]. Among the causes of false positivity in lymph node staging with ^{18}F-FDG PET, anthracosis is the most difficult to predict because it does not have any specific clinical findings.

Li et al. (2013) had 13.2% false negativity in hilar and mediastinal lymph nodes with ^{18}F-FDG PET in 219 NSCLC patients that was more common non-malignant lung disease, diabetic patient group, non-adeno ca patients and patients with primary tumor SUVmax >4. The false positivity was seen in 45.5% of patients in cases with primary tumor SUVmax ≤4, over 65 years of age and well differentiated malignancy [24].

Ivanick et al. (2021) anthracotic lymph nodes were mostly in bilateral hilar localizations in EBUS-TBNA samples in the group of 20 patients, and the mean SUVmax was found to be 7.9±2.2 [25]. Demirci et al. (2015), in 201 lymph nodes sam-pled by EBUS-TBNA of 106 patients, ALN was most common in subcarinal and interlobar lymph nodes, with a mean SUVmax

of 4.76 [26]. In our study, there was no significant relationship between age, histopathologic type, T stage, lobar distribution or ^{18}F-FDG affinity of the primary malignancy and anthracotic lymph node appearance.

Kaseda et al. (2016) reported that ^{18}F-FDG PET sensitivity was 47.4%, specificity was 91%, and accuracy was 82.5% in hilar and mediastinal lymph nodes in their study in which they examined 750 lymph nodes in 250 NSCLC patients. In that study, 43.8% (28/64) of patients were confirmed as false positive with upstaging from N0 to N1 or N2, and when SUVmax is above 1.7, the sensitivity and specificity could only reach 80.3% and 59.9% [8]. In our study, the sensitivity was 74.4% and the specificity was 75.2% when the SUVmax was above 5.72.

According to Korkmaz et al. (2021) in their study in which they examined 1068 lymph nodes sampled by EBUS-TBNA from 545 patients, they reported that SUVmax values in anthracotic and reactive lymph nodes were significantly lower than those of malignant ones (anthracotic -6.31±4.3, reactive -5.07±2.53, malignant-11.02±7.30) [27]. While there was a statistically significant difference between grade 1-2 ALN and MLN in our study based on SUVmax, which is the most used criterion in studies, no significant difference was observed with grade 3 ALN. However, there is a statistically significant difference between all ALN grades and MLN based on MTV and TLG.

Ivanick et al. (2021) and Demirci et al. (2015), both shared that the possibility of ALN should be considered first in the group of patients who were exposed to biomass and cigarette smoke for a long time on ^{18}F-FDG PET exam. The more the limit SUVmax value is increased, the higher the accuracy level of ^{18}F-FDG PET in detecting lymph node metastasis, and there is a great overlap between MLN and ALN SUVmax le-vels in every criterion.

In most studies evaluating false positivity in the lymph node in ^{18}F-FDG PET, SUVmax was used as a criterion. Although it was concluded in some of the studies that SUVmax was sufficient for the differential diagnosis of ALN, other study results concluded that it could not make with it. In our study design, regardless of the level of ^{18}F-FDG uptake, all lymph nodes diagnosed with ALN cytologically were evaluated to create a different perspective. Metabolic tumor volume and TLG are the texture parameters obtained with SUVmax when the area of interest is drawn in ^{18}F-FDG PET/CT. It has been reported that MTV and TLG calculated with the fixed absolute thresholds method is reliable, and the 42% threshold we use is shared as the most reliable prognostic and diagnostic approach [28].

The correlation between total ALN and MLN, there are statistically significant differences with all texture parameters of ^{18}F-FDG PET/CT. In our study, AUC was found to be 0.776 if SUVmax >5.72, AUC 0.67 if MTV >4.42cm^3, and AUC 0.77 if TLG >12.49. However, since the cohort was formed by the presence of ALN rather than ^{18}F-FDG positive lymph nodes, it was thought that it would not be correct to compare with studies in lymph nodes whose lymph nodes with ^{18}F-FDG uptake at a level that can be seen in metastatic lymph nodes were evaluated. When only grade 3 ALN were compared with MLN, there was no statistically significant difference in SUVmax in our study. However, there were statistically significant differences between grade 3 ALN and MLN in MTV and TLG values, and AUC was 0.72 when MTV was >4.10cm^3, and 0.77 when TLG was >26.57.

Limitations of our study include its retrospective design, the relatively small number of patients and being first study in which ALN were graded. However, prospective randomized controlled trials with a higher number of patients are needed to produce robust data coming and extending the current results.

In conclusion, it can be predicted that the group that caused ^{18}F-FDG PET/CT false positivity in our daily clinical practice is grade 3 ALN. In our study, it was seen that MTV and TLG values that obtained with ^{18}F-FDG PET/CT makes the most contribution to the differential diagnosis of ALN which is the most common cause of unpredictable false positivity, in the staging of lung cancer than SUVmax especially grade 3 group. In addition, when cytologic reporting ALN, it was thought that only those with grade 3 may be reported, so that the analysisof ALN evaluation in ^{18}F-FDG PET/CT could be more accurate.

Bibliography

1. Siegel RL, Miller KD, Jemal A. Cancer statistics, 2020. *CA Cancer J Clin* 2020; 70(1): 7-30.
2. Travis WD, Dacic S, Wistuba I et al. IASLC Multidisciplinary Recommendations for Pathologic Assessment of Lung Cancer Resection Specimens After Neoadjuvant Therapy. *J Thorac Oncol* 2020;15(5):709-40.
3. Schimmer C, Neukam K, Elert O. Staging of non-small cell lung cancer: Clinical value of positron emission tomography and mediastinoscopy. *Interact Cardiovasc Thorac Surg* 2006; 5(4): 418-23.
4. Lung cancer update [A] Evidence reviews for effectiveness of non-ultrasound-guided TBNA, EBUS-TBNA or EUS-FNA for people with a probability of mediastinal malignancy NICE guideline NG122. Published online 2019.https://www.ncbi.nlm.nih.gov/books/NBK558781/pdf/Bookshelf_NBK558781.pdf.
5. Yasufuku K, Nakajima T, Motoori K et al. Comparison of endobronchial ultrasound, positron emission tomography, and CT for lymph node staging of lung cancer. *Chest* 2006; 130(3): 710-8.
6. De leyn P, Dooms C, Kuzdzal J et al. Revised ests guidelines for preoperative mediastinal lymph node staging for non-small-cell lung cancer. *Eur J Cardiothorac Surg* 2014; 45(5): 787-98.
7. Kumar A, Dutta R, Kannan U et al. Evaluation of mediastinal lymph nodes using ^{18}F-FDG PET-CT scan and its histopathologic correlation. *Ann Thor Med* 2011; 6(1): 11-6.
8. Kaseda K, Watanabe K ichi, Asakura K et al. Identification of false-negative and false-positive diagnoses of lymph node metastases in non-small cell lung cancer patients staged by integrated ^{18}F-fluorodeoxyglucose-positron emission tomography/computed tomography: A retrospective cohort study. *Thor Cancer* 2016; 7(4): 473-80.
9. Lee J, Kim YK, Seo YY et al. Clinical Characteristics of False-Positive Lymph Node on Chest CT or PET-CT Confirmed by Endobronchial Ultrasound-Guided Transbronchial Needle Aspiration in Lung Cancer. *Tuberc Respir Dis (Seoul)* 2018; 81(4): 339-46.
10. Silvestri GA, Gonzalez A V, Jantz MA et al. Methods for staging non-small cell lung cancer: Diagnosis and management of lung cancer, 3rd ed: American college of chest physicians evidence-based clinical practice guidelines. *Chest* 2013;143 (5 Suppl): e211S-e250S.
11. Asamura H, Chansky K, Crowley J et al. The International Association for the Study of Lung Cancer Lung Cancer Staging Project: Proposals for the Revision of the N Descriptors in the Forthcoming 8th Edition of the TNM Classification for Lung Cancer. *J Thor Oncol* 2015;10(12): 1675-84.
12. Kandathil A, Kay FU, Butt YM et al. Role of ^{18}F-FDG PET/CT in the Eighth Edition of TNM Staging of Non-Small Cell Lung Cancer. *RadioGraphics* 2018; 38(7): 2134-49.

13. Rena O, Boldorini R, Papalia E et al. Metastasis to Subsegmental and Segmental Lymph Nodes in Patients Resected for Non-Small Cell Lung Cancer: Prognostic Impact. *Ann Thorac Surg* 2014; 97(3): 987-92.
14. Bendzsak A, Oliveira R, Goudie E et al. Evaluation of the Mediastinum: Differentiating Between Stations 4L, 5, and 6 Using EBUS and EUS Lower Paratracheal (Station 4L) Nodes. *Ann Thorac Surg* 2017; 103(2): e219-e221.
15. Käsmann L, Eze C, Taugner J et al. Chemoradioimmunotherapy of inoperable stage III non-small cell lung cancer: Immunological rationale and current clinical trials establishing a novel multimodal strategy. *Radiat Oncol* 2020; 15(1): 167.
16. Gao P, Chen H, Zeng T et al. A pathological complete response to neoadjuvant chemotherapy and immunotherapy in a non-small cell lung cancer patient. *Transl Lung Cancer Res* 2020; 9(5): 2157-60.
17. Gómez-caro A, Boada M, Cabañas M et al. False-negative rate after positron emission tomography/computer tomography scan for mediastinal staging in cI stage non-small-cell lung cancer. *Eur J Cardiothorac Surg* 2012; 42(1): 93-100.
18. Cerfolio RJ, Ojha B, Bryant AS et al. The role of FDG-PET scan in staging patients with nonsmall cell carcinoma. *Ann Thorac Surg* 2003; 76(3): 861-6.
19. Koike T, Koike T, Yamato Y et al. Predictive risk factors for mediastinal lymph node metastasis in clinical stage IA non-small-cell lung cancer patients. *J Thorac Oncol* 2012; 7(8): 1246-51.
20. Tsutani Y, Miyata Y, Nakayama H et al. Prediction of pathologic node-negative clinical stage IA lung adenocarcinoma for optimal candidates un-dergoing sublobar resection. *J Thorac Cardiovasc Surg* 2012; 144(6): 1365-71.
21. Kaseda K, Asakura K, Kazama A, Ozawa Y. Risk Factors for Predicting Occult Lymph Node Metastasis in Patients with Clinical Stage I Non-small Cell Lung Cancer Staged by Integrated Fluorodeoxyglucose Positron Emission Tomography/Computed Tomography. *World J Surg* 2016; 40(12): 2976-83.
22. Bilici A, Erdem T, Nur Boysan S et al. A case of anthracosis presenting with mediastinal lymph nodes mimicking tuberculous lymphadenitis or malignancy. *Eur J Intern Med* 2003; 14(7): 444-6.
23. Lin WY, Hsu WH, Lin KH, Wang SJ. Role of preoperative PET-CT in assessing mediastinal and hilar lymph node status in early stage lung cancer. *J Chin Med Assoc* 2012; 75(5): 203-8.
24. Li S, Zheng Q, Ma Y et al. Implications of False Negative and False Positive Diagnosis in Lymph Node Staging of NSCLC by Means of ^{18}F-FDG PET/CT. *PLoS ONE* 2013; 8(10): e78552.
25. Ivanick NM, Shrestha P, Podolsky MJ et al. A retrospective observational study of benign anthracotic lymphadenitis and its association with PET avid lymph nodes in patients undergoing cancer evaluation. *J Thorac Dis* 2021; 13(7): 4228-35.
26. Yilmaz Demirci N, Alici İO, Yilmaz A et al. Risk factors and maximum standardized uptake values within lymph nodes of anthracosis diagnosed by endobronchial ultrasound-guided transbronchial needle aspiration. *Turk J Med Sci* 2015; 45(4): 984-90.
27. Korkmaz C, Demirbas S, Vatansev H. The value of endobronchial ultrasound-guided transbronchial needle aspiration, ^{18}F-fluorodeoxyglucose positron emission tomography/computed tomography, and ultrasonography imaging techniques in the diagnosis of mediastinal and/or hilar malignant, anthracotic, and other benign lymph nodes. *Medicine* 2021; 100(7): e24728.
28. Im HJ, Bradshaw T, Solaiyappan M, Cho SY. Current Methods to Define Metabolic Tumor Volume in Positron Emission Tomography: Which One is Better? *Nucl Med Mol Imaging* 2018; 52(1): 5-15.