Initial clinical experience with dedicated multi-pinhole (MPH) collimator for ^{99m}Tc-HMPAO brain perfusion SPECT

Zita Képes[1] MD, Kornél Kukuts[2] BSc, Attila Oszlánszki[2] BSc, Iván Mihovk[1] MD, Áron Krizsán[2] PhD, Sándor Barna[2] MD, Andrew Robinson[5], Daniel Deidda[5], János Mester[3,4] PhD, József Varga[1] PhD, Ildikó Garai[1,2] MD, PhD, Attila Forgács[2] PhD

1. Division of Nuclear Medicine and Translational Imaging, Department of Medical Imaging, Faculty of Medicine, University of Debrecen, Debrecen, Hungary
2. Scanomed Nuclear Medicine Center Debrecen, Debrecen, Hungary
3. Department of Diagnostic and Interventional Radiology and Nuclear Medicine, University Medical Center Hamburg-Eppendorf, Hamburg, Germany
4. Mediso Medical Imaging Systems, Budapest, Hungary
5. National Physical Laboratory, Teddington, UK

Keywords: Brain perfusion - SPECT - Multi-pinhole collimator - Reconstruction - Image quality

Corresponding author:
Zita Képes MD,
University of Debrecen, Faculty of Medicine, Department of Medical Imaging, Division of Nuclear Medicine and Translational Imaging, Nagyerdeikrt. 98, 4032 Debrecen, Hungary
Tel: +36-70-364-6025
kepes.zita@med.unideb.hu,
zitakepes@gmail.com

Received:
1 October 2021
Accepted revised:
2 June 2022

Abstract

Objective: Dedicated multi-pinhole (MPH) collimators have been successfully tested in selected clinical investigations. The aim of our work was to report initial experiences with an MPH collimator set designed for brain perfusion single photon emission tomography (SPECT). **Subjects and Methods:** Ten patients underwent sequential technetium-99m-hexamethylpropyleneamineoxime (^{99m}Tc-HMPAO) SPECT with a dual-head SPECT camera equipped with conventional low-energy parallel hole collimators (LEHR), and with a triple-head system equipped with MPH collimators. Low-energy parallel hole collimators data were reconstructed by filtered back projection (FBP), ordered subset expectation maximization (OSEM), software for tomographic image reconstruction (STIR). In addition, both the parallel hole data and MPH data were reconstructed by Tera-Tomo™ 3D iterative reconstruction denoted LEHR_TT3D and MPH_TT3D, respectively. Five medical experts visually compared the reconstructed images of the five data sets and defined a ranking sequence from the lowest (1) to the highest (5) image quality. Results were compared using the Friedman test. P values below 0.05 were considered significant. **Results:** Low-energy parallel hole collimators acquisition resulted in 5 million, while MPH acquisition in 13 million total counts with 30 and 34 minutes of acquisition time, respectively. Mean rank coefficients of the reconstruction methods were 1.96±0.52, 2.66±0.46, 2.86±0.60, 3.62±0.55, 3.9±0.68 for FBP, STIR, LEHR_TT3D, LEHR_OSEM, MPH_TT3D respectively. The differences between MPH_TT3D-FBP ($P<0.01$); MPH_TT3D-STIR ($P<0.05$); LEHR_OSEM-FBP ($P<0.01$) were significant. **Conclusions:** Image quality provided by MPH collimator is comparable to that provided by conventional LEHR imaging. Higher sensitivity has the potential to shorten acquisition time or to reduce the amount of administered activity.

Hell J Nucl Med 2022; 25(2): 143-147 *Epub ahead of print: 3 August 2022* *Published online: 29 August 2022*

Introduction

Whole brain perfusion single photon emission computed tomography (SPECT) using technetium-99m (^{99m}Tc)-labelled radiotracers play an important role in numerous clinical situations [1-3].

Dual-headed cameras equipped with low-energy high-resolution (LEHR) or low-energy ultra-high-resolution (LEUHR) parallel hole collimators dominate in daily clinical routine to perform brain perfusion SPECT [4]. Although these devices provide an acceptable trade-off between 3D geometric resolution and sensitivity, further improvement in technical parameters would result in increased patient comfort and improved diagnostic performance as well. As a consequence, dedicated cameras with fan-beam and cone-beam collimators have been introduced into clinical practice [5-7]. Especially, fan-beam collimators offering notably increased sensitivity at slightly improved geometric resolution are frequently used [8]. In addition to the hardware innovations, novel iterative reconstruction techniques have led to improved lesion detection [9].

Preclinical imaging studies have demonstrated a new class of image quality in terms of geometric resolution up to the submillimetre level with increased sensitivity using multi-pinhole (MPH) collimator technology [10-14]. Furthermore, MPH imaging has been tested clinically in striatal [15] and myocardial perfusion imaging [14]. These investigations demonstrated the potential to increase overall sensitivity at preserved or even improved geometric resolution.

The MPH-brain collimator set was evaluated for clinical striatal dopamine transporter imaging [10]. In this study, we report on the initial results of the testing of this first generation novel collimator set in comparison with parallel hole collimator imaging. For this purpose, anthropometric phantom studies and repeated human examinations were performed and evaluated using standard parameters of the MPH-brain reconstruction software.

Moreover, the projection data acquired with parallel hole collimator have been reconstructed with different methods (FBP, 2D OSEM, STIR, TT3D) to provide a more comprehensive reference for the visual assessment.

Subjects and Methods

Study participants

This study was part of a clinical trial in patients with metabolic disorders. The trial was approved by the National Committee of Clinical Trials in Humans (OGYEI/2829-4/2017). Informed consent was obtained from all patients.

In addition to the study protocol with LEHR collimators, immediately after completing the acquisition, repeated imaging using MPH collimators was performed in 10 patients (mean age: 52.6 years±2.7 years) without history of mental or brain disorders. From among these patients 6 were suffering from controlled type 2 diabetes mellitus (DM), while 4 were non-DM obese participants with BMI >30kg/m^2.

^{99m}Tc-HMPAO SPECT with LEHR collimators

Half an hour prior to the intravenous injection of approximately 740MBq ^{99m}Tc-hexamethylpropyleneamineoxime (HMPAO) (Mediradiopharma, Hungary) 1000mg of perchlorate was administered orally. Single photon emission tomography acquisition started after a ten-minute rest in the dimly-lit examination room.

For the first study AnyScan SC Flex (Mediso Ltd., Hungary) dual-head gamma-camera equipped with LEHR parallel hole collimators was applied. Acquisition parameters were as follows: 120 views, 128x128 matrix with 2.4mm pixel size, 30sec projection time with body contouring. These acquisition settings resulted in a 30 minute total acquisition time.

^{99m}Tc-HMPAOSPECT with MPH collimators

Immediately after completing the SPECT with parallel hole collimators, the patients were repositioned under a triple-head gamma camera (AnyScan Trio, Mediso Hungary) equipped with MPH collimators.

Multi-pinhole SPECT parameters were the following: 72 views, 85sec/frame, 256x256 matrix size, 2.1mm pixel size, and with helical table displacement of 40mm, applying fix, 150mm detector radius. These acquisition settings resulted in a 34 minute total acquisition time.

Phantom measurements

The Kyoto IB-10 phantom (Kyoto Kagaku Co., Kyoto, Japan) with the anthropomorphic brain component was used. The activity concentration in the grey and white matter compartment was 193.3kBq/mL and 48.5kBq/mL, respectively, corresponding to a concentration ratio of~4. All acquisition parameters for the phantom studies were the same as for the investigations in humans.

Image reconstruction

Parallel collimator data sets were reconstructed by (1) filtered back projection (FBP) using Butterworth filter order 70 cut-off 70 with Chang attenuation correction (attenuation coefficient 0.12/cm); (2) ordered subsets expectation maximization (OSEM), with a Wiener pre-filter optimized for the cortex, and Chang attenuation correction; (3) a recently introduced OSEM from the Software for Tomographic Image Reconstruction (STIR) [16, 17] with 16 iterations and 2 subsets, together with a 3mm Gaussian post-filtering; and (4) an innovative contrast recovery reconstruction, Tera-TomoTM 3D (TT3D, Mediso, Hungary) with 48 iterations, 2 subsets, and low-level bilateral regularization. TT3D was used for the reconstruction of MPH collimator data sets as well, with 150 iterations and 3 subsets, with low-level bilateral regularization. Iteration number was chosen based on qualitative assessment by a medical doctor. Both the LEHR and MPH reconstruction matrix were 128x128, resulting 2.4mm and 1.7mm reconstructed isovoxel, respectively.

Comparative evaluation of clinical data

Reoriented transaxial slices covering the whole brain were presented randomly to five clinical experts with expertise in reporting brain perfusion studies, and without knowledge of the reconstruction method. The experts ranked the reconstructed images on a scale from the lowest (1) to the highest (5) image quality.

Statistical analyses

The IBM SPSS Statistics version 27software package (IBM SPSS Inc. 27, Armonk, New York) was used for data analysis. Differences of mean rank coefficients of the methods were compared using the Friedman test, with Bonferroni correction for multiple pair wise comparisons. P values below 0.05 were considered as significant.

Results

Phantom studies

Using comparable acquisition times, LEHR acquisition resulted in 5 million total counts, while MPH acquisition in 13 million total counts.

Upon visual assessment, TT3D reconstructed MPH acquisition demonstrated the best cortex/white matter contrast with the lowest noise level. The main anatomical/morphological structures were more differentiated in the MPH TT3D slices, followed by LEHR TT3D and LEHR OSEM (Figure 1).

Patient studies

Total counts for LEHR and for MPH were 4,2M (SD 0.9M) and 9.4M (SD 2.1M), respectively.

Mean rank coefficients of methods were 1.96±0.52, 2.66±0.46, 2.86±0.60, 3.62±0.55, 3.9±0.68 for FBP, STIR, LEHR_TT3D, LEHR_OSEM, MPH_TT3D respectively with the highest value for MPH_TT3D (Figure 2). After applying Bonferroni correction for multiple comparisons, rank coefficient of the following methods exhibited significant difference: MPH_TT3D-FBP (P<0.01); MPH_TT3D-STIR (P<0.05); LEHR_

OSEM-FBP (P<0.01). That means that the image quality with MPH acquisition and TT3RD reached or exceeded the image quality provided by alternative methods using parallel hole collimator (Figure 3).

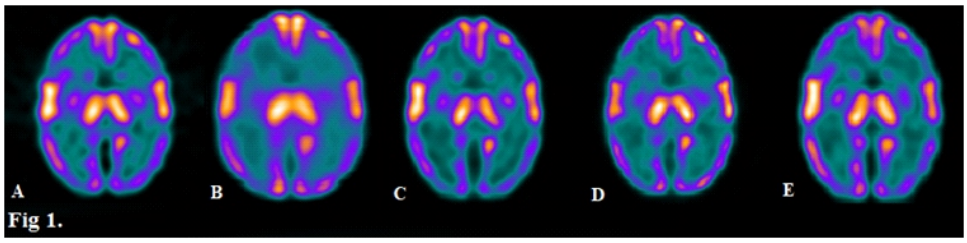

Figure 1. Representative axial slice of anthropomorphic brain phantom reconstructed with A) FBP LEHR B) STIR LEHR C) OSEM 2D LEHR D) LEHR TT3D E) MPH TT3D

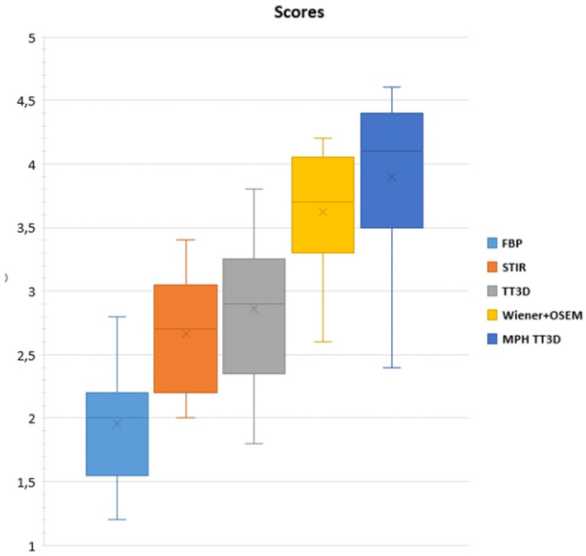

Figure 2. Box and Whisker diagram demonstrates the results of the statistical analysis of the evaluation of human brain perfusion images, demonstrating the scores the different reconstruction methods received.

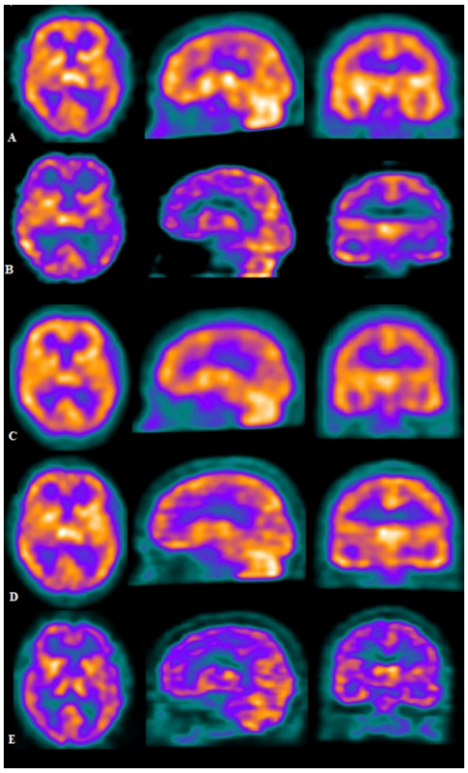

Figure 3. Representative transaxial, sagittal and coronal slices of a human brain for visual comparison. LEHR data sets were reconstructed applying A)FBP, B) STIR, C) 2D OSEM, D) TT3D, acquisition with MPH collimator reconstructed with TT3D E).

Discussion

Brain SPECT imaging technology has witnessed a significant change over the past few years [18]. Although multidetector SPECT systems equipped with parallel hole collimators are still most frequently used, some technical limitations have been identified with the use of this technology [4, 8]. Geometric resolution with parallel hole collimators is limited [19].

In order to address these limitations, growing interest has been placed on the introduction of novel technologies in order to optimize SPECT performance [7, 20].

Dedicated brain SPECT systems that might be capable of providing enhanced resolution and sensitivity were introduced into brain imaging [7]. However, owing to the limited number of cerebral perfusion SPECT studies, their clinical application is not as widespread as expected.

Novel collimator design for traditional SPECT cameras is an interesting alternative to dedicated brain SPECT devices. As both fan-, and cone-beam collimators provide favourable trade-off between resolution and sensitivity, they have significant clinical potential [4, 7, 21-24]. Currently, fan-beam collimators are the most commonly used alternatives to parallel hole collimators for brain SPECT in the clinical practice.

There are emerging promising approaches with MPH collimators that are extensively used in preclinical research with encouraging results of preliminary translation into clinical practice [7, 12-13, 25-26]. The design of MPH collimators makes a balance between sensitivity and spatial resolution, corresponding to the requirement of the particular clinical use [8].

In our present work we report on the experience with a dedicated MPH collimator set for brain perfusion imaging. Figure 1 demonstrates the reconstructed images of an anthropomorphic brain phantom. The MPH reconstructed data indicate good spatial resolution and high contrast. Multipinhole acquisition resulted in significantly higher number of total counts in both the phantom (5 Mcts vs. 13 Mcts) and the patient studies (4.2 Mcts vs 9.4 Mcts), even though the acquisition times were not absolutely identical (30 min for LEHR, and 34 min for MPH). Five medical experts performed visual assessment of images of 10 patients, they scored the scans from 1 to 5. Statistical analysis has revealed that the MPH image quality holds the highest mean score value, which is statistically significant compared to the FBP and STIR reconstructions. Figure 3 presents a representative patient image in three orthogonal views. TT3D reconstructed MPH images were depicted to provide better cortex/white matter contrast with lower noise level. We presume that the higher total counts and the better image quality would be in favour of enabling more precise lesion detection during reporting, which could support diagnosis setting and therapeutic decision making as well.

According to our knowledge, this is the first study so far to report the results of human brain perfusion SPECT with MPH collimators. The image quality achieved with MPH technology was found to reach that of carried out with conventional parallel hole collimators. The sensitivity of the used MPH collimators proved to be twice as much as the sensitivity of the parallel hole ones in the cortical regions, while its sensitivity was five times higher in the central regions compared to the conventional collimators due to the triple heads and the collimator aperture design.

Limitations

The present study reports on first clinical observations with MPH collimators. The physical parameters of this collimator have not been tested in detail. The presented evaluation is based on visual scoring only for 10 patients; the clinical relevance of our observation should be investigated in subsequent trials with more objective quantitative evaluation and with higher statistical power. In order to compare the image quality with conventional imaging, different methods of reconstruction have been used. The parameters of these reconstructions correspond to our everyday practice and their optimization was not the objective of this work.

Financial support

This research was supported by the National Grant No. GINOP-2.1.1-15-2015-00609. This work was also supported by the UK National Physical Laboratory through the National Measurement System.

Potential Conflicts of Interest

K. Kukuts, A. Oszlánszki, A. Forgács and I. Garai are full-time employees of Scanomed Nuclear Medicine Center Debrecen, Hungary, a subsidiary company of Mediso Medical Imaging Systems. J. Mester is part-time scientific advisor at Mediso Medical Imaging Systems. However, this did not bias their work as they have no financial interest in the results of the present study. There is no actual or potential conflict of interest for any of the other authors.

Ethical Approval

This work was part of a clinical trial, approved by the National Committee of Clinical Trials in Humans (OGYEI/2829-4/2017).

Bibliography

1. Zuckier LS. Radionuclide Evaluation of Brain Death in the Post-McMath Era. *J Nucl Med* 2016; 57: 1560-68.
2. Guerriero RM, Gaillard WD. Imaging modalities to diagnose and localize status epilepticus. *Seizure* 2019; 68: 46-51.
3. Álvarez-Linera Prado J, Jiménez-Huete A. Neuroimagen en demencia. Correlación clínico-radiológica. *Radiología* 2019; 61: 66-81.
4. Kapucu ÖL, Nobili F, Varrone A et al. EANM procedure guideline for brain perfusion SPECT using ^{99m}Tc-labelled radiopharmaceuticals, version 2. *Eur J Nucl Med Mol Imaging* 2009; 36: 2093-102.
5. Jaszczak RJ, Chang LT, Murphy PH. Single photon emission computed tomography using multi-slice fan beam collimators. *IEEE Trans Nucl Sci* 1979; 26: 610-8.
6. Jaszczak RJ, Floyd CE, Manglos SH et al. Cone beam collimation for single photon emission computed tomography: Analysis, simulation, and image reconstruction using filtered backprojection. *Med Phy* 1986; 13: 484-9.
7. Hutton BF. SPECT Imaging: Basics and New Trends. In: Grupen C, Buvat I,Eds. *Handbook of Particle Detection and Imaging*. Berlin, Heidelberg: Springer. 2012; 917-33.
8. Van Audenhaege K, Van Holen R, Vandenberghe S et al. Review of SPECT collimator selection, optimization, and fabrication for clinical and preclinical imaging. *Med Phys* 2015; 42: 4796-813.

9. Larsson A, Johansson L, Sundström T et al. A method for attenuation and scatter correction of brain SPECT based on computed tomography images. *Nucl Med Commun* 2003; 24: 411-20.
10. Tecklenburg K, Forgács A, Apostolova I et al. Performance evaluation of a novel multi-pinhole collimator for dopamine transporter SPECT. *Phys Med Biol* 2020; 65(16): 165015.
11. Andringa G, Drukarch B, Bol JGJM et al. Pinhole SPECT imaging of dopamine transporters correlates with dopamine transporter immunohistochemical analysis in the MPTP mouse model of Parkinson's disease. *Neuroimage* 2005; 26: 1150-8.
12. Apostolova I, Wunder A, Dirnagl U et al. Brain perfusion SPECT in the mouse: Normal pattern according to gender and age. *Neuroimage* 2012; 63: 1807-17.
13. Scherfler C, Donnemiller E, Schocke M et al. Evaluation of Striatal Dopamine Transporter Function in Rats by in Vivo β-[^{123}I]CIT Pinhole SPECT. *Neuroimage* 2002; 17: 128-41.
14. Funk T, Kirch DL, Koss JE et al. A novel approach to multipinhole SPECT for myocardial perfusion imaging. *J Nucl Med* 2006; 47: 595-602.
15. Konik A, De Beenhouwer J, Mukherjee JM et al. Simulations of a Multipinhole SPECT Collimator for Clinical Dopamine Transporter (DAT) Imaging. *IEEE Trans Radiat Plasma Med Sci* 2018; 2: 444-51.
16. Fuster BM, Falcon C, Tsoumpas C et al. Integration of advanced 3D SPECT modeling into the open-source STIR framework. *Med Phys* 2013; 40(9): 092502.
17. Thielemans K, Tsoumpas C, Mustafovic S et al. STIR: software for tomographic image reconstruction release 2. *Phys Med Biol* 2012; 57: 867-83.
18. Khalil MM, Tremoleda JL, Bayomy TB et al. Molecular SPECT Imaging: An Overview. *Int J Mol Imaging* 2011; 2011: 1-15.
19. Cherry SR, Sorenson JA, Phelps ME. *Physics in nuclear Medicine*. 4th edn. Elsevier Books. 2012.
20. Madsen MT. Recent Advances in SPECT Imaging. *J Nucl Med* 2007; 48: 661-73.
21. Accorsi R. Brain Single-Photon Emission CT Physics Principles. *Am J Neuroradiol* 2008; 29: 1247-56.
22. Li J, Jaszczak RJ, Van Mullekom A et al. Half-Cone Beam Collimation for Triple-Camera SPECT Systems. *J Nucl Med* 1996; 37: 498-502.
23. Mahowald J, Robbins P, O'Connor M. The evaluation and calibration of fan-beam collimators. *Eur J Nucl Med* 1999; 26: 314-9.
24. Tsui BM, Gullberg GT, Edgerton ER et al. Design and Clinical Utility of a Fan Beam Collimator for SPECT Imaging of the Head. *J Nucl Med* 1986; 27: 810-9.
25. Ozsahin I, Chen L, Könik A et al. The clinical utilities of multi-pinhole single photon emission computed tomography. *Quant Imaging Med Surg* 2020; 10: 2006-29.
26. Weber DA, Ivanovic M, Franceschi D et al. Pinhole SPECT: an approach to in vivo high resolution SPECT imaging in small laboratory animals. *J Nucl Med* 1994; 2: 342-8.