

More than the prostate: Intrapancreatic accessory spleen and papillary thyroid cancer detected with ^{18}F -PSMA PET/CT

**Dalveer Singh, BMedSci MBBS
(Hons) FRANZCR,
Roslyn Horneman, Bsci,
Navjot Kaur Nagra MBBS**

*Qscan Radiology Clinics (QLD), 123
Nerang Street Southport,
Queensland, Australia 4215*

Keywords: Intrapancreatic spleen
-Papillary thyroid cancer
- ^{18}F -PSMA PET/CT

Corresponding author:

Dr Dalveer Singh MBBS (Hons)
FRANZCR
Qscan Radiology 123 Nerang
Street Southport, Queensland,
Australia 4215
dsingh1386@gmail.com

Received:

29 March 2018

Accepted revised:

4 May 2018

Abstract

Objective: Prostate specific membrane antigen (PSMA) positron emission tomography diagnostic computed tomography (PET/CT) is gaining an increasing role in the staging of prostate cancer and restaging in cases of bio-chemical recurrence. Our understanding of PSMA affinity for incidental pathological and non-pathological entities is also maturing although certain cases do present as diagnostic and management dilemmas. **Subject and Methods:** We present a case of a 55 years old man with prostate adenocarcinoma, with incidentally found pancreatic and thyroid lesions showing PSMA avidity. **Results:** We were able to utilize a heat damaged red blood cell single photon emission tomography (SPET)/CT scan and ultrasound guided fine needle aspiration (FNA) to accurately diagnose co-existent thyroid papillary carcinoma and intrapancreatic accessory spleen (IPAS) tissue, respectively. The patient avoided invasive pancreatic tissue sampling and subsequent staging with fluorine-18 fluorodeoxyglucose (^{18}F -FDG) PET/CT. **Conclusion:** This is the first case to our knowledge describing both such lesions in one patient and the first case describing the use of 2-(3-[1-carboxy-5-[(6-[^{18}F]fluoro-pyridine-3-carbonyl)-amino]-pentyl]-ureido)-pentanedioic acid (^{18}F -DC-FPyL)-PSMA PET/CT to detect IPAS. Furthermore we highlight the value of nuclear medicine diagnostic work up in complex cases.

Hell J Nucl Med 2018; 21(2): 145-147

Epub ahead of print: 12 July 2018

Published online: 10 August 2018

Introduction

Intra-pancreatic accessory spleen is often a benign and an incidental finding. Histologically these have the same structure and function of a normal spleen, but are situated within the pancreas due to failure of fusion of splenic anlagen during fetal development. This results in splenic parenchymal foci separate to the main splenic body, often along the path of the splenic vessels. Published data shows an incidence accessory splenic tissue anywhere in the body in up to 10%-30% of normal subjects, with 80% found in the splenic hilum followed by 17% in the pancreas. Most intra-pancreatic accessory spleen (IPAS) are asymptomatic and pose no clinical problem. However they can be complicated by hemorrhage, spontaneous rupture, cyst formation, undergo torsion or contribute to a hematological disorder. In these cases surgical resection of the IPAS may be indicated. It is thus of vital importance to accurately diagnose IPAS in a non-invasive manner as to avoid unnecessary invasive sampling or surgical intervention [1-6].

Case Report

A 55 years old male presented for a fluorine-18 prostate specific membrane antigen (^{18}F -PSMA) PET/CT scan to investigate a rising serum prostate-specific antigen (PSA) level on a background of prostate adenocarcinoma treated with radical prostatectomy.

Prostate specific membrane antigen (PSMA) is a transmembrane protein that is over-expressed in prostate cancer cells and PSMA-binding ligands are bound to the extracellular domain of PSMA, although the transmembranous location of the binding domain and its enzyme activity enable the subsequent internalization of these ligands. In comparison to more commonly used gallium-68-labeled PSMA ligands, ^{18}F -labeled compounds offer potential advantages due to higher production capacity and improved image resolution conferred by decay properties of ^{18}F . There is growing data available on the

effectiveness and non-inferiority of ^{18}F -DCFPyL-PSMA compared to ^{68}Ga -PSMA for both initial staging of prostate cancer and restaging in suspected prostate cancer biochemical recurrence. Prostate specific membrane antigen PET/CT has shown improved sensitivity over CT, bone scintigraphy and magnetic resonance imaging (MRI) in prostate cancer nodal and metastatic staging, although can have difficulty with specificity for certain incidental findings, as our case demonstrates [7].

Two hours after an intravenous injection of 268MBq of ^{18}F -DCFPyL-PSMA, the patient was scanned from vertex to knees and subsequent intravenous iodinated contrast-enhanced CT was also performed. The images showed an intensely PSMA-avid lesion posterior to the bladder apex suspicious for a recurrent prostate malignancy (Figure 1). However there was also mild focal PSMA uptake in an 11x10mm right thyroid nodule (Figure 2) and a mildly enhancing 31x15mm lesion in the pancreatic tail (Figure 3). The thyroid nodule was later biopsied with ultrasound-guidance and found to be consistent with a papillary thyroid carcinoma (PTC), and a technetium-99m ($^{99\text{m}}\text{Tc}$)-heat damaged red blood cell (HDRBC) scan was ordered to further investigate the pancreatic lesion.

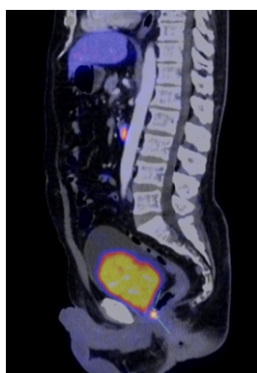


Figure 1. Sagittal fused ^{18}F -PSMA PET/CT image demonstrating focal intense PSMA uptake in the prostate gland consistent with prostate adenocarcinoma focus. No nodal disease or metastasis was present.

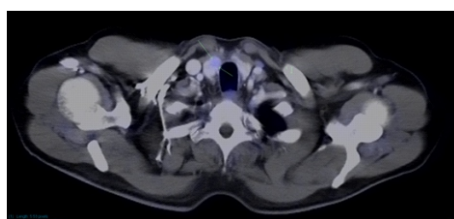


Figure 2. Axial fused ^{18}F -PSMA PET/CT image showing focal mild PSMA uptake in the right anterior thyroid lobe. This was subsequently diagnosed as papillary thyroid carcinoma with ultrasound guided FNA. No evidence of PSMA avid nodal or metastatic disease.

For the $^{99\text{m}}\text{Tc}$ -HDRBC scan, 4mL of the patient's blood was taken in a heparinized syringe and labelled using Ultratag. Subsequently the reconstituted product was damaged in a hot water bath at 49.5°C for 20min. Once cooled, 960MBq of HDRBC's were injected into the patient intravenously and 30 minutes later he underwent both static and SPET/CT

imaging of his torso. One of the spleens functions is to remove damaged blood cells. Therefore, by denaturing the erythrocytes with heat, they become stiff and get trapped in the splenic tissue because of fragmentation and spherocytosis. Normal erythrocytes will readily pass through because they are deformable [8]. The pancreatic tail lesion previously identified in the ^{18}F -PSMA scan was found to be actively functioning splenic tissue (Figure 4).

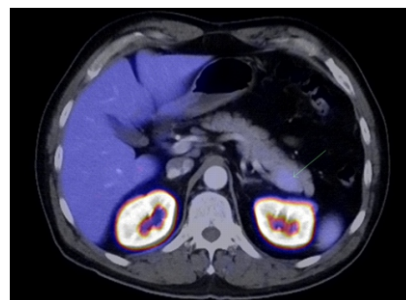


Figure 3. Axial fused ^{18}F -PSMA PET/CT image showing focal mild PSMA uptake in the tail of the pancreas, with associated mild contour bulging posteriorly on CT.

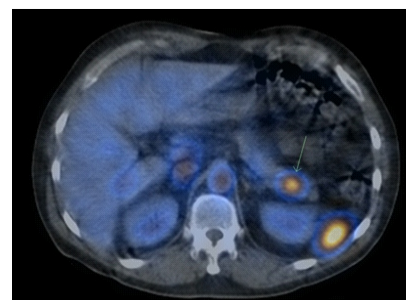


Figure 4. Axial fused SPET/CT image of $^{99\text{m}}\text{Tc}$ -HDRBC scan confirming functioning splenic tissue within the pancreatic tail and concordant with the focal PSMA uptake seen on the PET/CT

Discussion

There are multiple imaging modalities to diagnose IPAS, however a Nuclear Medicine $^{99\text{m}}\text{Tc}$ -HDRBC scan has been found to be the most sensitive and specific non-invasive method. This is because 90% of the radiopharmaceutical will be trapped by the splenic tissue, and the IPAS will not take up the radiopharmaceutical at all unless it is actively functioning splenic tissue. A $^{99\text{m}}\text{Tc}$ -sulphur colloid scan can also be used, however is less sensitive and specific, due to significant hepatic and marrow uptake of colloid, leaving only approximately 10% for splenic uptake [8]. Interestingly, intravenous immunoglobulin which is used to treat various autoimmune diseases will prevent visualization of splenic tissue unless stopped for at least 3 days prior to the $^{99\text{m}}\text{Tc}$ -HDRBC scan [9]. Contrast-enhanced CT and MRI are the other two non-invasive diagnostic modalities. IPAS will be similar to the attenuation/enhancement and signal intensity of normal splenic parenchyma in the main splenic body, on all contrast phases or sequences using CT or MRI respectively,

however other malignant pancreatic lesions such as neuroendocrine tumors, acinar cell carcinomas, solid pseudopapillary neoplasms and occasionally adenocarcinomas can appear similar. This makes a definite diagnosis difficult. Furthermore, on CT if the IPAS is <1cm then partial volume artefacts can render such foci as hypodense relative to spleen and enhancement may not be uniform or well-appreciable [3, 4, 6, 10].

For histological diagnosis, endoscopic ultrasound is the most common diagnostic approach, although is invasive. It involves the use of an endoscope and fine needle biopsy through the stomach to obtain both images and tissue samples of the IPAS. This can be a very specific test, but the biopsy sample can sometimes inadvertently pick up fragments of gastric mucosa or benign pancreatic islet cells which can impede analysis, and it also involves a general anesthetic [5, 10].

After a thorough review of the current literature, there are no case studies reporting the findings of an IPAS or PTC from an ^{18}F -PSMA PET/CT scan and very few using ^{68}Ga -PSMA. Of note is a preliminary study by Dietlein et al. (2015) [11], which found that ^{18}F -DCFPyL-PSMA and ^{68}Ga -Ga-PSMA-HBED-CC PET/CT scans were found to have very similar scan results, but ^{18}F -PSMA found marginally more suspicious lesions. Both radiopharmaceuticals target the same receptor, however they are synthesized differently and ^{18}F -PSMA has more advantageous physical properties. This includes a longer half-life (110 vs 68 minutes) and larger allowable mean injected activity (318.4MBq vs 128.3MBq). This enables imaging at later time points, allowing a higher clearance rate and less non-specific binding, thus higher signal to noise ratios. In addition, ^{18}F has lower mean positron emission energy (0.25MeV versus 0.89MeV) resulting in higher image resolution and more accurate quantification. Fluorine-18-PSMA also cleared faster from non-target tissue.

A case study by Taywade et al. (2016) [12] describes a patient who had a ^{68}Ga -PSMA scan to assess for PTC metastasis in a 50 years old male after a total thyroidectomy, negative radioiodine scan and rising thyroglobulin levels. It revealed widespread skeletal and soft tissue metastatic disease. One hypothesis for this uptake is that tumor associated neovascular endothelial cells express PSMA. This is because in endothelial cells there is activation of the transcriptional enhancer region, leading to an increased PSMA transcription and abnormal protein expression.

Demirci et al. (2017) [13] refer to a 68 years old male needing prostate cancer restaging after increasing PSA levels 6 years post a radical prostatectomy and pelvic lymph node dissection. In addition to finding multiple lymph node prostate cancer metastasis on the ^{68}Ga -PSMA scan, there was also multiple nodular, well-marginated lesions which had a high PSMA expression similar to peritoneal carcinosis within the peritoneal space. Due to a history of a splenic rupture and splenectomy after a motor vehicle accident, and the fact that PSMA is expressed in healthy splenic parenchyma, a diagnosis of splenosis was considered. A $^{99\text{mTc}}$ -HDRBC SPET/CT scan in their patient subsequently revealed the peritoneal lesions to accumulate the denatured erythrocytes, confirming splenosis. Gallium-68-octreotate and $^{99\text{mTc}}$ -octreotide have also been reported to mimic neuroendocrine tumors in

cases of IPAS [13-15].

In conclusion, this case study highlights the usefulness and comprehensive imaging evaluation that an ^{18}F -PSMA PET/CT can provide. After only one non-invasive scan, the patient was diagnosed with recurrent prostate cancer, and also detected two incidental lesions. The thyroid and pancreatic tail lesions most likely would have otherwise gone undiagnosed with conventional non-molecular imaging. The patient can now be treated in his early stages of the prostate cancer recurrence, most likely with salvage radiotherapy. Minimally invasive surgery is the most common initial management of PTC and possibly even iodine-131 treatment after that [16]. Furthermore, due to the asymptomatic nature of his IPAS, that will most likely be left in situ, avoiding unnecessary and invasive treatment.

The authors declare that they have no conflicts of interest.

Bibliography

- Ota T, Tei M, Yoshioka A et al. Intrapancreatic accessory spleen diagnosed by technetium-99m heat-damaged red blood cell SPECT. *J Nucl Med* 1997; 38(3): 494-5.
- Tourel L, Bedard J, Sawan B, Mosimann F. Case note: intrapancreatic accessory spleen mimicking a pancreatic endocrine tumour. *Can J Surg* 2010; 53(1): E1-2.
- Mortele KJ, Mortele B, Silverman SG. CT features of the accessory spleen. *Am J Roentgenol* 2004; 183(6): 1653-7.
- Katuchova J, Baumohlova H, Harbulak P et al. Intrapancreatic accessory spleen. A case report and review of literature. *J O Pancreas* 2013; 14(3): 261-3.
- Saunders TA, Miller TR, Khanafshar E. Intrapancreatic accessory spleen: utilization of fine needle aspiration for diagnosis of a potential mimic of a pancreatic neoplasm. *J Gastrointest Oncol* 2016; 7 (Suppl 1): S62.
- Spencer L, Spizarny D, Williams T. Imaging features of intrapancreatic accessory spleen. *Br J Radiol* 2010; 83(992): 668-73.
- Mena E, Lindenberg ML, Shih JH et al. Clinical impact of PSMA-based ^{18}F -DCFPyL PET/CT imaging in patients with biochemically recurrent prostate cancer after primary local therapy. *Eur J Nucl Med Mol Imag* 2018; 45(1): 4-11.
- MacDonald A, Burrell S. Infrequently performed studies in nuclear medicine: Part 1. *J Nucl Med Tech* 2008; 36(3): 132-43; quiz 145.
- Oner Tamam M, Mulazimoglu M, Sumeyye-Yavuz H et al. Negative effect of intravenous immunoglobulin administration on the scintiscans to identify accessory spleen in an idiopathic thrombocytopenic purpura patient. *Hell J Nucl Med* 2010; 13(2): 175-6.
- Bastidas AB, Holloman D, Lankarani A, Nieto JM. Endoscopic Ultrasound-Guided Needle-Based Probe Confocal Laser Endomicroscopy (nCLE) of Intrapancreatic Ectopic Spleen. *ACG Case Rep J* 2016; 3(3): 196-8.
- Dietlein M, Kobe C, Kuhnert G et al. Comparison of [^{18}F]DCFPyL and [^{68}Ga]Ga-PSMA-HBED-CC for PSMA-PET Imaging in Patients with Relapsed Prostate Cancer. *Mol Imag Biol* 2015; 17(4): 575-84.
- Taywade SK, Damle NA, Bal C. PSMA Expression in Papillary Thyroid Carcinoma: Opening a New Horizon in Management of Thyroid Cancer? *Clin Nucl Med* 2016; 41(5): e263-5.
- Demirci E, Has Simsek D, Kabasakal L, Mulazimoglu M. Abdominal Splenosis Mimicking Peritoneal Metastasis in Prostate-Specific Membrane Antigen PET/CT, Confirmed With Selective Spleen SPECT/CT. *Clin Nucl Med* 2017; 42(12): e504-5.
- Serrano-Vicente J, Infante-Torre JR, Garcia-Bernardo L et al. Pancreatic accessory spleen. False positive with $^{99\text{mTc}}$ -Octreotide. *Rev Esp Med Nucl Imag Mol* 2017; 36(1): 53-5.
- Barber TW, Dixon A, Smith M et al. Ga-68 octreotate PET/CT and Tc-99m heat-denatured red blood cell SPECT/CT imaging of an intrapancreatic accessory spleen. *J Med Imag Rad Oncol* 2016; 60(2): 227-9.
- Mitchell AL, Gandhi A, Scott-Coomes D, Perros P. Management of thyroid cancer: UK National Multidisciplinary Guidelines. *J Laryng Otol* 2016; 130(Suppl 2): S150-60.