

# Application of the alteration uptake ratio of $^{99m}\text{Tc}$ -MIBI scintigraphy for evaluating the efficacy of neoadjuvant chemotherapy in osteosarcoma patients

Zhongke Huang MD,

Cen Lou MD

Department of Nuclear Medicine,  
Sir Run Run Shaw Hospital  
Zhejiang University, Hangzhou,  
China

Keywords:  $^{99m}\text{Tc}$ -MIBI-Osteosarcoma  
-Neoadjuvant chemotherapy

## Corresponding author:

Cen Lou MD,  
Department of Nuclear Medicine,  
Sir Run Run Shaw Hospital  
Zhejiang University, Hangzhou,  
China  
3194110@zju.edu.cn

## Received:

21 January 2018

## Accepted revised:

30 March 2018

## Abstract

**Background:** We aimed to semi-quantitatively evaluate using technetium-99m methoxyisobutylisonitrile ( $^{99m}\text{Tc}$ -MIBI) scintigraphy, the efficacy of neoadjuvant chemotherapy in osteosarcoma (OS) patients. **Methods:** A hundred and two patients with OS were retrospectively included in this study. All of them underwent  $^{99m}\text{Tc}$ -MIBI scintigraphy before and after neoadjuvant chemotherapy. Semi-quantitative parameters including the uptake ratio (UR) and alteration of uptake ratio (AUR) were calculated for each patient. According to tumor necrosis rate (TNR) [1], patients were classified into three groups: a) Poor response group (grade I, TNR: less than 50%), b) Partial response group (grade II, TNR: 50%-89%) and c) Good response group (grade III, TNR: greater than 90%). The linear regression analysis of the AUR versus TNR was carried out. **Results:** Poor response, partial response and good response were found in 30, 52 and 20 patients, respectively. In the poor-response group the URpre and URpost were  $1.68\pm 0.44$  and  $1.83\pm 0.71$ , respectively and the AUR was  $-0.02\pm 0.33$ . In the partial-response group the URpre and URpost were  $2.42\pm 1.42$  and  $1.59\pm 0.71$ , respectively and the AUR was  $0.28\pm 0.18$ . In the good-response group the URpre and URpost were  $2.58\pm 0.61$  and  $1.21\pm 0.16$ , respectively and the AUR was  $0.46\pm 0.10$ . There was a statistically significant difference of the AUR between poor-response and partial-response groups ( $P<0.01$ ) and also between the poor-response and good-response groups ( $P<0.01$ ). The linear regression analysis of the AUR versus TNR showed a significantly positive correlation ( $r=0.76$ ). **Conclusion:** The AUR was significant after neoadjuvant chemotherapy in the partial-response group and in the good-response group. Furthermore, it exhibited a positive correlation with TNR. All results indicated that  $^{99m}\text{Tc}$ -MIBI scintigraphy can be used to evaluate neoadjuvant chemotherapy for OS patients.

Hell J Nucl Med 2018; 21(1): 55-59

Published online: 25 April 2018

## Introduction

Osteosarcoma is a type of malignant tumor that originates from mesenchymal tissue. It is the most common primary malignancy of the bones and the most common soft tissue tumor encountered in clinical practice. The annual incidence is about 3/1 million [1, 2]. Neoadjuvant chemotherapy for OS substantially improves patients' survival. The 5 years survival rate for patients with localized OS is approximately 50%-80% [3-5]. Even in patients with solitary pulmonary metastasis at initial presentation, the 5 years survival rate was 60% [6]. In various studies, neoadjuvant chemotherapy in patients without metastases has been shown to improve prognosis so that the 5 years survival rate is more than 90% [7, 8]. Several modalities, including computed tomography, magnetic resonance imaging, angiography, and radionuclide imaging, have been used to evaluate tumor response to neoadjuvant chemotherapy in patients with OS. There were few reports about  $^{99m}\text{Tc}$ -MIBI scintigraphy in OS during the last years. Therefore, wash-out rate was used to investigate malignant tumor in these reports [9, 10]. In this study, we aimed to semi-quantitatively evaluate the efficacy of neoadjuvant chemotherapy, in OS patients by using UR and AUR of  $^{99m}\text{Tc}$ -MIBI scintigraphy.

## Subjects and Methods

### Data acquisitions

A total of 102 patients with the diagnosis of OS confirmed by biopsy, who received

treatment between June 2008 and May 2016 were retrospectively recruited in this study. All patients gave their written informed consent. The patient population consisted of 63 males and 39 females aged from 8 to 52 years. There were 70 patients under the age of 18 and 32 patients over 18 years old (median age 19 years). Of the 102 patients, 85 suffered of conventional OS, 10 from small-cell OS and 7 from extra-skeletal OS. Fifty three patients had lesions in the lower femur, 20 patients had lesions in the upper humerus, 14 patients in the upper tibia, 8 in the middle segment of tibia and 7 in the pubic symphysis. Every patient underwent technetium-99m methoxyisobutylisonitrile ( $^{99m}\text{Tc}$ -MIBI) scintigraphy twice: before the initial neoadjuvant chemotherapy and after the last course of neoadjuvant chemotherapy before operation. Ten minutes and two hours after the intravenous (i.v.) injection of 370-740MBq of  $^{99m}\text{Tc}$ -MIBI, planar imaging was performed for 2 minutes with a single photon emission tomography (SPET) equipped with a low energy high resolution parallel hole collimator, matrix size 256×256 and pixel size 2.4mm.

### Chemotherapy

All patients were given neoadjuvant chemotherapy which was developed by our Institute of Orthopedics and is routinely used by us [11]. They were treated with 8g/m<sup>2</sup> (children received 12g/m<sup>2</sup>) of methotrexate (MTX) on the 1<sup>st</sup> and 8<sup>th</sup> days, administered i.v. over 6 hours. Tetrahydrofolic acid (THFA) was administered at 15mg/6hr for 3 days at the end of the MTX infusion. On the 15<sup>th</sup> day, cisplatin (CDDP) was administered i.v. at a dose of 90-120mg/m<sup>2</sup> every 12 hours. On the 17<sup>th</sup> day, 60mg/m<sup>2</sup> adriamycin (ADM) was infused via intravenous drip over 4 hours. On the 31<sup>st</sup> day, the second course of chemotherapy began. On the 62<sup>nd</sup> day, the operation was performed. The third course of chemotherapy was offered on the 14<sup>th</sup> day post-operation. Two or three courses of chemotherapy were administered after the operation. If the tumor necrosis rate (TNR) was more than 90%, the neoadjuvant chemotherapy regimen was offered. Otherwise, chemotherapy regimens would be changed to ifosfamide (IFO) 2mg/m<sup>2</sup> via intravenous drip for 5 days. Patients received the 2<sup>nd</sup> IFO chemotherapy at an interval of 7 days. Seven days after IFO chemotherapy, CDDP and ADM were administered following the same protocol used for the neoadjuvant chemotherapy. The histopathological response to chemotherapy was assessed based on the degree of necrosis in the largest slice of the resected tumor [12]. Grade III (TNR≥90%) was considered good response. Grade II (TNR: 50%-90%) was considered partial response; and Grade I (TNR<50%) was considered poor response.

### Statistical analysis

Uptake ratio was calculated by dividing the count density (average counts/pixel) of the lesion versus that of the contralateral normal area. The alteration of uptake ratio (AUR) was calculated as follows:  $\text{AUR}(\%) = 100 \times (\text{UR}_{\text{pre}} - \text{UR}_{\text{post}}) / \text{UR}_{\text{pre}}$ . Differences of UR, AUR among poor, partial and good responders were analyzed by Wilcoxon rank-sum test. A value of  $P < 0.05$  was considered statistically significant. We also un-

derwent a statistical analysis of the results for children and adults, females and males, respectively. Then linear regression analysis of the AUR versus TNR was also carried out.

## Results

In according to TNR, 30, 52 and 20 patients demonstrated poor response, partial response and good response, respectively (Table 1). All 102 patients had high uptake in the  $^{99m}\text{Tc}$ -MIBI imaging before the initial neoadjuvant chemotherapy. After the last neoadjuvant chemotherapy pre-operation, the radioactivity of the primary lesions decreased in 82 patients while in the others did not (Figure 1). The UR<sub>pre</sub> and UR<sub>post</sub> of the poor response group were  $1.68 \pm 0.44$  and  $1.83 \pm 0.71$ , respectively and the AUR was  $-0.02 \pm 0.33$ . The UR<sub>pre</sub> and UR<sub>post</sub> of the partial response group were  $2.42 \pm 1.42$  and  $1.59 \pm 0.71$ , respectively and the AUR was  $0.28 \pm 0.18$ . The UR<sub>pre</sub> and UR<sub>post</sub> of the good response group were  $2.58 \pm 0.61$  and  $1.21 \pm 0.16$ , respectively, and the AUR was  $0.46 \pm 0.10$ . There was a statistically significant AUR among poor response group, partial response group and good response group ( $P < 0.01$ ). The linear regression analysis of the AUR versus TNR showed a significantly positive correlation ( $r = 0.76, P = 0.02$ ) (Figure 2).

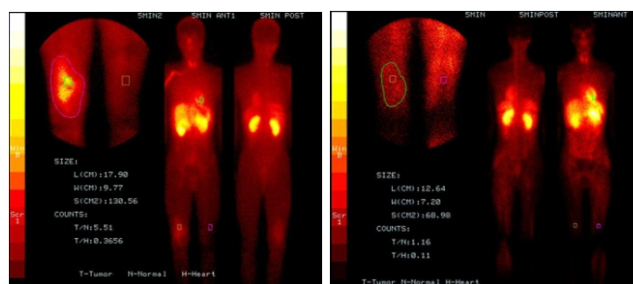


Figure 1. A 18 years old female with OS (before-after).

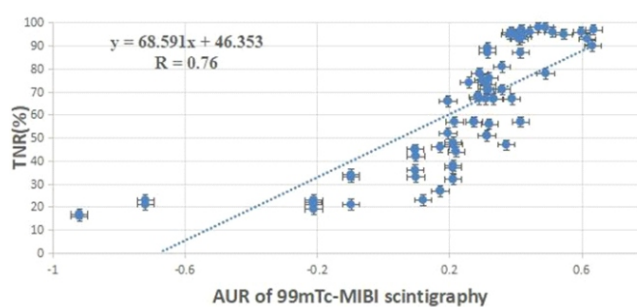


Figure 2. Linear correlation between AUR and TNR.

Eighteen, 37 and 15 children had poor response, partial response and good response, respectively (Table 2). Their AUR was  $-0.06 \pm 0.42$ ,  $0.31 \pm 0.04$  and  $0.47 \pm 0.09$ , respectively. There was a statistically significant AUR among poor response group, partial response group and good response group ( $P < 0.01$ ). The linear regression analysis of the AUR versus TNR showed a significantly positive correlation ( $r = 0.72, P = 0.09$ ).

(Figure 3). We also found that 12, 15 and 5 adults had poor response, partial response and good response, respectively. Their AUR was  $-0.03 \pm 0.31$ ,  $0.29 \pm 0.04$  and  $0.48 \pm 0.11$ , respectively. There was a statistically significant AUR among poor response group, partial response group and good response group ( $P < 0.01$ ). The linear regression analysis of the AUR versus TNR showed a significantly positive correlation ( $r = 0.78$ ,  $P = 0.00$ ) (Figure 4). There was no statistically significant difference in AUR between children and adults ( $P = 0.63$ ).

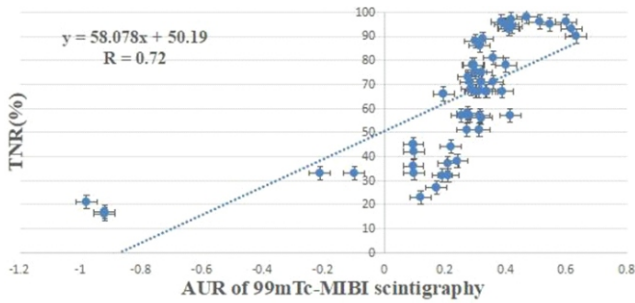


Figure 3. Linear correlation between AUR and TNR in children.

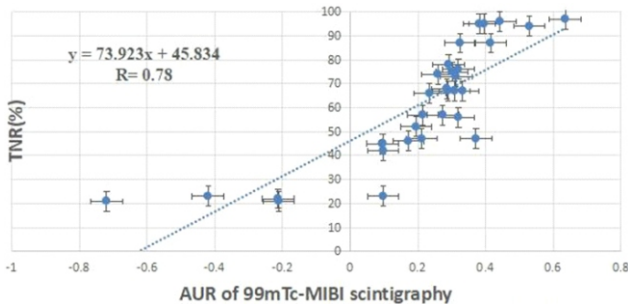


Figure 4. Linear correlation between AU and TNR in adults.

At the same time, we found that 15, 35 and 13 male patients had poor response, partial response and good response, respectively (Table 3). Their AUR was  $-0.03 \pm 0.40$ ,  $0.31 \pm 0.05$  and  $0.48 \pm 0.09$ , respectively. There was a statistically significant AUR among poor response group, partial response group and good response group ( $P < 0.01$ ). The linear regression analysis of the AUR versus TNR showed a significantly positive correlation ( $r = 0.71$ ,  $P = 0.12$ ) (Figure 5). We also found that 15, 17 and 7 female patients had poor response, partial response and good response, respectively and their AUR was  $-0.06 \pm 0.37$ ,  $0.29 \pm 0.05$  and  $0.46 \pm 0.09$ , respectively. There was a statistically significant difference in AUR among poor response group, partial response group and good response group ( $P < 0.01$ ). The linear regression analysis of the AUR versus TNR showed a significantly positive correlation ( $r = 0.77$ ,  $P = 0.05$ ) (Figure 6). However, there was no statistically significant difference in AUR between male and female patients ( $P = 0.56$ ).

## Discussion

Before the 1970s, amputation was the only treatment for

OS. Due to the wide application of neoadjuvant chemotherapy, we have gained much experience in the early diagnosis of OS. Thus, many patients with OS have been treated effectively by neoadjuvant chemotherapy so unnecessary amputation has been avoided. Preoperative neoadjuvant chemotherapy can postpone the development of the primary tumor but can also treat potential small metastases.

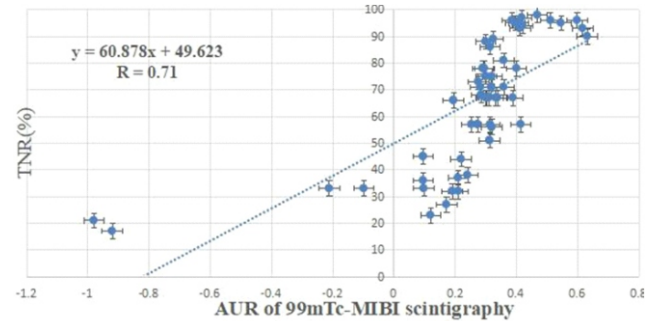


Figure 5. Linear correlation between AUR and TNR in males.

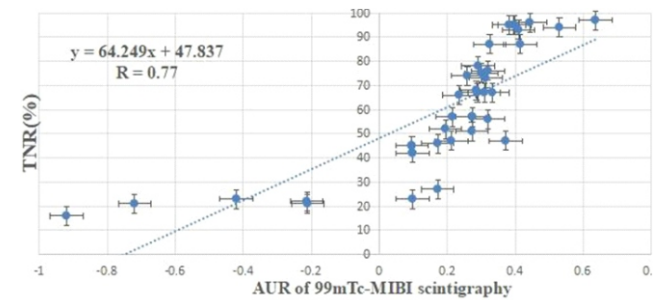


Figure 6. Linear correlation between AUR and TNR in females.

Tumor necrosis rate, an index proposed by Rosen et al. (19-82) [13] has become the most accurate method to assess the efficacy of neoadjuvant chemotherapy for OS. Traditional static imaging has a limited use for the evaluation of the efficacy of neoadjuvant chemotherapy for OS, because of the small reduction in tumor size. Many researchers reported that thallium-201 ( $^{201}\text{Tl}$ ) scintigraphy was superior to other imaging techniques in evaluating residual or recurrent OS [14,15]. However, the physical properties of  $^{99\text{m}}\text{Tc-MIBI}$  are much better than those of  $^{201}\text{Tl}$  and also  $^{99\text{m}}\text{Tc-MIBI}$  as a lipophilic monovalent cation complex can passively diffuse through the cell membrane and accumulate in mitochondria. The metabolic product of  $^{99\text{m}}\text{Tc-MIBI}$  is succinic acid, which as a salt enhances its ability to combine with mitochondria. Because malignant tumor cells have a vigorous metabolism, a large number of mitochondria can take up  $^{99\text{m}}\text{Tc-MIBI}$ ; therefore, it is widely used to diagnose tumors in our clinic.

Generally,  $^{99\text{m}}\text{Tc-MIBI}$  scintigraphy is used for early-phase and delayed-phase imaging studies. Goto et al. (2002) [16] reported that the early-phase of  $^{201}\text{Tl}$  scintigraphy was more suitable for monitoring tumor chemotherapy response. The authors analyzed the early and delayed-phases from 13 cases of OS before and after chemotherapy and found that the correlation coefficient in relation to the TNR of the early-phase was 0.801 and the correlation coefficient of the delayed-phase was 0.664. Therefore, our study only focused

**Table 1.** UR and AUR after the last course of preoperative chemotherapy.

Response	Cases	URpre (mean±SD)	URpost (mean±SD)	AUR (mean±SD)	TNR (%) (mean±SD)
Grade III	20	2.58±0.61	1.21±0.16	0.46±0.10	94.05±4.07
Grade II	52	2.42±1.42	1.59±0.71	0.28±0.18	67.26±12.06
Grade I	30	1.68±0.44	1.83±0.71	-0.02±0.33	34.03±10.20

AUR: Alteration of uptake ratio, TNR: Tumor necrosis rate

**Table 2.** AUR after the last course of preoperative chemotherapy (age).

Age	Response	Cases	AUR (mean±SD)	TNR (%) (mean±SD)
≤18	Grade III	15	0.47±0.09	94.67±1.95
	Grade II	37	0.31±0.04	68.00±10.30
	Grade I	18	-0.06±0.42	32.28±9.05
>18	Grade III	5	0.48±0.11	95.40±1.14
	Grade II	15	0.29±0.04	69.19±9.15
	Grade I	12	-0.03±0.31	35.58±12.07

AUR: Alteration of uptake ratio, TNR: Tumor necrosis rate

**Table 3.** AUR after the last course of preoperative chemotherapy (gender).

Gender	Response	Cases	AUR (mean±SD)	TNR (%) (mean±SD)
Male	Grade III	13	0.48±0.09	94.77±2.05
	Grade II	35	0.31±0.05	68.77±10.00
	Grade I	15	-0.03±0.40	33.07±8.44
Female	Grade III	7	0.46±0.09	95.00±1.29
	Grade II	17	0.29±0.05	67.5±10.98
	Grade I	15	-0.06±0.37	34.13±12.16

AUR: Alteration of uptake ratio, TNR: Tumor necrosis rate

for the early-phase images in <sup>99m</sup>Tc-MIBI scintigraphy.

The results of our study with <sup>99m</sup>Tc-MIBI scintigraphy showed that AUR values of most (80.39%) of the primary lesions were significantly decreased after neoadjuvant chemotherapy, especially in patients who exhibited a good histological response. Furthermore, linear correlation analysis showed that the AUR values correlated with TNR (r=0.76, P=0.02). We also found that there was no statistically significant AUR between male and female patients, or between children and adults. All these indicated that <sup>99m</sup>Tc-MIBI scintigraphy can well evaluate the efficacy, which was not affected by age and gender. Therefore, it was very important to find out the changes of radioactivity in the tumor lesion, obtain the AUR value and sequentially, determine the efficacy of chemotherapy with <sup>99m</sup>Tc-MIBI scintigraphy. The efficacy of neoadjuvant chemotherapy should be evaluated as early as possible, to guide decisions regarding postoperative chemotherapy and selection of the operation method. If the AUR of <sup>99m</sup>Tc-MIBI is significantly reduced after neoadjuvant chemotherapy, the original chemotherapy regimens can be used in postoperative chemotherapy, and a more appropriate operation plan can be adopted. Otherwise, chemotherapy regimens should be modified to improve their efficacy.

In conclusion, it is the opinion of the authors that <sup>99m</sup>Tc-MIBI scintigraphy by using tumor uptake can reliably predict chemotherapeutic efficacy during neoadjuvant chemotherapy of OS and suggest the proper technique for the operation that may follow.

The authors declare that they have no conflicts of interest.

### Bibliography

- Menedez LR, Fideler BM, Mira J. Thallium-201 scanning for the evaluation of osteosarcoma and soft-tissue sarcoma. A study of the evaluation and predictability of the histological response to chemotherapy. *J Bone Joint Surg Am* 1993; 75(4): 526-31.
- Mirabello L, Troisi RJ, Savage SA. Osteosarcoma incidence and survival rates from 1973 to 2004: data from the Surveillance, Epidemiology and End Results Program. *Cancer* 2009; 115(7): 1531-43.
- Kubo T, Shimose S, Fujimori J et al. Quantitative thallium-201 scintigraphy for prediction of histological response to neoadjuvant chemotherapy in osteosarcoma; systematic review and meta-analysis. *Surg Oncol* 2015; 24(3): 194-9.
- Gharehdaghi M, Dabbagh Kakhki VR et al. Is <sup>99m</sup>Tc-MIBI scintigraphy a predictor of response to pre-operative neoadjuvant chemotherapy in Osteosarcoma? *Asia Ocean J Nucl Med Biol* 2013; 1(2): 22-7.
- Miwa S, Takeuchi A, Shirai T et al. Prognostic value of radiological res-

- ponse to chemotherapy in patients with osteosarcoma. *PLoS One* 2013; 8(7): e70015.
6. Wakabayashi H, Saito J, Taki J et al. Triple-phase contrast-enhanced MRI for the prediction of preoperative chemotherapeutic effect in patients with osteosarcoma: comparison with  $^{99m}\text{Tc}$ -MIBI scintigraphy. *Skeletal Radiol* 2016; 45(1): 87-95.
  7. Sugawara Y, Kikuchi T, Kajihara M et al. Thallium-201 scintigraphy in bone and soft-tissue tumors: a comparison of dynamic, early and delayed scans. *Ann Nucl Med* 2005; 19(6): 461-8.
  8. Huang ZK, Lou C, Shi GH et al.  $^{201}\text{Tl}$  and  $^{99m}\text{Tc}$ -MIBI scintigraphy in evaluation of neoadjuvant chemotherapy for osteosarcoma. *J Zhejiang University (Medical Sciences)* 2012; 41(2): 183-7, 191.
  9. Gharehdaghi M, Dabbagh Kakhki VR, Khooei A et al. Is  $^{99m}\text{Tc}$ -MIBI scintigraphy a predictor of response to pre-operative neoadjuvant chemotherapy in Osteosarcoma? *Asia Oceania J Nucl Med Biol* 2013; 1(2): 22-7.
  10. Sohaib M, Wiqar MA, Ali MK et al. A single  $^{99m}\text{Tc}$ -MIBI study to predict response to neoadjuvant treatment in sarcoma patients. *Hell J Nucl Med* 2011; 14(2): 140-5.
  11. Yang DS, Fan SW, Tao HM et al. The assessment of the effectiveness of the adjuvant chemotherapy regimen for the treatment of osteosarcoma. *Chin J Orthop* 2000; 20(1): 35-9.
  12. Huang ZK, Lou C, Fang XQ et al. The value of Thallium-201 Scintigraphy in assessment of neoadjuvant chemotherapy for osteosarcoma. *Chin J Oncol* 2009; 31(10): 769-72.
  13. Rosen G, Caparros B, Huvos AG et al. Neoadjuvant chemotherapy for osteogenic sarcoma: selection of postoperative adjuvant chemotherapy based on the response of the primary tumor to neoadjuvant chemotherapy. *Cancer* 1982; 49(6): 1221-30.
  14. Inaki A, Taki J, Wakabayashi H et al. Thallium-201 scintigraphy for the assessment of long-term prognosis in patients with osteosarcoma. *Ann Nucl Med* 2012; 26(7): 545-50.
  15. Wakabayashi H, Taki J, Inaki A et al. Prognostic value of  $^{99m}\text{Tc}$ -MIBI scintigraphy performed during middle course of the neoadjuvant chemotherapy in patients with malignant bone and soft tissue tumors. *Clin Nucl Med* 2012; 37(1): 1-8.
  16. Goto Y, Ihara K, Kawauchi S et al. Clinical significance of thallium-201 scintigraphy in bone and soft tissue tumors. *J Orthop Sci* 2002; 7(3): 304-12.



Bartolomé Esteban Murillo. *Child and dog (Nino con perro)*. Oil in canvas 74x60cm. 1655-1660.