

Tumoricidal effect and pain relief after concurrent therapy by strontium-89 chloride and zoledronic acid for bone metastases

Kenkichi Baba^{1,2} MD,
Hayato Kaida³ MD,
Chikayuki Hattori^{2,4} MD,
Koichiro Muraki⁴ MD,
Tomoko Kugiyama⁴ MD,
Hiromasa Fujita⁵ MD,
Masatoshi Ishibashi⁶ MD

1. Department of General Diagnosis and Treatment, Fukuoka Kieikai Hospital, Chihaya 5-11-5, Higashiku, Fukuoka City, Fukuoka, 813-0044, Japan,

2. Department of Radiology, Saiseikai Hita Hospital, Ohazamiwa 643-7, Hita City, Oita, 877-1291, Japan,

3. Department of Radiology, Kindai University Faculty of Medicine, Ohnohigashi 377-2, Osakasayama City, Osaka, 589-8511, Japan,

4. Department of Radiology, Kurume University School of Medicine, Asahi-machi 67, Kurume City, Fukuoka, 830-0011, Japan,

5. Department of Surgery, Fukuoka Wajiro Hospital, Wajirogaoka 2-2-75, Higashiku, Fukuoka City, Fukuoka, 811-0213, Japan,

6. Division of Nuclear Medicine and PET center, Department of Radiology, Fukuoka Tokushukai Medical Center, Sugukita 4-5, Kasuga City, Fukuoka, 816-0864, Japan

Keywords: Bone metastases - Strontium-89 chloride - Zoledronic acid - Pain relief - Tumoricidal effect

Corresponding author:

Hayato Kaida MD
Department of Radiology, Kindai University Faculty of Medicine, Ohnohigashi 377-2, Osakasayama City, Osaka 589-8511, Japan
Telephone: +81-(72)-366-0221,
FAX: +81-(72)-367-1685
kaida@med.kindai.ac.jp

Received:

7 January 2018

Accepted revised:

9 February 2018

Abstract

Objective: The purpose of this study was to investigate the palliative and tumoricidal effects of concurrent therapy of strontium-89 chloride (⁸⁹SrCl₂) and zoledronic acid (ZA) for painful bone metastases. **Subjects and Methods:** Fifty-one patients with painful bone metastases prostate cancer (n=17), lung cancer (n=13), breast cancer (n=12), other cancers (n=9) were treated. Bone metastases was confirmed in all patients by technetium-99m hydroxymethylene diphosphonate (^{99m}Tc-HMDP) bone scintigraphy. The numeric rating scale (NRS) and performance status (PS) were used to assess the degree of pain and patients' physical condition. The extent of bone metastases was assessed with imaging modalities including CT, MRI and/or ^{99m}Tc bone scintigraphy before treatment and 2 or 3 months after. **Results:** The pain relief response of ⁸⁹SrCl₂ with ZA for bone metastases was 94% (48/51) from 1 to 3 months after treatment. The tumoricidal effect of concurrent therapy by ⁸⁹SrCl₂ with ZA for painful bone metastases was 8/22 as shown by imaging modalities and the rate of non-progressive disease (non-PD) was 19/22. Pain due to bone metastases assessed with the NRS was significantly improved (P<0.001) in many types of primary cancer, including prostate, breast and lung cancers. **Conclusion:** Concurrent therapy of ⁸⁹SrCl₂ with ZA may offer not only pain relief, but also a tumoricidal effect for painful bone metastases.

Hell J Nucl Med 2018; 21(1): 15-23

Epub ahead of print: 20 March 2018

Published online: 25 April 2018

Introduction

Bone metastases is frequently observed in patients with advanced cancer with an incidence were of 65% in patients with prostate or breast cancer, and 35% in those with advanced lung, thyroid and renal cell cancer [1]. Bone metastases frequently cause skeletal-related events (SREs) such as pathological fractures, spinal cord compression or vertebral collapse, severe bone pain and hypercalcemia which worsen patients' quality of life (QOL) and shortens their survival [2]. The management of painful bone metastases consists of multidisciplinary approaches including systemic analgesics, hormones, bisphosphonates, denosumab, chemotherapy, steroids, external beam radiotherapy (RT), radiofrequency ablation and surgery [3, 4]. However, the management of bone metastases is not standardized and the above approaches are not always effective, especially at the late stage of the disease having multiple bone metastases.

The use of radiopharmaceuticals with avidity to selectively localize in the metastatic skeletal sites, such as strontium-89 chloride (⁸⁹SrCl₂), rhenium-186-hydroxy ethylene diphosphonate (¹⁸⁶Re-HEDP) and samarium-153-ethylene diamine tetramethylene (¹⁵³Sm-EDTMP), is widely accepted to reduce the pain caused by bone metastases [5]. Strontium-89 is a calcium (Ca) homolog that accumulates in bone-metastatic lesions that have enhanced Ca metabolism. Strontium-89 is a radionuclide with a physical half-life of 50.5 days. It emits β-rays with an energy of 1.49MeV and mean energy range of 2.4mm. The uptake of strontium-89 in bone metastases is 2 to 25 times higher than that in normal bone marrow. Strontium-89 is also used to relieve pain caused by bone metastases and has also demonstrated tumoricidal action [6-8].

Zoledronic acid (ZA) is a third-generation nitrogen-containing bisphosphonate binding to hydroxyapatite. It induces dysfunction and apoptosis of osteoclasts, reduces the number of osteoclasts, and inhibits bone re-absorption. It is reported that ZA reduces the risk of SREs in patients with bone metastases and delays its onset [9]. There are a few reports that ZA has an anti-angiogenic effect and tumoricidal effect [10, 11].

There are also a few reports concerning pain relief using the combination of $^{89}\text{SrCl}_2$ with ZA for bone metastatic patients [12, 13]. To our knowledge, the tumoricidal effect of this concurrent therapy for patients with painful bone metastases has not yet been fully investigated. The purpose of the present study was to investigate, in patients with bone metastases from various cancers, whether concurrent therapy of $^{89}\text{SrCl}_2$ with ZA is effective for pain relief and whether it has a tumoricidal effect.

Subjects and Methods

Patients

Patients who received concurrent therapy of $^{89}\text{SrCl}_2$ and ZA for painful bone metastases at Saiseikai Hita Hospital during the period from March 2010 to July 2013 were enrolled in the present prospective study. Written informed consent was obtained from all patients before initiation of treatment. The study was approved by the Institutional Review Board. Complete blood counts and serum chemistry tests were performed. Patients who met the following criteria were excluded from the present study: a) white blood cell counts less than $2000/\text{mm}^3$, b) platelet counts less than $75000/\text{mm}^3$, c) hemoglobin less than 9g/dL , d) serum creatinine greater than 2.0mg/dL or creatinine clearance less than 30mL/min . All patients underwent technetium-99m hydroxymethylene diphosphonate ($^{99\text{m}}\text{Tc-HMDP}$) bone scintigraphy before treatment. Pain equivalent to findings in the bone scintigraphy was confirmed by a physicians' interview before treatment.

The study population consisted of 51 patients (31 male and 20 female) with a median age of 74 years (range, 44-89). Primary lesions of painful bone metastases patients included prostate cancer ($n=17$), breast cancer ($n=12$), lung cancer ($n=13$), hepatocellular carcinoma (HCC) ($n=3$), gastric cancer ($n=2$), malignant fibrous histiocytoma (MFH) ($n=1$), pancreatic cancer ($n=1$), uterine cancer ($n=1$) and rectal cancer ($n=1$).

Treatment

Radioactive strontium-89 chloride was intravenously administered at a dose of 2MBq/kg with a median dose of 108MBq/body ($62\text{-}141\text{MBq}$). Zoledronic acid was also intravenously (i.v) administered every 3 weeks at a dose of 3 or 4mg/body in 100mL of saline solution. The median duration of administration of ZA was 3 months (2-23 months). Before concurrent therapy of $^{89}\text{SrCl}_2$ with ZA, 14 patients had undergone radiotherapy: 2 with prostate cancer, 6 with lung cancer, 2 with breast cancer and 3 each with pancreatic cancer, HCC and rectal cancer. Thirty-seven patients had undergone prior chemotherapy: 16 with prostate cancer, 7 with lung cancer, 11 with breast cancer, 2 with HCC and 1 with pancreatic cancer. Bone metastases occurred or persisted in all patients even after radiotherapy or chemotherapy. During several months of concurrent therapy with $^{89}\text{SrCl}_2$ and ZA and thereafter, no other anti-cancer treatment such as radio-

therapy or chemotherapy was performed. The patients who underwent external radiotherapy waited at least three months before receiving $^{89}\text{SrCl}_2$ with ZA.

Bone scintigraphy

Technetium-99m hydroxymethylene diphosphonate (NihonMedi-Physics Co., Ltd., Nishinomiya, Japan) was administered at a dose of 555MBq in all patients. Whole-body images taken 3 hours after radiotracer injection were recorded with a gamma camera (E.CAM, Siemens Medical Systems, Inc., scan speed 10cm/min , matrix 256×1024). The whole-body field was digitally recorded in anterior and posterior views (256×1024) on a dedicated computer system. Energy discrimination was provided by a 10% window centered on the 140keV of $^{99\text{m}}\text{Tc}$.

^{89}Sr imaging with bremsstrahlung

Strontium-89 imaging with bremsstrahlung was examined within 2 to 4 weeks after $^{89}\text{SrCl}_2$ administration. It visualizes ^{89}Sr β -rays damping radiation showing the distribution of $^{89}\text{SrCl}_2$ and was compared with the $^{99\text{m}}\text{Tc}$ accumulation in the bone scintigraphy to detect changes in disease status. Anterior and posterior views of whole-body images were recorded with a gamma camera with a medium-energy collimator (E.CAM, Siemens Medical Systems, Inc., scan speed 10cm/min , matrix 256×1024). Energy discrimination was provided by a 100% window centered on the 300keV peak.

Clinical assessment of painful bone metastases

All patients received blood tests and be interviewed every two weeks until two months after the treatment. The severity of pain due to bone metastases was assessed with the numeric rating scale (NRS) [14]. The patients' physical condition was assessed with the performance status (PS) scale [15]. To assess the clinical therapeutic effect, NRS and PS scores before and after treatment were compared.

Imaging assessment of tumoricidal effects

Computed tomography (CT), magnetic resonance imaging (MRI) and bone scintigraphy were examined before and 2 or 3 months after treatment. The tumoricidal effect of the treatment on bone metastases was evaluated according to the Response Evaluation Criteria in Solid Tumors (RECIST) criteria [16]. In this study, "responders" had a complete response (CR) or partial response (PR).

Toxicity

To assess bone marrow toxicity, minimum leukocyte and platelet counts in the three months after the administration of $^{89}\text{SrCl}_2$ and ZA were examined. Toxicities were graded with the Common Terminology Criteria for Adverse Events (CTCAE) version 4.0.

Statistical analysis

The comparison of NRS and PS before and after treatment was analyzed with the Wilcoxon signed rank sum test using SPSS version 19.0 software (IBM Inc, Armonk, New York, USA). P-values less than 0.05 were defined as statistically sig-

nificant.

Results

Evaluation of pain relief using NRS and PS

The median NRS significantly decreased after the treatment; it was 7 before treatment and 3 after treatment ($P<0.001$). This decrease in NRS was observed regardless of the primary cancer type: from 7 to 1 for prostate cancer ($P<0.001$), 7 to 2 for lung cancer ($P<0.001$), 6.5 to 3 for breast cancer ($P<$

0.001), and 7 to 3 for other cancers ($P=0.008$) (Tables 1-4).

In 48 of 51 patients, NRS was improved after $^{89}\text{SrCl}_2$ +ZA administration. In 2 of the remaining three patients, NRS was not changed, and in one patient, NRS was increased after $^{89}\text{SrCl}_2$ +ZA administration. The response rate of pain relief for $^{89}\text{SrCl}_2$ +ZA was 94% (48/51). There was no difference in PS before and after treatment for all cancers ($P=0.417$ for prostate cancer, $P=0.540$ for lung cancer, $P=0.755$ for breast cancer and $P=0.796$ for other cancers) (Tables 1-4).

Evaluation of tumoricidal effects using imaging modalities.

Table 1. The characteristics of prostate cancer patients with bone metastases.

Case	Age	Radiotherapy	Chemotherapy	$^{89}\text{SrCl}_2$	ZOL period	Follow-up	Survival	NRS	PS	Response
1	74		BCL+LA	124	8	10	Death	7→3	0→0	
2	89			110	2	2	Death	8→0	2→2	
3	75		BCL+LA	128	14	16	Death	5→1	1→0	PR
4	77		BCL+LA	80	16	18	Death	7→3	1→1	SD
5	74		BCL+LA	108	23	25	Death	5→1	0→0	
6	76		BCL+LA	100	17	19	Death	7→1	0→0	SD
7	63	30	BCL+LA	78	8	9	Death	7→1	1→1	PR
8	77		BCL+LA	120	5	8	Death	6→3	0→0	PR
9	81		LA	72	2	6	Death	6→2	1→1	
10	80		LA	95	4	8	Death	6→1	1→1	
11	78		BCL+LA	110	8	12	Death	7→0	0→0	PR
12	78	30	LA	141	5	6	Death	6→2	1→1	
13	79		LA	124	3	22	Death	7→1	1→0	
14	63		BCL+LA	118	3	20	Death	5→1	1→0	
15	81		LA	98	2	3	Death	8→5	3→3	
16	79		LA	93	3	5	Death	6→3	2→2	
17	78		BCL+LA	120	3	22	Alive	8→2	2→1	

The unit of $^{89}\text{SrCl}_2$ and that of duration of ZOL period are MBq and month, respectively. The unit of radiotherapy and that of duration of follow-up are Gy and month, respectively. $^{89}\text{SrCl}_2$: Strontium-89 chloride, ZOL: Zoledronic acid, NRS: Numeric rating scale, PS: Performance status, BCL: Bicalutamide, LA: Leuprorelin acetate, Radiotherapy: External radiotherapy, PR: Partial response, SD: Stable disease.

Table 2. The characteristics of lung cancer patients with bone metastases.

Case	Age	Gender	Radiotherapy	Chemotherapy	⁸⁹ SrCl ₂	ZOL period	Follow-up	Survival	NRS	PS	Response
1	70	F			128	2	4	Death	6→4	1→1	
2	84	M	20		141	3	5	Death	8→1	2→1	
3	77	F			141	7	8	Death	7→2	1→1	
4	85	M		CDBCA+GEM	120	11	12	Death	5→1	0→0	SD
5	74	M	20	CDDP+VNR	110	3	24	Death	8→2	0→0	SD
6	70	M	30	CDDP+TXL	120	4	4	Death	9→5	0→0	SD
7	70	F	20	Gefitinib	130	4	37	Death	5→2	0→0	PR
8	55	M		CBDCA+TXL	141	16	19	Death	5→0	1→1	PR
9	75	M	30		110	3	4	Death	7→7	1→1	PD
10	89	F	20		62	3	3	Death	7→5	0→0	
11	79	M		UFT	100	3	4	Death	5→3	0→0	PR
12	63	M			80	5	1	Death	8→6	2→3	
13	68	F		DOC	96	17	23	Death	8→2	0→0	PR

The unit of ⁸⁹SrCl₂ and that of duration of ZOL period are MBq and month, respectively. The unit of radiotherapy and that of duration of follow-up are Gy and month, respectively. ⁸⁹SrCl₂: Strontium-89 chloride, ZOL: Zoledronic acid, Radiotherapy: External radiotherapy, CDDP: Cis-diamminedichloroplatinum, GEM: Gemcitabine, VNR: Vinorelbine, TXL: Paclitaxel, CDBCA: Carboplatin, UFT: Uracil-tegafur, DOC: Docetaxel, SD: Stable disease, PR: Partial response, NRS: Numeric rating scale, PS: Performance status.

Table 3. The characteristics of breast cancer patients with bone metastases.

Case	Age	Radiotherapy	Chemotherapy	⁸⁹ SrCl ₂	ZOL period	Follow-up	Survival	NRS	PS	Response
1	61		ATZ	80	4	4	Death	7→7	1→1	
2	44		Trastuzumab	106	8	8	Death	8→5	0→0	
3	75			88	3	3	Death	8→5	1→1	
4	63		Fulvestrant	100	2	2	Death	8→6	0→0	
5	58	20	BEV, PTX	108	12	13	Death	7→2	0→0	PR
6	63		Trastuzumab +PTX	86	12	27	Alive	6→1	1→1	SD
7	66	20	ATZ	112	10	10	Death	5→1	0→0	SD
8	59		Fulvestrant	121	3	22	Death	8→3	0→0	SD
9	84		ATZ	86	3	25	Death	5→1	0→0	

10	59	Anastrozole	97	3	21	Death	5→4	1→1
11	49	Tamoxifen	110	2	11	Death	6→2	1→1
12	63	Anastrozole	100	3	20	Death	5→3	1→0

The unit of $^{89}\text{SrCl}_2$ and that of duration of ZOL period are MBq and month, respectively. The unit of radiotherapy and that of duration of follow-up are Gy and month, respectively. $^{89}\text{SrCl}_2$: Strontium-89 chloride, ZOL: Zoledronic acid, ATZ: Anastrozole, PTX: Paclitaxel, BEV: Bevacizumab, PR: Partial response, SD: Stable disease, PS: Performance status, NRS: Numeric rating scale.

Table 4. The characteristics of other tumors patients with bone metastases.

Case	Age	Gender	Radiotherapy	Chemotherapy	Tumor	$^{89}\text{SrCl}_2$	ZOL period	Follow-up	Survival	NRS	PS	Response
1	81	F			Gastric cancer	98	2	4	Death	7→2	2→2	
2	76	F			MFH	86	3	3	Death	8→5	2→2	
3	65	M	30	GEM	Pancreatic cancer	114	3	5	Death	7→3	1→1	SD
4	68	M			HCC	86	7	9	Death	7→3	1→1	PD
5	63	M		TACE (Epi+ADM)	HCC	116	3	18	Death	6→3	0→0	SD
6	63	M	30	DDP-H+5FU	HCC	141	3	4	Death	7→8	0→0	PD
7	77	F			Uterine cancer	86	3	3	Death	8→5	1→1	SD
8	67	M	30		Rectal cancer	106	3	8	Death	5→5	1→1	
9	80	M			Gastric cancer	121	3	10	Death	5→3	1→0	

The unit of $^{89}\text{SrCl}_2$ and that of duration of ZOL period are MBq and month, respectively. The unit of radiotherapy and that of duration of follow-up are Gy and month, respectively. $^{89}\text{SrCl}_2$: Strontium-89 chloride, ZOL: Zoledronic acid, GEM: Gemcitabine, TACE: Transcatheter arterial chemoembolization, Epi-ADM: Epirubicin-adriamycin, DDP-H: Fine-powder formulated cisplatin (cis-diammineedichloro-platinum), 5-FU: Fluorodeoxyuridine-5-monophosphate, SD: Stable disease, PD: Progressive disease, NRS: Numeric rating scale, PS: Performance status, MFH: Malignant fibrous histiocytoma, HCC: Hepatocellular carcinoma.

In 22 patients, the tumoricidal efficacy of the concurrent therapy of $^{89}\text{SrCl}_2$ with ZA for bone metastases could be assessed with CT, MRI and/or $^{99\text{m}}\text{Tc}$ bone scintigraphy; this included 6 prostate, 7 lung, 4 breast cancer, and 5 other cancers (Tables 1-4). Its effect was defined as PR in 8 patients (36%), stable disease (SD) in 11 patients (50%), and as progressive disease (PD) in 3 patients (14%). The rate of non-PD was 86% (19/22). Representative cases are shown (Figures 1-3).

^{89}Sr imaging with bremsstrahlung

In 12 of 51 patients who underwent ^{89}Sr imaging with bremsstrahlung, $^{89}\text{SrCl}_2$ accumulated in bone-metastatic lesions

that had shown $^{99\text{m}}\text{Tc}$ -HMDP uptake. Eleven of those 12 patients were PR or SD. A representative case of ^{89}Sr imaging with bremsstrahlung is shown (Figure 4).

Adverse events

Adverse events observed during 1-3 months of follow-up after treatment were anemia in one patient and post-therapy transient pain suggestive of a flare phenomenon in 5 patients.

Survival

The prognosis of patients was investigated with their medical

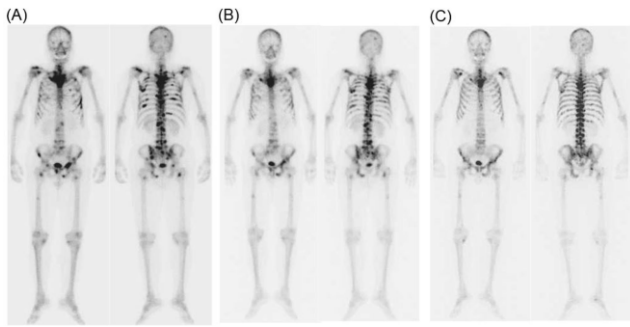


Figure 1. The Tc-99m HMDP bone scintigraphy of a 78 years old man with bone metastases from prostate cancer (A). $^{89}\text{SrCl}_2$ (110MBq) was administered twice every three months, and Zoledronic acid (ZA) at 3mg/body was administered every 4 weeks. The bone scintigraphy three months (B) and six months (C) after treatment shows an improvement of multiple bone metastases. The Numeric Rating Scale (NRS) score decreased from 7 before the treatment to 0 six months after the treatment. The tumoricidal effect was assessed to be partial response (PR).

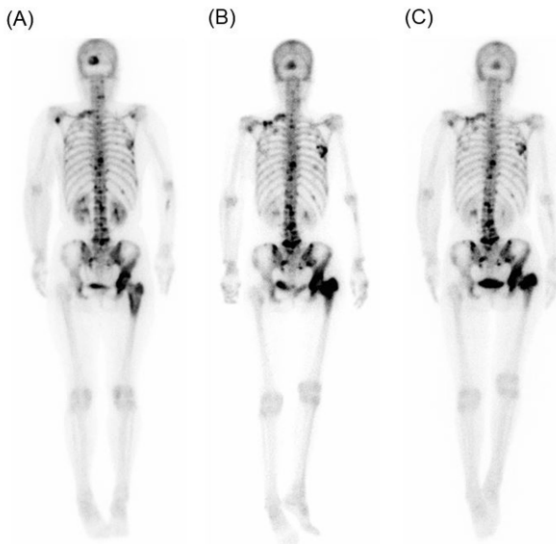


Figure 2. Tc-99m HMDP bone scintigraphy of a 75 years old woman with bone and brain metastases from breast cancer. She underwent concurrent therapy of $^{89}\text{SrCl}_2$ (88MBq) and Zoledronic acid (ZA) of 4mg/body three times. The bone scintigraphy shows unchanged bone metastases (A; before treatment, B; 1 year after treatment, C; 1.5 years after treatment). The therapy, however, enabled her to walk without pain until her terminal stage. The tumoricidal effect was assessed to be stable disease (SD).

records and interviews of their family by telephone. The average survival period was 11.6 months [prostate cancer 12.4 months (range 2–25), breast cancer 13.8 months (range 1–37), lung cancer 11.4 months (range 2–27), others 5.0 months (range 3–18). Forty nine of 51 patients have died; one patient with breast cancer and one with prostatic cancer are still alive.

Discussion

Pain relief assessed with NRS

In this study, the response rate of pain relief for bone metas-

tases was 94% (48/51). In the present study, a decrease in NRS was regardless of cancer type, i.e., prostate, breast, lung and other cancers. A systemic review showed the rate of responders of $^{89}\text{SrCl}_2$ for metastatic bone tumors to be 57%–92% [1]. Numerous reports have investigated the efficiency of $^{89}\text{SrCl}_2$ for pain relief in patients with metastatic bone tumors

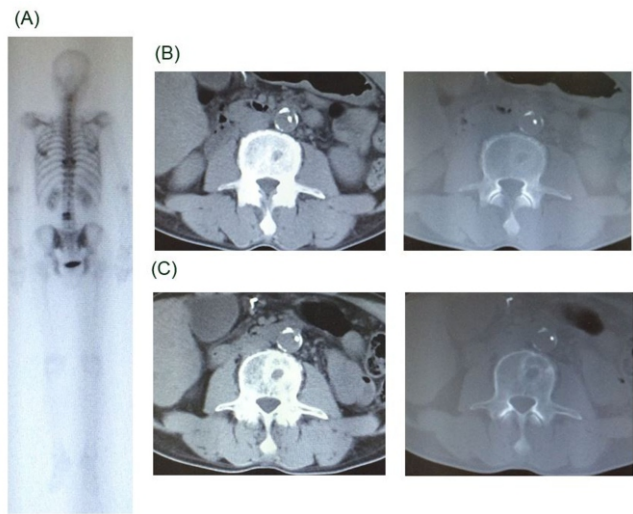


Figure 3. The CT and $^{99\text{m}}\text{Tc}$ HMDP bone scintigraphy of a 63 years old man with bone metastases from HCC. Technetium-99m HMDP accumulated in ninth thoracic vertebrae and fourth lumbar vertebrae, which were metastatic bone tumors (A). He underwent concurrent therapy of $^{89}\text{SrCl}_2$ (116MBq) and Zoledronic acid (ZA) of 4mg/body. The CT before the therapy shows osteolytic lesions due to metastases (B). The CT after the concurrent therapy shows an increase of bone metastatic lesions (C). The Numeric Rating Scale (NRS) score increased from 7 to 8. External radiotherapy (30Gy) was added, and the NRS score decreased to 7. The tumoricidal effect was assessed to be progressive disease (PD).

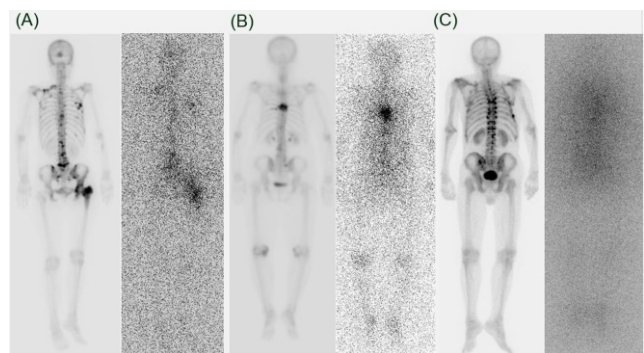


Figure 4. Sr-89 imaging with bremsstrahlung shows $^{89}\text{SrCl}_2$ accumulation in bone metastases. In two cases (A and B) with accumulation of $^{89}\text{SrCl}_2$, pain relief was obtained. However, in a case (C) without it, pain relief was not obtained.

from prostatic cancer or breast cancer; however, such investigations are fewer in patients with metastatic bone tumors from lung cancer or other tumor types. Taylor et al. (1994) reported that 10 out of 45 patients with other cancers achieved a “dramatic” response, and 24 achieved a “partial” response [17]. Concerning $^{89}\text{SrCl}_2$ single therapy for pain relief in 54 patients, Zenda et al. (2014) reported response rates of 71%, 69% and 73% for breast, prostate and other cancers, respectively [18]. The mechanism of pain relief by $^{89}\text{SrCl}_2$ is presumed as following; (1) damage of nerves cells, (2) the anti-tumor effect decreasing the pressure on nerves, and (3)

suppression of prostaglandin E2 and interleukin-6 [19-21]. Our response rate of pain relief for painful bone metastases was high, showing that $^{89}\text{SrCl}_2$ may be useful for pain relief in patients with lung and other cancers, as well as in breast and prostatic cancer patients.

Concurrent therapy of $^{89}\text{SrCl}_2$ with ZA is not commonly used for palliative care against bone metastases. However, concurrent therapy of $^{89}\text{SrCl}_2$ with ZA has recently been reported as more effective for pain relief than $^{89}\text{SrCl}_2$ or ZA alone; Storto et al. (2006) reported that the clinical response rates of $^{89}\text{SrCl}_2$ + ZA, $^{89}\text{SrCl}_2$ alone, and ZA alone were 96%, 72% and 72% respectively, in 49 patients with breast cancer or prostate cancer [12]. Yamada et al. (2012) also reported a clinically good response rate (88%) for painful bone metastases using the combination $^{89}\text{SrCl}_2$ + ZA therapy in 16 patients with a breast cancer; however, in their study, $^{89}\text{SrCl}_2$ and ZA were not simultaneously administered but rather, $^{89}\text{SrCl}_2$ was administered six months after the ZA therapy [13]. Maeda et al. (2014) suggested that $^{89}\text{SrCl}_2$ could be enhanced with administration of ZA on the patient with esophageal cancer with bone metastases [20]. The present study is the first to show the efficiency of concurrent therapy of $^{89}\text{SrCl}_2$ with ZA for painful bone metastases.

Tumoricidal effect assessed with ^{89}Sr imaging with bremsstrahlung

In the present study, a tumoricidal effect (PR) was obtained in 8 of the 22 patients (36%) assessed with imaging modalities. In another 11 of the 22 (50%) patients, the tumoricidal effect was SD; hence, the rate of non-PD was 86% (19/22). The $^{89}\text{SrCl}_2$ accumulated in $^{99\text{m}}\text{Tc}$ -HMDP uptake-positive bone metastases in eleven of 12 patients in whom the initial imaging was performed. All these eleven patients were PR or SD (91.6%). One patient with PD response showed no $^{89}\text{SrCl}_2$ accumulation. These rates are considered reasonably well in patients with painful bone metastases. Strontium-89 chloride has been reported to have a tumoricidal effect on bone metastases. According to a published autoradiography report, the radiation dose at which $^{89}\text{SrCl}_2$ is absorbed into metastatic tumors is 68cGy [22]. Kuroda et al. (2014) reported that $^{89}\text{SrCl}_2$ administration caused a decrease of the prostate-specific antigen (PSA) level, improvement of painful bone metastases, and prolonged survival in patients with prostatic cancer [19]. Yoshimura et al. (2011) suggested that clear ^{89}Sr accumulation on ^{89}Sr imaging with bremsstrahlung was associated with a tumoricidal effect for bone metastases [23]. Suzawa et al. (2010) reported a case in which pain caused by multiple bone metastases from HCC was relieved and regressed with treatment by $^{89}\text{SrCl}_2$ alone [24]. In addition, Heianna et al. (2014) reported that multiple bone metastases from breast cancer were regressed by $^{89}\text{SrCl}_2$ and that $^{89}\text{SrCl}_2$ has a possible tumoricidal effect on bone metastases as case report [25].

However, the effect of concurrent therapy of $^{89}\text{SrCl}_2$ with ZA has not been investigated in detail among a cohort of patients using imaging modalities. ZA was reported to relieve the pain of bone metastases, decrease the risk of SREs, and have a tumoricidal effect for bone metastases in patients with lung cancer and those with breast cancer [26]. Wang et al.

(2013) suggested that treatment with ZA and/or $^{89}\text{SrCl}_2$ significantly reduced the incidence of SREs, and also prolonged survival [27]. Bisphosphonates exhibit a tumoricidal effect, showing anti-angiogenic and immunomodulatory effects and inhibition of tumor bone invasiveness [12]. Furthermore, ZA inhibits bone resorption by reducing osteoclast activity, and prevents acidification at metastatic sites, and relieves pain [28]. Zoledronic acid has been shown to be effective mainly when administered long-term; however, the combination therapy of ZA and $^{89}\text{SrCl}_2$ improves painful bone metastases within 8 weeks after administration [12, 29]. Yoshimura et al. (2012) have suggested that $^{89}\text{SrCl}_2$ accumulation is significantly higher in the group with less than 1 year of ZA treatment than that in the group with 1 or more years of ZA treatment [26]. They recommended concurrent therapy of $^{89}\text{SrCl}_2$ with ZA not only because of pain relief for bone metastases, but also to enhance the tumoricidal effect, because administering $^{89}\text{SrCl}_2$ simultaneously with a limited ZA dose is considered to increase $^{89}\text{SrCl}_2$ accumulation and prolong its biological half-life by avoiding the high bone turnover caused by continuous ZA treatment [26]. The relatively high rate of pain relief and tumoricidal effects in the present study may be due to the synergy of $^{89}\text{SrCl}_2$ and ZA. However, Lam et al. (2008) have reported that ZA does not influence skeletal uptake of radiopharmaceuticals such as ^{153}Sm EDTMP [30]. Investigations of combination therapy of ZA and radiopharmaceutical for painful bone metastases are few. The mechanism behind the pain relief and tumoricidal effect of $^{89}\text{SrCl}_2$ and ZA combination therapy is still up for debate. These issues should be investigated in the future.

Clinical effect assessed with PS

In the present study, no significant improvement of PS was observed after concurrent therapy of $^{89}\text{SrCl}_2$ with ZA, although pain relief was obtained in almost patients. Among 51 patients, PS was improved only in seven patients. Performance status remained unchanged in 43 patients and became worse in one patient. These results may be due to the good PS (PS \leq 2) in almost all patients when the treatment was initiated. Turner et al. (2011), however, reported that $^{89}\text{SrCl}_2$ alone significantly improved the PS in 93 patients with bone metastases from prostate cancer [31]. To our knowledge, a correlation between improved PS and a therapeutic effect for bone metastases is seldom reported. Further investigations are needed.

Adverse effects

Bone marrow suppression of grade III or more was not observed in the present study, although grade II anemia was. No severe bone suppression caused by concurrent therapy of $^{89}\text{SrCl}_2$ + ZA was observed in previous papers [26, 28]. A temporary increase in pain within a week after administration of $^{89}\text{SrCl}_2$ + ZA, so-called pain flare, was observed in five of 51 patients (9.8%). The incidence of this phenomenon is reported to be 5%-15% [32]. Hence, concurrent therapy of $^{89}\text{SrCl}_2$ with ZA is eligible as palliation against painful bone metastases.

There are some limitations in the present study. First, this is a single-center study, and the patient population is small.

Second, the correlation between the therapeutic effect assessed with imaging modalities and findings of the ^{89}Sr imaging with bremsstrahlung could not be investigated in all patients. Third, the influence of the concurrent therapy of $^{89}\text{SrCl}_2$ with ZA to the SREs and QOL, and the statistics of biologically heterogeneous tumors such as lung cancer and breast cancer and their survivals were not investigated in the present study. In this study, this was not a randomized control study, and this treatment was uniform; we did not classify our patients into three groups such as $^{89}\text{SrCl}_2$ + ZA group, $^{89}\text{SrCl}_2$ alone group and ZA alone group, and investigate the pain relief and tumoricidal effect for bone metastases. However, concurrent therapy of $^{89}\text{SrCl}_2$ with ZA has been already reported to be more useful to pain relief than $^{89}\text{SrCl}_2$ or ZA alone in several studies, and it would be unethical to compare the pain relief and tumoricidal effect among three groups in terminal cancer patients suffering from painful bone pain. Strontium-89 chloride is useful for palliation of pain from diffuse skeletal metastases, but no significant benefit in terms of disease progression and over-all survival (OS) has been shown in past reported literatures [33, 34]. However, radium-223 dichloride (^{223}Ra) is an alpha emitter radionuclide, which is first line treatment of bone metastases from castration-resistant prostate cancer (CRPC) because of antitumor effect on bone metastases with no relevant effects on the bone marrow [34]. Recently, ^{223}Ra has been reported to improve the OS and reduce the risk for SREs in patients with CRPC bone metastases [34, 35].

Especially, the positive interaction between ^{223}Ra and osteoclast-target agents (bisphosphonates or denosumab) may not only be associated with simple pain palliation but also provide benefits in terms of SREs reduction and increased survival [34, 36]. The clinical effectiveness of combined radiopharmaceuticals and osteoclast-target agents' therapy for bone metastases should be investigated in more cases in the future.

In conclusion, concurrent therapy of $^{89}\text{SrCl}_2$ with ZA is not only effective for pain relief of bone metastases but also may have tumoricidal effect.

The authors declare that they have no conflicts of interest.

Bibliography

- Paes FM, Serfini AN. Systemic metabolic radiopharmaceutical therapy in the treatment of metastatic bone pain. *Semin Nucl Med* 2010; 40: 89-104.
- Hirsh V. Skeletal disease contributes substantially to morbidity and mortality in patients with lung cancer. *Clin Lung Cancer* 2009; 10: 223-9.
- Hillegonds DJ, Franklin S, Shelton DK et al. The management of painful bone metastases with an emphasis on radionuclide therapy. *J Natl Med Assoc* 2007; 99: 785-94.
- Serafani AN. Therapy of metastatic bone pain. *J Nucl Med* 2001; 42: 895-906.
- Sbonias E. Radioprotection and environmental pollution by the use of the radionuclides ^{89}Sr , ^{186}Re and ^{153}Sm for pain palliation in metastatic bone diseases. Related calculations. *Hell J Nucl Med* 2005; 8: 68-73.
- Kan MK. Palliation of bone pain in patients with metastatic cancer using strontium-89 (Metastron). *Cancer Nur* 1995; 18: 286-91.
- Blake GM, Zivanovic MA, Blaquiery RM et al. Strontium-89 therapy; measurement of absorbed dose to skeletal metastases. *J Nucl Med* 1988; 29: 549-57.
- Finlay IG, Mason MD, Shelley M. Radioisotope for the palliation of metastatic bone cancer; a systemic review. *Lancet Oncol* 2005; 6: 392-400.
- Tchekmedyan NS, Chen YM, Saad F. Disease progression increases the risk of skeletal-related events in patients with bone metastases from castration resistant prostatic cancer, lung cancer, or other solid tumors. *Cancer Invest* 2010; 28: 844-55.
- Trojan J, Kim SZ, Engels K et al. In vitro chemosensitivity to gemcitabine, oxaliplatin and zoledronic acid predicts treatment response in metastatic gastric cancer. *Anticancer Drugs* 2005; 16: 87-91.
- Miwa S, Mizokami A, Konaka H et al. A case of bone, lung, pleural and liver metastases from renal cell carcinoma which responded remarkably well to zoledronic acid monotherapy. *Jpn J Clin Oncol* 2009; 39: 745-50.
- Stroto G, Klain M, Paone G et al. Combined therapy of Sr-89 and zoledronic acid in patients with painful bone metastases. *Bone* 2006; 39: 35-41.
- Yamada K, Yoshimura M, Kaise H et al. Concurrent use of Sr-89 chloride with zoledronic acid is safe and effective for breast cancer patients with painful bone metastases. *Exp Ther Med* 2012; 3: 226-30.
- Downie WW, Leatham PA, Rhind VM et al. Studies with pain rating scales. *Ann Rheum Dis* 1978; 37: 378-81.
- Sørensen JB, Klee M, Palshof T, Hansen HH. Performance status assessment in cancer patient. A review. *Lancet Oncol* 2005; 6: 392-400.
- Van den Wyngaert T, Huizing MT, Fossion E, Vermorken JB. Bisphosphonate in Oncology; Rising Stars or Fallen Heroes. *Oncologist* 2009; 14: 181-91.
- Taylor AJ. Sr-89 for the palliation of bone pain due to metastatic disease. *J Nucl Med* 1994; 35: 2054
- Zenda S, Nakagami Y, Toshima M et al. Strontium-89 (Sr-89) chloride in the treatment of various cancer patients with multiple bone metastases. *Int J Clin Oncol* 2014; 19: 739-43.
- Kuroda I. Strontium-89 for prostatic cancer with bone metastases: the potential of cancer control and improvement of overall survival. *Ann Nucl Med* 2014; 28: 11-6.
- Maeda O, Ando T, Ishiguro K et al. A patient with esophageal cancer with bone metastasis who achieved pain relief with repetitive administration of strontium-89 chloride. *Clin J Gastroenterol* 2014; 7: 387-91.
- Krishnamurthy GT, Krishnamurthy S. Radionuclides for metastatic bone pain palliation: a need for rational re-evaluation in the new millennium. *J Nucl Med* 2000; 41: 688-91.
- Breen SL, Pow JE, Porter T. Dose estimation in strontium-89 radiotherapy of metastatic prostatic carcinoma. *J Nucl Med* 1992; 33: 1316-23.
- Yoshimura M, Saito K, Park J et al. Tumoricidal effect of strontium-89. *Clin Nucl Med* 2011; 36: 296-9.
- Suzawa N, Yamakado K, Takaki H et al. Complete regression of multiple painful bone metastases from hepatocellular carcinoma after administration of strontium-89 chloride. *Ann Nucl Med* 2010; 24: 617-20.
- Heianna J, Miyauchi T, Endo W et al. Tumor regression of multiple bone metastases from breast cancer after administration of strontium-89 chloride (Metastron). *Acta Radiol Short Rep* 2014; 10: 2047981613493412.
- Yoshimura M, Kohno N, Yamada K et al. ^{89}Sr imaging with Bremsstrahlung in patients with metastatic breast cancer. *Clin Nucl Med* 2012; 37: 1035-40.
- Wang Y, Tao H, Yu X et al. Clinical significance of zoledronic acid and Strontium-89 in patients with asymptomatic bone metastases from non-small cell lung cancer. *Clin Lung Cancer* 2013; 14: 254-60.
- Kuroda I. Effective use of strontium-89 in osseous metastases. *Ann Nucl Med* 2012; 26: 197-206.
- Perry CM, Figgitt DP. Zoledronic acid: review of its use in patients with advanced cancer. *Drugs* 2004; 64: 1197-211.
- Lam MG, Dahmane A, Stevens WH et al. Combined use of zoledronic acid and ^{153}Sm -EDTMP in hormone-refractory prostate cancer patients with bone metastases. *Eur J Nucl Med Mol Imaging* 2008; 35: 756-65.
- Turner SL, Gruenewald S, Spry N et al. Loss pain does equal better quality of life following strontium-89 therapy for metastatic prostatic cancer. *Br J Cancer* 2001; 84: 297-302.
- Robinson RG. Strontium-89 precursor targeted therapy for pain relief of blastic metastatic disease. *Cancer* 1993; 172: 3433-5.
- James ND, Pirrie SJ, Pope AM et al. Clinical Outcomes and Survival Following Treatment of Metastatic Castrate-Refractory Prostate Cancer With Docetaxel Alone or With Strontium-89, Zoledronic Acid, or Both: The TRAPEZE Randomized Clinical Trial. *JAMA Oncol* 2016; 2: 493-9.
- Florimonte L, Dellavedova L, Maffioli LS. Radium-223 dichloride in clinical practice: a review. *Eur J Nucl Med Mol Imaging* 2016; 43: 1896-909.

35. Parker C, Zhan L, Cislo P et al. Effect of radium-223 dichloride (Ra-223) on hospitalization: An analysis from the phase 3 randomized Alpha-radin in Symptomatic Prostate Cancer Patients (ALSYMPCA) trial. *Eur J Cancer* 2017;71: 1-6.

36. Basch E, Loblaw EA, Oliver TK et al. Systemic therapy in men with metastatic castration-resistant prostate cancer: American Society of Clinical Oncology and Cancer Care Ontario clinical practice guideline. *J Clin Oncol* 2014;32:3436-48.



Vasiliki Grammatikou: Grave Depression. Oil in canvas 30x21 cm.