

Imaging with ^{18}F -FDG PET/CT of a primitive primary neuroectodermal tumor of the chest wall, in an adult

To the Editor: Primary primitive neuroectodermal tumor (PNET) of the chest wall is a rare disease of the pediatric age group and even rarer in adults. Radiological investigation of the PNET of the chest wall includes plain chest radiographs, computed tomography (CT), and magnetic resonance imaging (MRI), the latter having the greatest sensitivity. Imaging with ^{18}F -fluorodeoxyglucose (^{18}F -FDG) positron-emission computed tomography (PET/CT) can also be helpful and effective for the pre-treatment evaluation of patients with PNET of the chest wall. We report a ^{18}F -FDG PET/CT imaging of PNET of the chest wall in an adolescent visualizing the active focus of glucose metabolism.

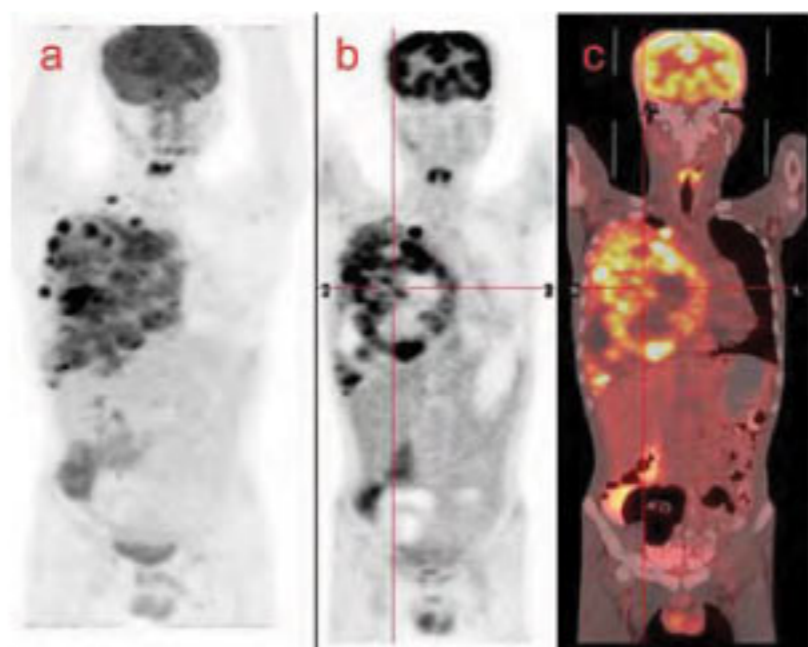


Figure 1. The ^{18}F -FDG images: (a) maximum intensity projection (b) coronal PET and (c) coronal PET/CT showing a large hypermetabolic lesion in the right chest involving entire mediastinum without any other lesion elsewhere in the body.

An 18 years old male presented with sudden onset breathlessness, chest pain and cough. Physical examination revealed a small nodular swelling in the right upper chest wall associated with tenderness. Computed tomography (CT) of the chest showed a large soft tissue mass within the right upper hemithorax, arising from the chest wall. A diagnosis of PNET of the chest wall was made on histopathology. Imaging with ^{18}F -FDG PET/CT performed for staging showed a large hypermetabolic focus in the right hemithorax involving the entire mediastinum without any other lesion elsewhere in the body. Involvement of the 4th rib and multiple mediastinal lymph nodes were also noticed. The patient is on treatment with chemotherapy comprising adriamycine, cyclophosphamide and vincristine.

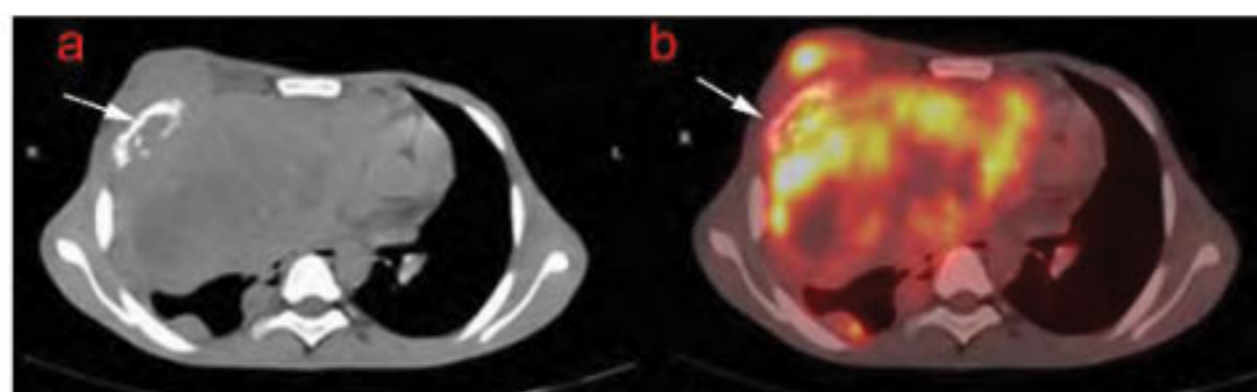


Figure 2. Transaxial ^{18}F -FDG images: (a) CT (b) PET/CT showing involvement of the right 4th rib with a lytic lesion (arrow). Areas of necrosis are also noticed in the mass on CT images with photopenic areas on PET/CT, suggestive of necrosis.

Primitive neuroectodermal tumor (PNET) of the thoraco-abdominal region is one of the groups of small

round cell tumors originally described by Askin et al (1979) [1]. Most common symptom is chest pain, which may be accompanied with pleural effusion and dyspnea. Radiological description of the PNET of the chest wall is well described using CT and MRI [2]. However, the role of ^{18}F -FDG PET/CT in the diagnostic work-up of PNET of the chest wall is yet to be established. Few reports describe the uptake ^{18}F -FDG in PNET, but there is only one case report of PNET of the chest wall [3].

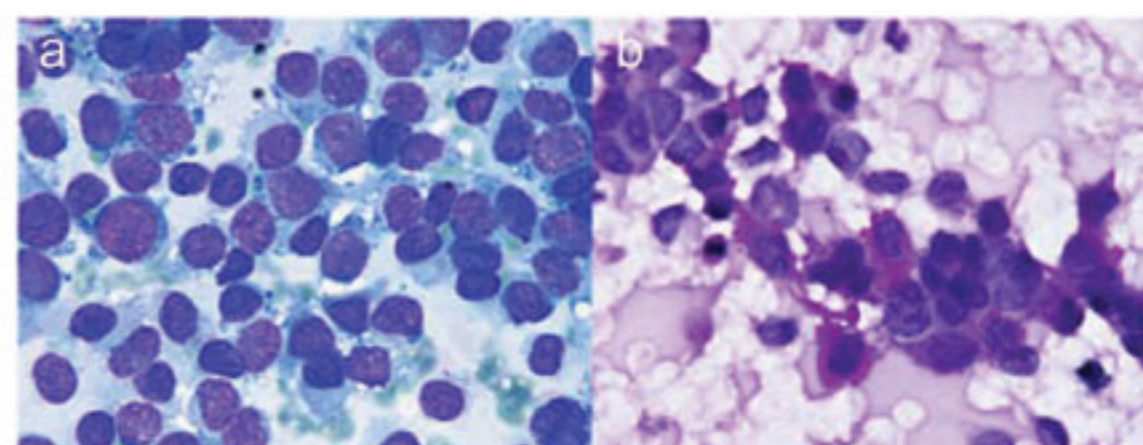


Figure 3. Microphotographs (a) (MGG x 1120) showing dispersed population of malignant small round cells with scanty cytoplasm and high nuclear cytoplasmic ratio and (b) (PAS x 1120) showing cytoplasmic PAS positivity in the tumor cells along with a neutrophil cell acting as an internal control.

Unfortunately, these reports contain contradictory imaging findings, the majority of them demonstrating intense hypermetabolism of the tumor [4-7]. A case of PNET of the right upper extremity did not show ^{18}F -FDG uptake despite its large size and aggressive nature [8]. This contradiction may be attributed to the differences in biological behavior in the form of underexpression of glut-1 transporter and/or hexokinase II enzymes and metabolic profiles of PNET in different sites [8]. Direct tumor invasion into chest wall structures is interpreted better by increased ^{18}F -FDG uptake on PET/CT images than by other imaging modalities. *In conclusion*, active glucose metabolism of PNET of the chest wall on ^{18}F -FDG PET/CT was valuable in the preoperative evaluation and treatment monitoring of a patient with this very seldom tumor [3].

Bibliography

1. Askin FB, Rosai J, Sibley RK et al. Malignant small cell tumor of the thoracopulmonary region in childhood: a distinctive clinicopathologic entity of uncertain histogenesis. *Cancer* 1979; 43: 2438-51.
2. Sallustio G, Pirroni T, Lasorella A et al. Diagnostic imaging of primitive neuroectodermal tumour of the chest wall (Askin tumour). *Pediatr Radiol* 1998; 28: 697-702.
3. Demir MK, Koşar F, Sanlı Y et al. ^{18}F -FDG PET-CT features of primary primitive neuroectodermal tumor of the chest wall. *Diagn Interv Radiol* 2009; 15: 172-5.
4. Gyorke T, Zajic T, Lange A et al. Impact of FDG-PET for staging of Ewing sarcomas and primitive neuroectodermal tumours. *Nucl Med Commun* 2006; 27: 17-24.
5. Watanabe N, Kawano M, Takada M et al. ^{18}F -FDG PET imaging in a primitive neuroectodermal tumor. *Clin Nucl Med* 2006; 31: 484-5.
6. Lucas JD, O'Doherty MJ, Cronin BF et al. Prospective evaluation of soft tissue masses and sarcomas using fluorodeoxyglucose positron emission tomography. *Br J Surg* 1999; 86: 550-6.

7. Meltzer CC, Townsend DW, Kottapally S et al. FDG imaging of spinal cord primitive neuroectodermal tumor. *J Nucl Med*. 1998; 39: 1207-9.
8. Musana KA, Raja S, Cangelosi CJ et al. FDG PET scan in a primitive neuroectodermal tumor. *Ann Nucl Med* 2006; 20: 221-5.
9. Dick EA, McHugh K, Kimber C et al. Imaging of non-central nervous system primitive neuroectodermal tumours: Diagnostic features and correlation with outcome. *Clin Radiol* 2001; 56: 206-15.

**Koramadai Karuppuswamy Kamaleshwaran²,
Bhagwant Rai Mittal MD, Dhritiman Chakraborty MD,
Anish Bhattacharya MD, Nalini Gupta¹ MD, Surinder
Kumar Jindal² MD**

1. Departments of Nuclear Medicine and PET, 2. Cytology and Gynecological Pathology and 3. Pulmonary

*Medicine, Postgraduate Institute of Medical Education
and Research,
Chandigarh, India*

Dr. B.R.Mittal, MD

Professor and Head, Department of Nuclear Medicine
and PET, PGIMER, Chandigarh –160 012, India

Tel: +91 172 2756722

Fax: +91 172 2742858

E-mail: brmittal@yahoo.com

Hell J Nucl Med 2010; 13(3): 287-288

Published on line:25-11-10

Department of error

In HJNM 2010; 13(2): 127-131, in the original article "The value of different washout parameters in the evaluation of renal transplants by technetium-99m-ethylene-l-l-dicysteine" by Bedii Kanmaz et al, the first part of the first paragraph of Discussion should read:

Determining the function of renal transplants is an important early postoperative parameter to decide for continuing or discontinuing immunosuppression. For this purpose radionuclide methods have been used after surgeries for monitoring renal transplant recovery by various agents such as ¹³¹I-OIH, ^{99m}Tc-diethylene triamine penta acetic acid (^{99m}Tc-DTPA) and ^{99m}Tc-MAG3 [7, 8]. Ortho-hippurate acts like para amino-hippuric acid and has been used as a standard agent to show renal function, especially the extraction and excretion phases of the kidney. This agent is commonly labeled with ¹³¹I resulting in relatively poor quality images and significant radiation dose to the patient. Then follows: On the other hand ...