

The therapeutic effect of transcatheter arterial thromboembolization of hepatocellular carcinoma as for residual viable tumors related to lipiodol density areas and detected by ^{18}F -FDG PET/CT and CT

Jinpeng Li¹ MD, Wenbo Shao¹ MD, PhD, Jinlong Song¹ MD, Congcong Shi², Hua Chen¹ MD, Ning Cong¹ MD.

(Jinpeng Li and Wenbo Shao contributed equally to this study)

1. Department of Surgical Oncology (Interventional Therapy), Shandong Cancer Hospital and Institute, Shandong Academy of Medical Sciences, 440 Jiyuan Road, Jinan, Shandong, 250117, China. 2. Six Ward of Shandong Mental Health Center, Jinan 250014, China.

Jinlong Song MD. Email: jlsong1026@126.com

Hell J Nucl Med 2013; 16(1): 64-65

Published on line: 10 April 2013

Hepatocellular carcinoma (HCC) is one of the most common cancers worldwide and causes about one million deaths annually [1, 2], however, most patients are diagnosed at an advanced stage, Transcatheter arterial chemoembolization (TACE) is one of the most common and effective palliative treatments and meta-analysis of a randomized controlled trial has shown that survival is improved after treatment [3]. Despite documented survival benefits, TACE can also induce the up-regulation of proangiogenic and growth factors, which might contribute to accelerate the progression of HCC in patients with incomplete response. Therefore, it is clinically important to analyse the therapeutic effect of TACE as soon as possible [4]. Conventional imaging modalities, such as computed tomography (CT) or magnetic resonance imaging (MRI), cannot satisfy clinicians in that context, because treatment evaluation by these anatomical imaging modalities requires a sufficient period of time in order to confirm tumor shrinkage. Additionally, the ability of contrast CT to determine tumor viability after TACE is limited, because the

retained hyperattenuating lipiodol makes it difficult to detect contrast enhancement within a viable tumor.

The ^{18}F -fluoro-2-deoxy-D-glucose positron-emission-tomography (^{18}F -FDG PET) is a functional imaging tool that provides metabolic information of the lesion. It is effective for diagnosis, monitoring treatment and detection of recurrent tumors of various cancers because of its high sensitivity and specificity [5]. In contrast to morphological imaging techniques such as CT, the ^{18}F -FDG PET evaluates tumor viability based on glucose metabolism; it is not influenced by tumor morphology or lipiodol deposition. Therefore, as several investigators have previously reported ^{18}F -FDG PET might be useful for monitoring response and for being a guide in following treatment [6].

Our present report and a previous study of ours have shown that increased ^{18}F -FDG uptake was not correlated with lipiodol dense distribution [7]. Researchers have also found that ^{18}F -FDG PET was valuable to reveal recurrent tumor or residual tumor in HCC patients after TACE [8].

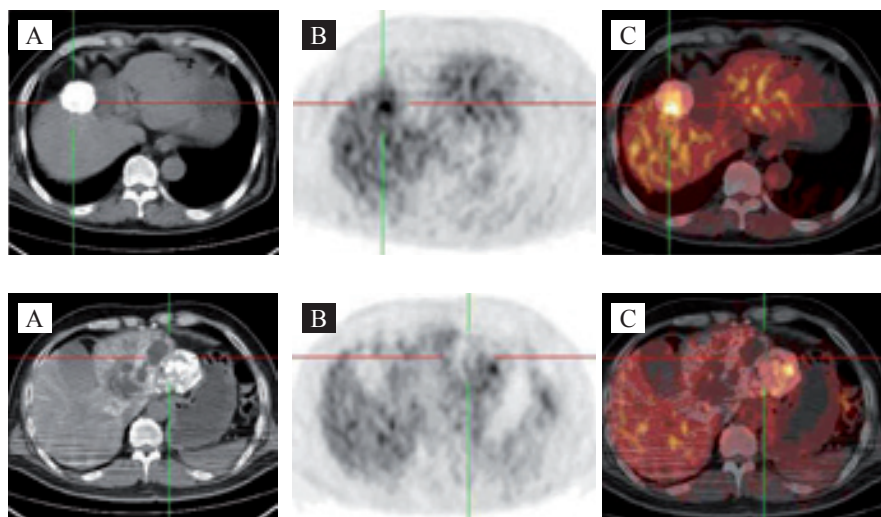


Figure 1. A 58 years old woman with HCC treated with TACE. Interval from TACE to PET was 78 days. Serum AFP concentration was 210.8ng/mL. The patient underwent PET-CT for clinically suspected recurrence. Multiphasic CT (A) shows wide lipiodol dense distribution in the right lobe of the liver, ^{18}F -FDG PET-CT images (B and C) show increased activity in the marginal portion of the tumor.

Figure 2. Images of a 55 years old woman with viable lipiodolized HCC. Multiphasic CT images (A) show absent lipiodol dense distribution in the marginal portion of the tumor. PET images (B) show defects of ^{18}F -FDG uptake (arrows) observed in the marginal portion of tumor. PET-CT images (C) show the viable residual tumor in the lipiodol uptake or in the non-lipiodol uptake areas.

We have studied 29 HCC patients without metastatic lesions who underwent ^{18}F -FDG PET/CT examination within 1.5~2 months after TACE. In our analysis, we regarded as viable lipiodolized HCC, with ^{18}F -FDG uptake higher or similar to that of the surrounding normal liver tissue. Increased ^{18}F -FDG uptake was found in 21/29 cases. Nine of these cases showed increased tracer uptake indicating tumor residuals in the lipiodol-accumulated areas and the other 12/21 cases showed increased tracer uptake in tumor residuals only in the lipiodol-unaccumulated areas. The imaging of ^{18}F -FDG PET/CT scanning for 8/29 cases was negative and 3 of these 8 cases had an unexplained high serum α -fetoprotein concentration. One of these 8 cases after 1-2.5 years of follow-up showed false-negative and 7 showed true-negative results. The sensitivity of PET/CT for the detection of viable residuals of HCC after TACE was 95.4% (21/22) and this sensitivity was higher than when tested by CT 63.8% (14/22). Residual viable tumors were not collerated with lipiodol dense areas, because so many were found in the unaccumucated areas (Fig. 1 and 2).

In conclusion, we confirm the results of others that ^{18}F -FDG PET/CT has higher sensitivity as compared to CT for the detection of viable residuals of HCC after TACE. ^{18}F -FDG uptake is not correlated with lipiodol dense distribution after TACE, and residual viable tumors could be found in the lipiodol-accumulated and non accumulated fields. ^{18}F -FDG PET/CT may provide the assessment for the therapeutic

effect on HCC after TACE and the guidance for additional treatment.

Bibliography

1. Schafer DF, Sorrell MF. Hepatocellular carcinoma. *Lancet* 1999; 353: 1253-7.
2. Bosch FX, Ribes J, Borrás J et al. Epidemiology of hepatocellular carcinoma. *Clin Liver Dis* 2005; 9: 191-211.
3. Rougier P, Mitry E, Barbare JC et al. Hepatocellular carcinoma (HCC): an update. *Semin Oncol* 2007; 34(2 Suppl 1): S12-S20.
4. Cheng HY, Wang X, Chen D et al. The value and limitation of transcatheter arterial chemoembolization in preventing recurrence of resected hepatocellular carcinoma. *World J Gastroenterol* 2005; 11: 3644-6.
5. Vitola JV, Delbeke D, Meranze SG et al. Positron emission tomography with F-18-fluorodeoxyglucose to evaluate the results of hepatic chemoembolization. *Cancer* 1996; 78: 2216-22.
6. Torizuka T, Tamaki N, Inokuma T et al. Value of fluorine-18-FDG-PET to monitor hepatocellular carcinoma after interventional therapy. *J Nucl Med* 1994; 35: 1965-9.
7. Ma L, Zheng JS, Fu Z et al. Clinical value of ^{18}F -FDG PET/CT to monitor liver cancer after transcatheter arterial chemoembolization. *J Med Imaging Vol* 2009; 19(4): 428-31.
8. Park JW, Kim JH, Kim SK et al. A prospective evaluation of ^{18}F -FDG and ^{11}C -acetate PET/CT for detection of primary and metastatic hepatocellular carcinoma. *J Nucl Med* 2008; 49: 1912-21.