

Negative predictive value of gallium-67 SPET/CT in a case of Hodgkin's lymphoma with bulky mediastinal disease

To the Editor: Many of Hodgkin's lymphoma (HL) patients may present with a bulky mediastinal mass. Treatment of Hodgkin's lymphoma often results in reduction of this tumor but its complete disappearance is unusual.

Detecting viable tumor in these residual masses is difficult with conventional imaging modalities [1-2]. Positron emission tomography combined with computerized tomography (PET/CT) using ^{18}F -fluorodeoxyglucose (FDG) is considered as the best available imaging modality for the diagnosis of lymphomas [3, 4]. Recently, hybrid imaging systems for single photon emission tomography, combined with computerized tomography (SPET/CT) have been introduced and may be an alternative to positron emission tomography (PET/CT) when the latter is not available. The negative predictive value of gallium-67 citrate (^{67}Ga -C) SPET is 83% which is just less than that of PET (89%) [3]. We have studied a 32 years old male with lymphocyte predominant stage IIa HL treated with cyclophosphamide, hydroxydaunorubicin vincristine and prednisolone (CHOP), having a mediastinum mass which caused clinical symptoms and was diagnosed by CT scan (Fig. 1). He then had 4 cycles of bleomycin, etoposide, adriamycine, cyclophosphamide, vincristine, procarbazine, and prednisone (BEACOPP) and remained symptom-free during this period. He was referred to our Institute for further management as there was no decrease in the size of the paracardiac mass post treatment.

The patient was subjected to ^{67}Ga -C scintigraphy. Images were acquired 48h after the i.v. injection of 185MBq of ^{67}Ga -C (Fig 2). Six weeks post-chemotherapy, whole body SPET/CT images showed increased ^{67}Ga uptake in the bone marrow consistent with post chemotherapy status. However, no abnormal ^{67}Ga avid focus was noted anywhere in the body. Hybrid SPET/CT imaging revealed a right paracardiac mass suggestive of fibrosed lymph node masses (Fig. 3). Subsequent CT guided biopsy from the mass did not demonstrate malignant tissue. No further chemotherapy was advised. ^{18}F -FDG PET/CT is the gold standard for imaging lymphomas with a sensitivity of about 100%. The sensitivity of ^{67}Ga is inferior to ^{18}F -FDG-PET (80% Vs 100%) and can never be recommended as an alternative in initial evaluation of lymphoma. However, the negative predictive value is comparable to ^{18}F -FDG-PET (83% Vs 89%). This high negative predictive value of ^{67}Ga -C SPET can be used in identifying patients with bulky residual disease that contain residual viable tumor, when no access is available to ^{18}F -FDG-PET. The high negative predictive value of ^{67}Ga -C SPET would hold good for tumors of size at least 1.5cm. In this case, the tumor was sufficiently large (7cmx4cm) to be identified on SPET. However, ^{67}Ga uptake in smaller tumors should be interpreted with caution considering the difficulties in imaging smaller tumors with lower resolution of SPET tech-

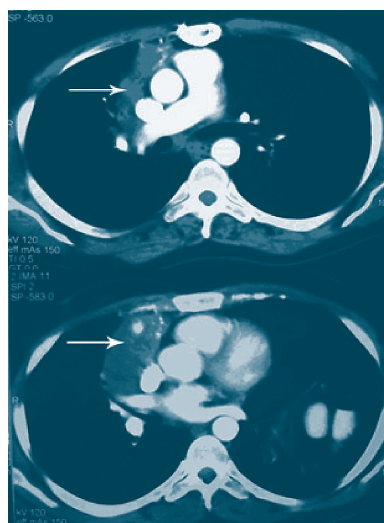


Figure 1. Contrast enhanced CT scan obtained after 2nd line chemotherapy for Hodgkin's lymphoma, revealed a paracardiac mass (arrows) with evidence of calcifications. The mass remained essentially unchanged after 4 cycles of chemotherapy treatment prompting referral for a ^{67}Ga scan.

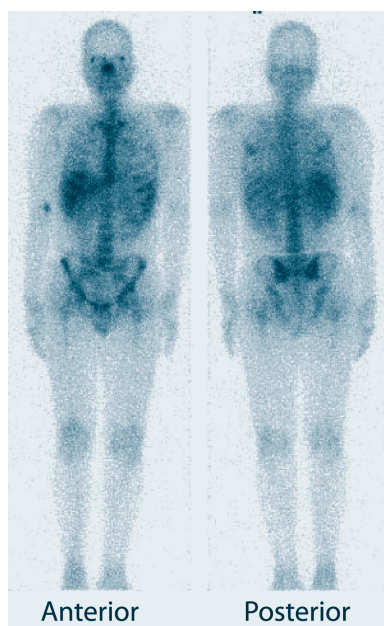


Figure 2. Whole body image acquired 48 h after the intravenous injection of 185MBq of ^{67}Ga citrate, shows bone marrow uptake of ^{67}Ga consistent with the post chemotherapy status. No abnormal ^{67}Ga avid focus is noted anywhere in the body.

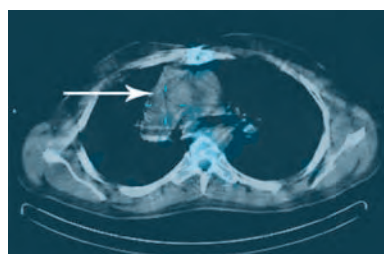


Figure 3. A SPET/CT imaging of the chest confirms no gallium-67 avidity in the paracardiac mass (arrow) suggesting that it is residual fibrosed mass further confirmed by CT guided FNAC.

niques in comparison to CT. This case thus suggests that ^{67}Ga -C SPET/CT can differentiate fibrosed from functionally active enlarged lymph nodes, avoiding invasive biopsies and providing a viable alternative, when PET/CT is not available.

Bibliography

1. Even-Sapir E, Israel O. Gallium-67 scintigraphy: a cornerstone in functional imaging of lymphoma. *Eur J Nucl Med Mol Imaging*. 2003 Jun; 30 Suppl 1: S65-81.
2. Zinzani PL, Zompatori M, Bendandi M et al. Monitoring Bulky Mediastinal Disease with Gallium-67, CT-Scan and Magnetic Resonance Imaging in Hodgkin's disease and High-Grade Non-Hodgkin's Lymphoma. *Leukemia and Lymphoma* 1996; 22: 131-135.
3. Hines-Thomas M, Kaste SC, Hudson MM et al. Comparison of gallium and PET scans at diagnosis and follow-up of pediatric patients with Hodgkin lymphoma. *Pediatr Blood Cancer* 2008; 51:198-203.
4. Kostakoglu L, Leonard JP, Kuji I et al. Comparison of fluorine-18 fluorodeoxyglucose positron emission tomography and ⁶⁷Ga scintigraphy in evaluation of lymphoma. *Cancer* 2002; 94: 879-888.

**Chidambaram Natrajan Balasubramanian Harisankar,
Koramadai Karuppuswamy Kamaleshwaran, Anish Bhattacharya,
Baljinder Singh, Bhagwant Rai Mittal**

Department of Nuclear Medicine, Postgraduate Institute of Medical Education and Research, Chandigarh - 160 012 India.

Dr. B.R. Mittal

Professor and Head, Department of Nuclear Medicine,
Postgraduate Institute of Medical Education and Research,
Chandigarh-160 012, India.

Phone: +91 172 275 6722, Fax: +91 172 274 4401

E-mail: brmittal@yahoo.com

Published on line: 3 March 2009



A traditional highland village, Kalarrytes, near Ioannina NW of Greece, where Mr C. Voulgaris the great grand father of the owners of the well-known synonymous jewelry stores was born. Notice the handsome stone-slate-domed roof. One of the crowns of mt. Tzoumerka 2.112m is seen at the background. Sent by Mrs. A Papatriantafidou MA, Thessaloniki.