

Two cases of ^{18}F -FDG PET/CT findings in HIV-negative Kaposi's sarcoma. Original presentation of one case favorably treated with interferon

To the Editor: Kaposi's sarcoma (KS) is a rarely seen angio-proliferative tumor associated with human herpes virus 8 (HHV-8) infection, also known as Kaposi sarcoma herpes virus (KSHV) [1-3]. Four epidemiological types of KS have been described: a) The classic type originally described by Kaposi, which is typically found in midaged or in the elderly, b) The endemic type, several subtypes of which have been described in sub-Saharan indigenous Africans prior to the acquired immune deficiency syndrome (AIDS) epidemic after 2000s, c) The iatrogenic type associated with immunosuppressive drug treatment, typically seen in organ transplant recipients, and d) AIDS-associated, epidemic KS, which is usually aggressive in HIV-related or in post transplant patients, but may be more indolent. Clinically, in KS we find dark blue or purplish macular or spindle-shaped nodular skin lesions. The same lesions are found in pathology in the lymphoid, respiratory, and/or in the gastrointestinal tissues [4-7]. The disease carries a variable clinical course ranging from minimal mucocutaneous disease to extensive organ involvement. Treatment for localized pathology is surgery or radiation treatment, while widespread disease may be treated by systemic chemotherapy or immunomodulators [8-14].

Currently, fluorine-18-fluorodesoxyglucose positron emission tomography/computed tomography (^{18}F -FDG-PET/CT) is used as a very effective tool in monitoring treatment response for many ^{18}F -FDG avid tumors. To our knowledge, the role of ^{18}F -FDG-PET/CT, in HIV-negative KS of the skin and soft tissues was documented in only one case report [8]. In that report, the authors documented a case of human immunodeficiency virus (HIV)-negative classic KS,

which responded to target of rapamycin (mTOR), a kinase delivering phosphate groups to amino acid residues of downstream proteins. The treatment response to rapamycin was well demonstrated by PET-CT. No published report referring to the interferon (INF) response in a HIV-negative KS using ^{18}F -FDG-PET/CT could be found in current literature till January 2010.

In case 1, a 76 years old man with violaceous plaques and nodular skin lesions diffusely involving the lower thigh, legs and upper extremities was admitted. He had no significant medical history except for asthma. His blood tests were normal. The histopathological diagnosis obtained from skin lesions of the thigh revealed low grade KS. Before starting INF treatment, he was referred to us for a ^{18}F -FDG-PET/CT test for staging and treatment response. Fluorine-18-FDG-PET scan using 444MBq activity showed multifocal increased dermal and subdermal ^{18}F -FDG uptake in the distal parts of the lower extremities more intense on the dorsal surface of the left foot (Fig. 1A and C). The lesions on the scan were fewer than lesions seen on physical examination. Upper extremities' lesions showed no ^{18}F -FDG avidity. Bilateral ^{18}F -FDG positive axillary lymphadenopathy was an unexpected finding which may be due to benign or malignant lymphoproliferative disease related or unrelated with KS (Fig. 1E). No change in axillary lymph nodes sizes as compared to previous thorax CT findings was found indicating a benign course. A control PET/CT scan after 6 months revealed diminished metabolic activity in both axillae (Fig. 1B and F) and in the lower extremities (Fig. 1B and D). New lesions on the upper extremities were ^{18}F -FDG negative.

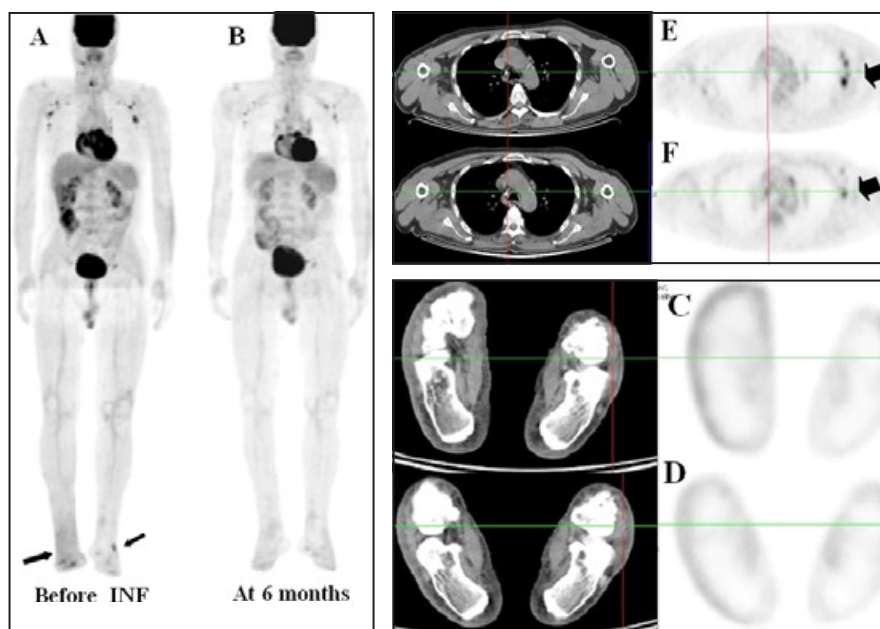


Figure 1. First case: Fluorine-18-FDG-PET image **A** and **B**: Anterior position of maximum intensity projection (MIP) image **C**: Axial section at the level of heel before the initiation of INF treatment. Multifocal increased dermal and subdermal ^{18}F -FDG uptake was demonstrated in the distal parts of bilateral lower extremities (arrows in **A** and **C**). A control PET scan after 6 months, **B**: Anterior MIP image **D**: Axial view at the level of heel revealed decreased uptake indicating metabolic response to INF treatment. Unexpected bilateral ^{18}F -FDG positive axillary lymphadenopathies were demonstrated (arrow, **E**). After 6 months, diminished uptake was shown in both axillary regions (arrow, **F**) and no pathological uptake was observed on both feet (**D**).

The second case was a 77 years old woman with ulcerated plaques disseminated on the distal portion of both legs, since years. She had no significant medical history and blood tests were normal. Excisional biopsy from a dermal lesion of the right dorsal foot showed KS. One year later, similar lesions occurred around the excised area suggesting recurrence and the patient had palliative radiotherapy. On follow up, the patient had more dermal lesions and was admitted for restaging. A PET/CT study using 400MBq of ^{18}F -FDG showed multifocal dermal and subdermal ^{18}F -FDG accumulation, mainly on the right distal lower extremity (Fig. 2A, B and C). In addition, bilateral diffuse ^{18}F -FDG uptake was seen in the distal portions of the legs suggesting lymphedema and venous stasis (Fig. 2A).

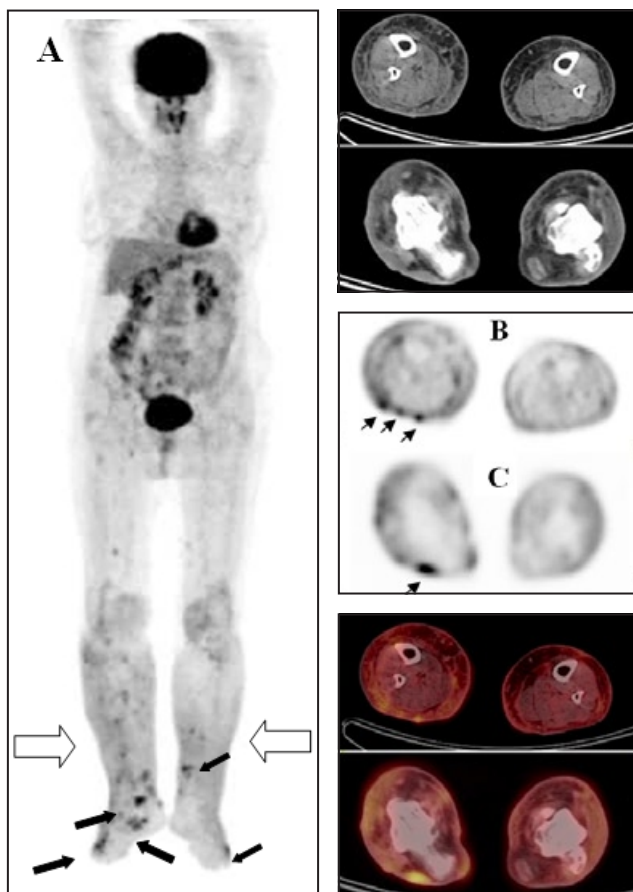


Figure 2. Second case, multifocal increased ^{18}F -FDG uptake in dermal and subdermal regions, representing ulcerated plaques disseminated on the distal portions of both legs are shown in anterior position of MIP image (black arrows, A), in axial section at the mid thigh (arrows, B) and at proximal heel level (arrow, C). Bilateral diffuse ^{18}F -FDG uptake seen in the distal portions of legs suggesting lymphedema and venous stasis was also notable (bold white arrows in A).

In conclusion, these two cases accentuated that HIV negative cutaneous KS can present with heterogeneous ^{18}F -FDG avidity. The ^{18}F -FDG study may be useful in initial staging and in treatment monitoring.

The authors have no conflicts of interest.

Bibliography

- Gao SJ, Kingsley L, Hoover DR et al. Seroconversion to antibodies against Kaposi's sarcoma-associated herpesvirus-related latent nuclear antigens before the development of Kaposi's sarcoma. *N Engl J Med* 1996; 335: 233.
- Gao SJ, Kingsley L, Li M et al. KSHV antibodies among Americans, Italians and Ugandans with and without Kaposi's sarcoma. *Nat Med* 1996; 2: 925.
- Martin JN, Ganem DE, Osmond DH et al. Sexual transmission and the natural history of human herpesvirus 8 infection. *N Engl J Med* 1998; 338: 948.
- Royle JS, Baade P, Joske D et al. Risk of second cancer after lymphohematopoietic neoplasm. *Int J Cancer* 2010 Sep 30. DOI: 10.1002/ijc.25706
- Riva G, Barozzi P, Torelli G et al. Immunological and inflammatory features of Kaposi's sarcoma and other Kaposi's sarcoma-associated herpesvirus/human herpesvirus 8-associated neoplasias. *AIDS Rev* 2010; 12: 40-51.
- Huppman AR, Orenstein JM. Opportunistic disorders of the gastrointestinal tract in the age of highly active antiretroviral therapy. *Hum Pathol* 2010; 41: 1777-87.
- Bernardini B, Faggion D, Calabró L et al. Imiquimod for the treatment of classical Kaposi's sarcoma. *Acta Derm Venereol* 2010; 90: 417-8.
- Merimsky O, Jiveliouk I, Sagi-Eisenberg R. Targeting mTOR in HIV-Negative Classic Kaposi's Sarcoma. *Sarcoma* 2008; 2008: 1-4.
- Brash DB, Bale AE. Molecular biology of skin cancer, In: VT DeVita Jr, S Hellman, S Rosenberg, Eds. *Cancer Principles and Practice of Oncology* LippincottWilliams &Wilkins, Philadelphia, Pa, USA. 2000; 1971-5.
- Costa da Cunha CS, Lebbe C, Rybojad M et al. Long-term follow-up of non-HIV Kaposi's sarcoma treated with low-dose recombinant interferon alfa-2b. *Arch Dermatol* 1996; 132: 285-90.
- Tur E, Brenner S, Michalevicz. Low dose recombinant interferon alfa treatment for classic Kaposi's sarcoma. *Arch Dermatol* 1993; 129: 1297-300.
- Salameire D, Templier I, Charles J et al. An "anaplastic" Kaposi's sarcoma mimicking a Stewart-Treves syndrome. A case report and a review of literature. *Am J Dermatopathol* 2008; 30: 265-8.
- Cannavò SP, Borgia F, Scimone A et al. Penile ulceration during pegylated doxorubicin chemotherapy of classical Kaposi's sarcoma. *Acta Derm Venereol* 2009; 89: 216-7.
- Osawa R, Kato N, Yanagi T et al. Clearance of recurrent, classical Kaposi's sarcoma using multiple paclitaxel treatments. *Acta Derm Venereol* 2007; 87: 435-6.

Fevziye Canbaz MD, Deniz Ersoy MD, Tarik Basoglu MD.

Departments of Nuclear Medicine, Ondokuz Mayıs University Hospital, Samsun, Turkey

Fevziye Canbaz MD, Assoc.Prof. of Nuclear Medicine
Ondokuz Mayıs University, Medical Faculty, Nuclear
Medicine Department, Kurupelüt 55139 Samsun, Turkey
Tel: +90 362 45760 00 + 26 46, Fax: +90 362 4576041
E-mail : fcanbaz@omu.edu.tr, fcanbazt@gmail.com

Hell J Nucl Med 2011;14(1): 74-75

Published on line: 5 March 2011