

# Unilateral pulmonary metastases from Ewing's sarcoma shown in a technetium-99m-methylene-diphosphonate bone scan

Ali Gholamrezanezhad<sup>1</sup>,  
Davoud Moinian<sup>2</sup>,  
Sahar Mirpour<sup>1</sup>,  
Hadi Hajimohammadi<sup>2</sup>

1. Nuclear Medicine Research  
Center, Tehran University of  
Medical Sciences, Tehran, Iran

2. 110 Nuclear Medicine  
Center, Tehran, Iran

☆☆☆

**Keywords:** Bone scintigraphy -  
<sup>99m</sup>Tc- MDP – Ewing's sarcoma –  
Lung uptake – Metastases

## Correspondence address:

Ali Gholamrezanezhad  
Research Center for Nuclear  
Medicine, Tehran University of  
Medical Sciences,  
Shariati hospital,  
Northern Kargar St.,  
14114 Tehran- Iran  
Tel: +98-0912-2107037,  
Fax: +98-21-88026905,  
E-mail:  
gholamrezanezhad@razi.tums.ac.ir

**Received:**

13 December 2005

**Accepted:**

23 June 2006

## Abstract

A 32-year-old man with a history of painful swelling of the right ankle underwent bone scintigraphy, which showed increased uptake in the right ankle and also unexpected diffuse uptake throughout the right hemithorax. A single photon emission tomography scan performed after the intravenous injection of 740 MBq of technetium-99m methylene-diphosphonate (<sup>99m</sup>Tc-MDP) showed abnormal uptake throughout the right lung. Computed tomography (CT) revealed a large mass in the right lower lobe. CT-guided biopsy of this mass led to a diagnosis of metastatic Ewing's sarcoma. Although lung uptake on bone scans has been noted in various occasions (such as: pulmonary alveolar microlithiasis, Pneumocystis carinii pneumonia, and various tumoral lesions), increased uptake of <sup>99m</sup>Tc-MDP in lung metastases of Ewing's sarcoma has not been reported according to our knowledge until now. We report such a case.

*Hell J Nucl Med 2006; 9(3): 181-183*

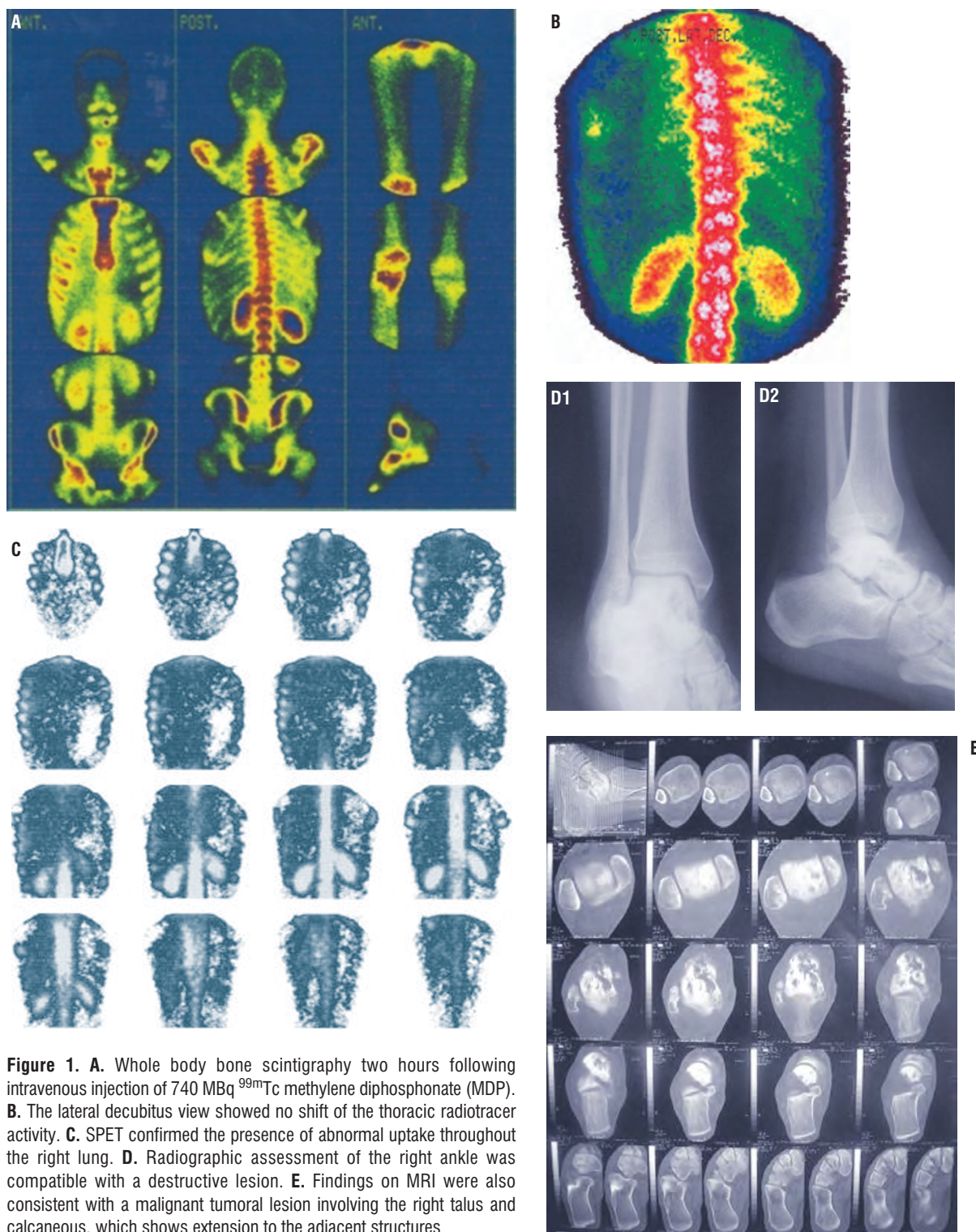
## Introduction

Lung uptake of <sup>99m</sup>Tc-methylene-diphosphonate (<sup>99m</sup>Tc-MDP) was detected in bone scans in various conditions [1], such as: pulmonary alveolar microlithiasis [2], pneumocystis carinii pneumonia [3], metastatic calcification [1,4] and pulmonary Waldenström's macroglobulinemia [5]. However, increased uptake of <sup>99m</sup>Tc-MDP in lung metastases of Ewing's sarcoma has not been reported according to our knowledge until now. This case is informative in order to prevent lung dysfunction by applying necessary treatment and is also prognostic as for the outcome of the disease.

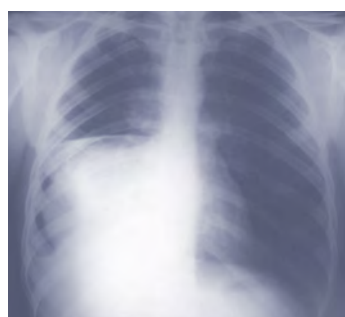## Clinical case

A 32-year-old man with history of painful swelling of the right ankle was referred for a bone scintigraphy. Immediately after intravenous injection of 740 MBq of <sup>99m</sup>Tc- MDP, imaging was performed from the anterior view of ankles. Perfusion and blood pool images showed diffusely increased activity around the right ankle (not shown). Delayed images (Fig. 1A) revealed intensely increased radiotracer uptake in the region of the talar head as well as unexpected diffuse uptake throughout the right hemithorax. There was no shift of the thoracic radiotracer activity on the lateral decubitus view (Fig. 1B). Single photo emission tomography (SPET) confirmed a range area of abnormal uptake in the lower lobe of the right lung (Fig. 1C). The scan findings in the right ankle corresponded to destructive lesions on the X-rays radiographs (Fig. 1D). Findings on magnetic resonance imaging (MRI) were also consistent with a malignant tumoral lesion involving the right talus and calcaneus, which showed extension to the adjacent structures (Fig. 1E). An open biopsy and immunohistochemistry analysis (positive for CD99, and negative for CD54 and EMA –Epithelial Membrane Antigen) confirmed the diagnosis of Ewing's sarcoma.

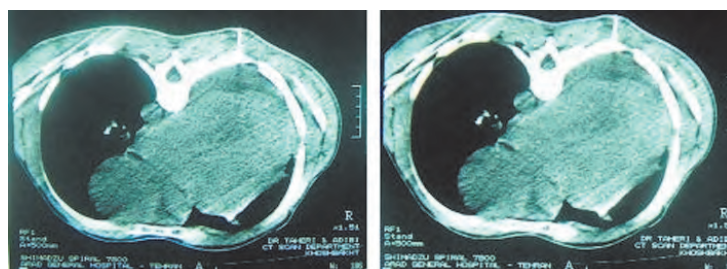
For better assessment of the unilateral diffuse lung uptake, a chest radiograph (Fig. 2) was requested, which raised the suspicion of pulmonary metastases. Physical examination was unremarkable and therefore as a complementary test, computed tomography (CT) of the chest was performed. Reformatted images of computed tomography (Fig. 3) clearly exhibited a large and hyperdense mass involving the lower and middle lobe of the right lung as well as multiple small nodular metastases in the upper lobe, consistent with the suspicion of disseminated pulmonary metastatic involvement. Finally, transdermal CT-guided biopsy of the lung mass was performed under local anesthesia. The histopathology test (hematoxylin and



**Figure 1.** A. Whole body bone scintigraphy two hours following intravenous injection of 740 MBq <sup>99m</sup>Tc methylene diphosphonate (MDP). B. The lateral decubitus view showed no shift of the thoracic radiotracer activity. C. SPET confirmed the presence of abnormal uptake throughout the right lung. D. Radiographic assessment of the right ankle was compatible with a destructive lesion. E. Findings on MRI were also consistent with a malignant tumoral lesion involving the right talus and calcaneus, which shows extension to the adjacent structures



**Figure 2.** A Chest radiograph was requested for better assessment of the underlying cause



**Figure 3.** Reformatted images of computed tomography.

eosin-100) demonstrated small pieces of lung tissue with aggregates of round cells, highly suggestive of metastatic Ewing's sarcoma. A follow-up scan two months later (not shown) revealed progress of the disease with metastatic involvement of several ribs.

## Discussion

Abnormal lung uptake of bone-avid agents can be observed in a wide variety of tumors most often in primary or metastatic breast and colon cancers and in neuroblastoma [1]. Also, in pulmonary metastasis from osteogenic sarcomas and chondrosarcomas on bone scans [6-8]. Moreover, in rare cases diffuse metastases in both parietal pleura and lung parenchyma were seen on bone scans, indicating of aggressive cancer disease [8]. However, as to our knowledge, there is no previous report concerning observation of pulmonary metastasis by Ewing's sarcoma detected incidentally on a bone scan. This report suggests that in Ewing's sarcoma SPET bone scan can identify lung metastases and thus prevent respiratory malfunctions and prognosticate the evaluation of the disease.

## Bibliography

1. HA Ziessman, PK Rehm. Case review: Nuclear medicine. Mosby. 2002: 132.
2. Shigeno C, Fukunaga M, Morita R, et al. Bone scintigraphy in pulmonary alveolar microlithiasis: a comparative study of radioactivity and density distribution. *Clin Nucl Med* 1982; 7: 103-107.
3. Vaquer RA, Dunn EK, Bhat S, et al. Reversible pulmonary uptake and hypertrophic pulmonary osteoarthropathic distribution of technetium-99m methylene diphosphonate in a case of *Pneumocystis carinii* pneumonia. *J Nucl Med* 1989; 30: 1563-1537.
4. Strain JP, Hill TC, Parker JA, et al. Diffuse, intense lung uptake on a bone scan: a case report. *Clin Nucl Med* 2000; 25: 608-610.
5. Ortapamuk H, Alp A. Lung uptake on a bone scan: a case of pulmonary Waldenstrom's macroglobulinemia. *Ann Nucl Med* 2002; 16: 487-489.
6. Mekhmandarov S, Engelberg S, Nass D, et al. <sup>99m</sup>Tc MDP uptake by metastatic chondrosarcoma in the lung. *Clin Nucl Med* 1989; 14: 369-371.
7. Tsuji T, Yamamuro T, Kotoura Y, et al. Uptake of <sup>99m</sup>Tc-MDP in lung metastasis from osteosarcoma: clinical and animal studies. *Nucl Med Commun* 1988; 9: 947-954.
8. Othman S, El-Desouki M. Bone scan appearance in aggressive osteogenic sarcoma with pleural, lung, bone, and soft-tissue metastases. *Clin Nucl Med* 2003; 28: 926.

