

Technetium-99m-dimercaptosuccinic acid renal scintigraphy in children with urinary tract infections

**Boris Ajdinović¹,
Ljiljana Jauković¹,
Zoran Krstić²,
Marija Dopuđa¹**

1. Institute of Nuclear Medicine,
Military Medical Academy,
Belgrade, Serbia & Montenegro
2. University Pediatric Clinic,
Belgrade, Serbia & Montenegro

☆☆☆

Keywords: Urinary tract infection – Vesicoureteral reflux – Static renal scintigraphy – Abnormal findings – Incidence

Correspondence address:

Professor Boris Ajdinović,
Institute of Nuclear Medicine,
Military Medical Academy,
Crnotravska 17,
11 000 Belgrade,
Serbia & Montenegro
Tel: +38111 661647,
+38163 687524,
E-mail:
borisajdinovic@yahoo.com

Received:

5 November 2005

Accepted revised:

26 January 2006

Abstract

The aim of this study was to determine the incidence of abnormal dimercaptosuccinic acid-Tc-99m (^{99m}Tc-DMSA) renal scintigraphy findings in children with culture proved urinary tract infection (UTI) with or without vesicoureteral reflux (VUR). ^{99m}Tc-DMSA renal scintigraphy was performed in 343 children with culture documented UTI (247 girls and 96 boys) aged from three months to 14 years (middle age of 4.82 years). The children studied were all those submitted for renal scintiscan to the Institute of Nuclear Medicine, Military Medical Academy, Belgrade, during a five-year period (2000-2004). Micturating cystoureterography (MCU) performed in all patients before ^{99m}Tc-DMSA scan, revealed VUR in 213 children, while in 130 children VUR was not detected by MCU. In 15 of the 213 children the grade of VUR was I, in 88 it was II, in 57 it was III, in 33 it was IV and 20 children had grade V of VUR. Findings of ^{99m}Tc-DMSA renal scintigraphy were classified as: normal, equivocal and abnormal. Statistical analysis was performed using the χ^2 test. Abnormal findings were detected in 38% (131/343), normal in 51% (174/343) and equivocal findings in 11% (38/343) of our patients. In children with UTI and VUR the incidence of abnormal findings was 53% (112/213), of normal 37% (80/213) and of equivocal findings 10% (21/213). In children with UTI without VUR the incidence of abnormal findings was 15% (19/130), of normal findings 72% (94/130), and of equivocal findings 13% (17/130). The incidence of abnormal findings was significantly higher in children with UTI and VUR than in those with UTI without VUR ($P < 0.001$). In children with VUR grades I, II, III, IV and V abnormal findings were 33%, 32%, 60%, 79% and 95% respectively. The incidence of abnormal findings was higher in children with VUR grades IV and V, than in grade I and II ($P < 0.001$). Our results suggest that ^{99m}Tc-DMSA renal scintigraphy in children can discriminate between grade I-II and IV-V of VUR and also that in children with UTI and VUR abnormal findings in the scintiscan were more than three times higher than in children with UTI alone.

Hell J Nucl Med 2006; 9(1): 27-30

Introduction

Urinary tract infection (UTI) is one of the most common diseases in childhood [1]. UTI may appear as cystitis, and/or pyelitis or pyelonephritis. Clinical presentation of UTI may be nonspecific and vary depending on the age of the child and the level of infection [2,3]. The diagnosis of acute pyelonephritis is made on the basis of the classical signs and symptoms of fever and flank pain or tenderness associated with pyuria and positive urine culture. However, diagnosis based on these parameters is often difficult in neonates and infants [4]. The ultimate goal of care of children with UTI is to prevent progressive renal damage with its consequences such as hypertension, complications of pregnancy and end stage renal disease [5,6]. Recurrent infections, multifocal /unifocal renal scarring and vesicoureteral reflux (VUR) may also appear and are risk factors for the development of renal damage [7,8]. VUR usually manifested by infection may be detected only in the advanced stages of the disease when hypertension and / or chronic renal failure are already present [9]. The most important consequence of VUR is reflux nephropathy and renal scarring which occurs in 25% of the children and younger adults with chronic renal failure [10]. Therefore, it is important to early diagnose and identify those patients who are at risk for having progressive renal damage.

Several imaging techniques have been used to evaluate the extent of parenchyma involvement by acute infection. Renal ultrasonography (US) is a noninvasive technique, highly reliable for the detection of hydronephrosis, congenital abnormalities, renal abscesses etc, however, it has a low sensitivity for the detection of acute UTI as compared with ^{99m}Tc-DMSA scan, underestimating the number and the extent of pyelonephritic lesions in the renal cortex [11-14]. Intravenous urography (IVU) also has a low sensitivity for the diagnosis of acute UTI. IVU was reported to be normal in 75% of adult patients with uncomplicated acute pyelonephritis [11,15,16]. Although computed tomography (CT) is a sensitive method, it is

not used routinely for the initial evaluation and follow up of children with UTI [17]. The role of magnetic resonance imaging in the diagnosis of acute pyelonephritis is yet to be determined [18]. Nuclear medicine techniques have been used over the years to evaluate renal function. Nephro-urologic radionuclide studies such as radionuclide cystography, renal ^{99m}Tc -DMSA scintigraphy, MAG3 renal diuresis-scintigraphy and ^{99m}Tc -DTPA renal diuresis-scintigraphy, are able to detect vesicoureteral reflux and reflux nephropathy [19].

Since the mid-1980s, various studies have demonstrated ^{99m}Tc -DMSA renal scintigraphy to be significantly more sensitive than IVU and US in the detection both acute pyelonephritis and renal scarring [20-22]. Also, ^{99m}Tc -DMSA renal scintigraphy can be considered the technique of choice for the detection of renal complications six months after acute UTI [23].

The aim of this study was to determine the incidence of abnormal ^{99m}Tc -DMSA renal scintigraphy findings in children with UTI and to evaluate the difference between UTI with or without VUR.

Patients and methods

^{99m}Tc -DMSA renal scintigraphy was performed in 343 children (247 girls and 96 boys) with UTI, aged three months to 14 years (middle age 4.82 years). The mean age was 5.27 years for the female, and 3.66 years for the male patients. All children had urine cultures with more than 10^5 bacteria (*E. coli* in more than 80% of the patients). Micturating cystoureterography (MCU) was also performed mostly one month prior to the ^{99m}Tc -DMSA scan, revealing VUR in 213 patients (bilateral VUR in 75 and unilateral VUR in 138 patients). In the remaining 130 patients VUR was excluded. VUR was graded after the MCU findings, following the recommendations of the International Reflux Study in Children [24]. Fifteen children presented VUR grade I, 88 children grade II, 57 children grade III, 33 children grade IV, and 20 children presented VUR grade V.

^{99m}Tc -DMSA renal scintigraphy was performed using a recommended standard procedure [25,26]. The patients were injected by a ^{99m}Tc -DMSA dose of 2 MBq / kg BW (minimum dose 20 MBq). Two to three hours after injection static images were taken in the supine, posterior, left and right posterior oblique and in the anterior views, using a gamma camera (Gamma Diagnost Tomo-Philips, Netherlands) equipped with computer PDP 11/34. For each projection 300,000 counts were acquired in 128×128 matrix size.

^{99m}Tc -DMSA scans were interpreted under the following criteria: renal position, size, shape, indentation of renal contour as well as the uniformity of the tracer uptake (focal and diffuse lesions). Relative tracer uptake in the entire kidney scan was given as the percent of tracer uptake in both kidneys, and was calculated as the mean value of uptake in the anterior and posterior projections, corrected for background activity. Scintigraphic findings were classified as normal, abnormal and equivocal. The criteria of normality included: regular kidney outlines and shape, no enlargement of kidneys or volume loss, absence of focal cortical defects and a relative left-to right renal cortical

uptake (RU) within the normal range (45%-55%). The abnormal findings were defined as showing a solitary cortical defect; multiple focal defects involving one or both kidneys; diffuse reduced uptake with renal volume loss and significant reduction in the function (more than 10% difference in RU between the two kidneys). The equivocal findings showed slightly reduced diffusely inhomogenous tracer uptake with no cortical defects.

Che square test was used for statistical analysis between the group of children with UTI and VUR and the group with UTI without VUR, and between the groups of children with different grade of VUR, considering the P value of less than 0.01 statistically significant.

Results

Out of 343 patients, ^{99m}Tc -DMSA scintigraphy showed abnormal scintigraphic findings in 38% of the patients, normal findings were obtained in 51% of the patients and equivocal findings in 11% (Table 1).

In the group of children with UTI and VUR the incidence of abnormal findings was 53%, the incidence of normal findings was 37% and equivocal findings 10%. In children with VUR grades I, II, III, IV and V abnormal findings were 33%, 32%, 60%, 79% and 95% respectively (Table 2). In children with UTI in whom the presence of VUR was excluded, incidence of abnormal findings was 15 %, normal findings were obtained in 72% and equivocal findings in 13% (Table 3).

Table 1. ^{99m}Tc -DMSA scintigraphy in 343 children with UTI

^{99m}Tc -DMSA findings	No of patients
Normal	174
Equivocal	38
Abnormal	131
Total	343

Table 2. ^{99m}Tc -DMSA scintigraphy according to the grades of VUR

VUR	Normal	Equivocal	Abnormal	Total
Grade I	10	0	5	15
Grade II	45	15	28	88
Grade III	19	4	34	57
Grade IV	6	1	26	33
Grade V	0	1	19	20
Total	80	21	112	213

Table 3. ^{99m}Tc -DMSA scintigraphy in children with UTI without VUR

^{99m}Tc -DMSA findings	No of patients
Normal	94
Equivocal	17
Abnormal	19
Total	130

The incidence of abnormal ^{99m}Tc -DMSA findings in children with UTI and VUR was significantly higher than in the group of children with UTI without VUR ($P < 0.001$), also significantly higher in children with VUR grades IV and V than in children with VUR grade I and II ($P < 0.001$).

The function of one kidney was assessed by relative tracer uptake. In the group of children with UTI without VUR, more than 10% difference of RU between two kidneys was shown only in 7% (10/130). In 138 patients with UTI and unilateral VUR, percent of RU decreased according to the severity of VUR, thus giving pathological value of RU in 24% of patients with VUR grade I – II (19/78) and more than 80% (49/60) in patients with higher grade of VUR (III, IV and V).

Discussion

^{99m}Tc -DMSA static renal scintigraphy was initially used as a morphologic imaging tool (Fig. 1). Although ^{99m}Tc -DMSA scanning can be useful in assessing congenital abnormalities or space occupying lesions, its major indication at present is the diagnosis of urinary tract infection (Fig. 2 and 3) [27-29]. The pathophysiological mechanisms of decreased uptake of ^{99m}Tc -DMSA in acute pyelonephritis are multifactorial [30]. Cortical uptake of ^{99m}Tc -DMSA is related to renal blood flow and distal tubular cell membrane fraction [31]. Pathological processes altering these parameters may result in focal or diffuse decreased uptake of ^{99m}Tc -DMSA. Experimental studies in animals demonstrated that interstitial damage due to ischemia and/or release of toxic enzymes and production of super oxides, reduces tubular uptake of ^{99m}Tc -DMSA and produces abnormalities seen on ^{99m}Tc -DMSA scintigraphy [32,33]. Ischaemia occurs early in the inflammatory response to acute pyelonephritis and precedes tubular cell dysfunction. Therefore the ^{99m}Tc -DMSA scan probably becomes positive early in the course of diseases, before any significant tissue damage has occurred.

There have been various studies reporting data for children with UTI who had undergone both MCU and ^{99m}Tc -DMSA renal scintigraphy [34-40]. Caione et al. (2004) detected renal damage in 188/282 kidneys with VUR (67%) and in 18/112 (16%) contralateral nonrefluxing kidneys [34]. Camacho et al. (2004) reported 26% abnormal ^{99m}Tc -DMSA scans performed in 152 children during acute UTI [35]. In our previous study the incidence of abnormal ^{99m}Tc -DMSA

scans was 10% (8/82) in the group of children with UTI alone, and 49% (43/88) in the group of children with UTI and VUR [36]. The heterogeneity of published results is evident and dependent on the type of patients included in the study, the retrospective or prospective character of the study, the time elapsing between acute infection and ^{99m}Tc -DMSA renal scan, the antibiotic treatment etc.

In the present study 38% of the children studied presented with abnormal findings, slightly fewer than those reported by other studies [34,36-40]. There may be several reasons for this such as that antibiotic treatment started before the ^{99m}Tc -DMSA scanning, UTI could be limited to the collecting system which is rarely detectable by the ^{99m}Tc -DMSA study etc.

VUR is one of the most frequent risk factors for the development of renal damage. In our group of patients 213 children demonstrated VUR of various grades. Our results, showing that abnormal ^{99m}Tc -DMSA findings were obtained in a significantly higher percentage in children with UTI and VUR (53%) as compared with children with UTI without VUR (15%) and also that a significantly high percentage of abnormal findings was found in patients with VUR grades IV and V, as compared to grade I and II, are concordant with other studies showing that 80%-90% of patients with UTI and VUR of high grade presented an abnormal ^{99m}Tc -DMSA renal scan [41,42]. Renal damage is more likely in patients with severe than with mild or moderate grade of reflux [41-44]. Hasson et al (2004) suggested that ^{99m}Tc -DMSA scintigraphy in infants with UTI may replace MCU as a first line investigation, and proposed a strategy to perform MCU only in patients with renal lesions [43]. Although, if VUR is present, a higher percentage of abnormal ^{99m}Tc -DMSA renal findings is expected, abnormal findings detected in patients without VUR suggest that renal damage may occur even in the absence of VUR. Urinary tract infection is often caused by *Escherichia coli*, as was found in our study [45,46]. Bacterial adherence to uroepithelial cells related to the presence of filamentous structures which specifically bind to the glycolipid receptors located on the surface of cells, has been described. [46] According to other studies, the incidence of renal damage in children after the first UTI without VUR is 12% and rises to 25% with recurrent UTI. In our group of patients 15% of children with recurrent UTI without VUR presented abnormal ^{99m}Tc -DMSA renal findings.

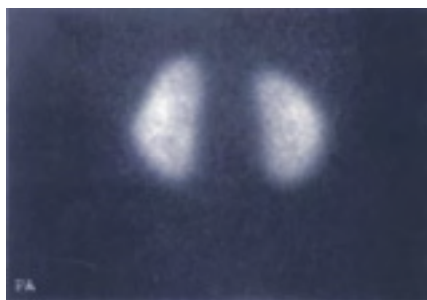

Figure 1. A normal DMSA study

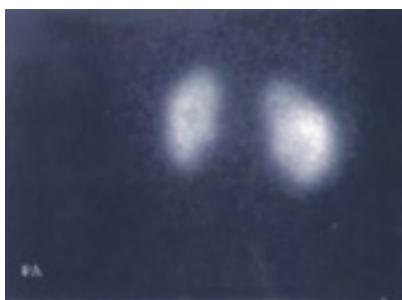


Figure 2. A ^{99m}Tc -DMSA scan in a patient with multiple cortical scars caused by bilateral reflux grade II/III

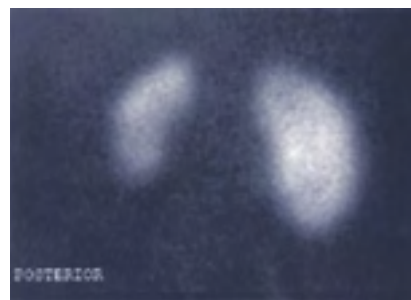


Figure 3. A ^{99m}Tc -DMSA scan in a patient with VUR grade V, posterior view, showing reduced uptake in the lower part of the smaller left kidney

In conclusion: Our results confirmed the importance of ^{99m}Tc -DMSA renal scintigraphy in the assessment of UTI in children with or without VUR. ^{99m}Tc -DMSA studies may suggest the type of treatment in these children or modify the further strategy such as the indication for a MCU. Well-controlled, prospective studies are needed.

Bibliography

- Rushton HG. Urinary tract infections in children: epidemiology, evaluation and management. *Pediatr Clin North Am* 1997; 44: 1133-1169.
- Stork JE. Urinary tract infection in children. *Adv Pediatr Infect Dis* 1987; 2: 115-134.
- Eggl DF, Tulchinsky M. Scintigraphic evaluation of pediatric urinary tract infection. *Semin Nucl Med* 1993; 3: 199-218.
- Bush R, Huland H. Correlation of symptoms and results of bacterial localization in patients with urinary tract infections. *J Urol* 1984; 132: 282-285.
- Jacobson SH, Eklof O, Eriksson CG, et al. Development of hypertension and uraemia after pyelonephritis in childhood: 27 year follow up. *BMJ* 1989; 299: 703-706.
- Smellie J, Barratt TM, Chantler C, et al. Medical versus surgical treatment in children with severe bilateral vesicoureteral reflux and bilateral nephropathy. A randomised trial. *Lancet* 2001; 357: 1329-1333.
- Merrick MV, Notghi A, Chalmers N, et al. Long term follow-up to determine the prognostic value of imaging after urinary tract infections. Part 1. Reflux. *Arch Dis Child* 1995; 72: 388-392.
- Merrick MV, Notghi A, Chalmers N, et al. Long term follow-up to determine the prognostic value of imaging after urinary tract infections. Part 2. Scarring. *Arch Dis Child* 1995; 72: 393-396.
- Ajdinovic B, Markovic M, Krstic Z, et al. Static ^{99m}Tc -DMSA renal scintigraphy in children with vesicourethral reflux. *Medicus* 2003; 4: 27-29.
- Greenfield P, Wan J. Vesicourethral reflux: Practical aspects of evaluation and management. *Pediatric nephrology* 1996; 10: 789-794.
- Stokland E, Hellstrom M, Jacobsson B, Sixt R. Imaging of renal scarring. *Acta Paediatr Suppl* 1999; 431: 13-21.
- Bjorgvinsson E, Majd M, Eggl KD, et al. Diagnosis of acute pyelonephritis in children: comparison of sonography and Tc-99m DMSA scintigraphy. *Am J Roentgenol* 1991; 157: 539-546.
- Puseljic S, Arambasic J, Gardasanic J, et al. The value of Tc 99m-DMSA renal scintigraphy in evaluation of parenchymal lesions in children with acute urinary tract infection. *Acta Med Croatica* 2003; 57: 5-10.
- Ataei N, Madani A, Habibi R, Khorasani M. Evaluation of acute pyelonephritis with DMSA scans in children presenting after the age of 5 years. *Pediatr Nephrol* 2005; 20: 1439-1444.
- Silver TM, Kass EJ, Thornburg JR, et al. The radiologic spectrum of acute pyelonephritis in adults and adolescents. *Radiology* 1976; 118: 65-71.
- Meyrier A, Condamin M-C, Fernet M, et al. Frequency of development of early cortical scarring in acute pyelonephritis. *Kidney Int* 1989; 35: 696-703.
- Mongomery P, Kuhn JP, Afshani E. CT evaluation of severe renal inflammation in children. *Pediatr Radiol* 1987; 17: 216-222.
- Raymond C, Tran-Dinh S, Bourguignon M, et al. Acute pyelonephritis in children. Preliminary results obtained with NMR imaging. *Contrib Nephrol* 1987; 56: 129-134.
- D'Errico G. The role of nuclear medicine in evaluation of vesicoureteral reflux and/or reflux nephropathy. *Rays* 2002; 27: 149-154.
- Thrall J, Ziessman H. Chapter 13. Genitourinary system. In: *Nuclear medicine the requisites*. 2nd edition Ed. Mosby 2001, St Lois, USA.
- Jacobsson B, Berg U, Svensson L. Renal scarring after acute pyelonephritis. *Arch Dis Child* 1994; 72: 111-115.
- Jacobsson B, Soderlundh S, Berg U. ^{99m}Tc -DMSA in the diagnosis of acute pyelonephritis in children: relation to clinical and radiological findings. *Pediatr Nephrol* 1992; 6: 328-334.
- Camacho V, Estorch M, Fraga G, et al. DMSA study performed during febrile urinary tract infection: a predictor of patient outcome. *Eur J Nucl Med Mol Imaging* 2004; 31: 862-866.
- Lebowitz RL, Olbing H, Parkkulainen KV, et al. International system of radiographic grading of vesicoureteric reflux: International Reflux Study in Children. *Pediatr Radiol* 1985; 15: 105-109.
- Piepsz A, Hahn K, Roca I, et al. A radiopharmaceutical schedule for imaging in paediatrics. Pediatric Task Group European Association Nuclear Medicine. *Eur J Nucl Med* 1990; 17: 127-129.
- Piepsz A, Blafox MD, Gordon I, et al. Consensus of renal cortical scintigraphy in children with urinary tract infection. Scientific Committee of Radionuclides in Nephrourology. *Semin Nucl Med* 1999; 29: 160-174.
- Jaksic E, Beatovic S, Paunkovic N, et al. Variability of interpretation of static renal scintigraphy findings. *Vojnosanit Pregl* 2005; 62(3): 189-193.
- Gordon I. Indications for ^{99m}Tc -DMSA scan in children. *J Urol* 1987; 137: 464-470.
- Gordon I. Urinary tract infection in pediatrics: the role of diagnostic imaging. *Br J Radiol* 1990; 63: 507-511.
- Majd M, Rushton H. Renal cortical scintigraphy in the diagnosis of acute pyelonephritis. *Semin Nucl Med* 1992; 22: 98-111.
- Yee CA, Lee HB, Blafox MD. Tc-99m DMSA renal uptake: influence of biochemical and physiological factors. *J Nucl Med* 1981; 22: 1054-1058.
- Risdon RA, Godley ML, Parkhouse HF, et al. Renal pathology and the ^{99m}Tc -DMSA image during the evolution of the early pyelonephritic scar: an experimental study. *J Urol* 1994; 151: 767-773.
- Kaack MB, Dowling KJ, Patterson GM, et al. Immunology of pyelonephritis. VIII. E coli causes granulocytic aggregation and renal ischemia. *J Urol* 1986; 136: 1117-1122.
- Cainoe P, Ciofetta G, Collura G, et al. Renal damage in vesico-ureteral reflux. *BJU Int* 2004; 93: 591-595.
- Camacho V, Estorch M, Fraga G, et al. DMSA study performed during febrile urinary tract infection: a predictor of patient outcome? *Eur J Nucl Med Mol Imaging* 2004; 31: 862-866.
- Ajdinovic B, Krstic Z, Dopudja M, et al. Renal scintigraphy in children with urinary tract infection. *Vojnosanit Pregl* 2005; 10: 745-779.
- Stokland E, Hellstrom M, Jacobsson B, et al. Early ^{99m}Tc -DMSA scintigraphy in symptomatic first-time urinary tract infection. *Acta Paediatr* 1996; 85: 430-436.
- Majd M, Rushton HG, Jantusch B, Wiedermann BL. Relationship among vesicourethral reflux, P-fimbriated Escherichia coli, and acute pyelonephritis in children with febrile urinary tract infection. *J Pediatr* 1991; 119: 578-585.
- Gordon I, Barkovics M, Pindoria S, et al. Primary Vesicoureteric Reflux as a Predictor of Renal Damage in Children Hospitalised with Urinary Tract Infection: A Systematic Review and Meta-Analysis. *J Am Soc Nephrol* 2003; 14: 739-744.
- Szluk GR, Williams SB, Majd M, et al. Incidence of new renal parenchymal inflammatory changes following breakthrough urinary tract infection in patients with vesicoureteral reflux treated with antibiotic prophylaxis: evaluation by 99m Technetium dimercaptosuccinic acid renal scan. *J Urol* 2003; 170: 1566-1568.
- Cascio S, Chertin B, Colhoun E, Puri P. Renal parenchymal damage in male infants with high grade vesicoureteral reflux diagnosed after the first urinary tract infection. *J Urol* 2002; 168: 1708-1710.
- Goldraich NP, Manfroi A. Febrile urinary tract infection: Escherichia coli susceptibility to oral antimicrobials. *Pediatr Nephrol* 2002; 17: 173-176.
- Hasson S, Dhamey M, Sigstrom O, et al. Dimercapto-succinic acid scintigraphy instead of voiding cystourethrography for infants with urinary tract infection. *J Urol* 2004; 172: 1071-1073.
- Lin Ky, Chiu NT, Chen MJ, et al. Acute pyelonephritis and sequelae of renal scar in pediatric first febrile urinary tract infection. *Pediatr Nephrol* 2003; 18: 362-365.
- Shaw KN, Gorelich MH. Urinary tract infection in pediatric patient. *Pediatr Clin North Am* 1999; 46: 1111-1124.
- Leffler H, Svanborg EC. Chemical identification of a glycosphingolipid receptor for Escherichia coli attaching to human urinary tract epithelial cells and agglutinating human erythrocytes. *FEMS Microbiol Lett* 1980; 8: 297-302.

