

Sialocintigraphy versus ultrasonography of the salivary glands in patients first diagnosed with Sjögren's syndrome

Marco Decuzzi¹,
 Francesca Tatulli¹,
 Maria Giampaolo²,
 Riccardina Tesse³,
 Marianna Gasparre¹,
 Giovanna Pepe¹,
 Paolo Decuzzi⁴,
 Ioannis Asteriadis⁵

1. Nuclear Medicine Policlinico, Bari, Italy
2. Internal Medicine Policlinico Bari, Italy
3. Clinical Pediatric Policlinico Bari, Italy
4. Politecnico Bari, Italy
5. Nuclear Medicine Department, Kavala, Greece

★★★

Keywords: Parotid salivary gland – Submandibular salivary gland – Sjögren's syndrome – Salivary gland scintigraphy – Salivary gland ultrasound

Correspondance address:

Ioannis Asteriadis
 Director,
 Department of Nuclear Medicine,
 Kavala Hospital, Greece,
 Tel: +30 2510 292652,
 E-mail: ioa-aste@otenet.gr

Received:

29 March 2006

Accepted revised:

10 June 2006

Abstract

Sjögren's syndrome (SjS) is an autoimmune disease characterized by dysfunction of particularly salivary and lacrimal glands. The aim of the present study was to compare salivary gland scintigraphy (SGS) and salivary gland ultrasonography (SUS) in identifying salivary gland function in patients first diagnosed with SjS. We recruited 20 such patients with SjS (5 male, 15 female, aged from 35 to 65 y, mean age 52, standard deviation: ± 5 y. All patients were submitted to SUS and SGS longitudinal and transverse images. Before the scintiscan, patients fasted for 6 h. Technetium-99m pertechnetate (^{99m}Tc-PT) 110 MBq was injected intravenously (i.v.) and simultaneous multi-frames dynamic acquisition was performed for 30 min. In two patients who had discordant results between SUS and US, labial biopsy was performed. Dynamic acquisition curves for 30 sec for the parotid and the submandibular glands were generated. For each gland we have calculated: (a) the maximum uptake (MU): the ratio between the mean counts in the gland at 20 min and the background activity and (b) the outflow efficiency (OE): the ratio between the minimum counts after lemon juice stimulation at 30 min and the counts at 20 min. The results showed abnormal scintiscans with low MU and high OE in one or more of the glands, in 17/20 patients. These results were confirmed by SUS in 15 cases and in two cases labial biopsy confirmed the diagnosis made by SGS while SUS was negative. In the remaining 3/20 cases of SjS both tests, SUS and SGS, showed normal results. Discrepancies between SGS findings and labial biopsy as found in two of our cases, have been reported by others and may be due among other causes, to early lymphocytic infiltration in SjS. Normal findings of SGS have also been reported. *In conclusion*, in cases first diagnosed with SjS, the function of the parotid and the submandibular glands was better identified by the SGS as compared to SUS. Although SGS is a more complex and expensive examination, it should be preferred to SUS as more sensitive and indicating the stage of SjS.

Hell J Nucl Med 2006; 9(2): 103-105

Introduction

Sjögren's syndrome (SjS) is an autoimmune disease characterized by dysfunction of particularly salivary and lacrimal glands. Clinical features are secondary to exocrine gland dysfunction [1-5]. There is a chronic inflammatory process leading to a decreased salivary flow. Xerostomia and xerophthalmia are the most common symptoms of SjS [2,6]. Numerous techniques have been validated for diagnosing SjS: labial salivary gland biopsy, salivary gland scintigraphy (SGS) and salivary gland ultrasonography (SUS). The clinical use of labial salivary gland biopsy is rather limited because of its invasiveness. The use of SUS and of SGS is expanding because of their non invasiveness and high sensitivity. Advantages and disadvantages of both techniques are of interest because are often used in routine [2]. Also, it is of interest to know in patients first diagnosed with SjS whether the function and imaging of the salivary glands is related to the stage of the disease [7]. The aim of the present study was to compare SGS and SUS in identifying salivary gland function and scintigraphic image in patients who were at first diagnosed with SjS.

Subjects and methods

We recruited 20 first diagnosed patients with SjS (5 male, 15 female, aged from 35 to 65 y, mean age 52, standard deviation: ± 5 y. All patients were submitted first to SUS (Fig. 1). A high-resolution 7.5 MHz linear transducer was used (Esaote Technos, MPX). Patients were invited to turn laterally their heads to examine each gland. Longitudinal and transverse images of each parotid and submandibular gland were then taken. Regular border, normal or enlarged dimensions and punctate hypoechoic lesions were considered as early destructive

changes (Stage I), whereas irregular border, reduced dimensions, multicystic or reticular pattern, calcification and hyper-echoic stripes indicated late destructive changes of the glands (Stage II) (Table 1). After SUS all patients were submitted to SGS. Before the scintiscan, patients fasted for 6 h. Technetium-99m pertechnetate ($^{99m}\text{Tc-PT}$) 110 MBq was injected intravenously (i.v.) and simultaneous multi-frames dynamic acquisition was performed for 30 min. SGS were evaluated by one of the authors blinded to the SUS results and vice versa. Acquisition parameters were: single head gamma camera, parallel high resolution collimator, matrix 128×128 , 60 frames, 30 sec/frames. In two patients who had discordant results between SUS and US, labial biopsy was employed.

Twenty min after the injection of the radiopharmaceutical, a 5 ml solution of lemon juice was administered as a stimulus for sialorrhea. Regions of interest (ROIs) were drawn manually over each salivary gland. As background we drew a ROI over the chin. Time activity curves were generated. Two parameters, for each gland, were calculated: (a) the maximum uptake (MU): the ratio between the mean counts in the gland at 20 min and the background activity (normal value: $>0.43 \pm 0.16$ for the parotid gland; $>0.43 \pm 0.13$ for the submandibular gland) [8] and (b) the outflow efficiency (OE): the ratio between the minimum counts after lemon juice stimulation at 30 min and the counts at 20 min (normal value: 47.4 ± 11.7 for the parotid gland; 37.4 ± 9.8 for the submandibular gland). Four different types of the time activity curves were considered: (A and B): the normal type - good accumulation and excretion of the $^{99m}\text{Tc-PT}$ at 30 min (the B type has data borderline to the median type); (C): the median type - lower accumulation and excretion (MU: 0.22 ± 0.5 for the parotid gland; 0.25 ± 0.5 for the submandibular gland) (OE: 38 ± 10 for the parotid gland; 27 ± 10 for the submandibular gland) (Fig. 3); (D): the poor excretion type - good accumulation but poor excretion (MU: $>0.43 \pm 0.16$ for the parotid gland and $>0.43 \pm 0.13$ for the submandibular gland) (OE: 28 ± 10 parotid gland; 17 ± 10 submandibular gland); and (E): the flat type - accumulation and excretion (MU: <0.16 for the parotid gland and >0.19 for the submandibular gland) (OE: <17 for the parotid gland and <7 for the submandibular gland).

Results

The results showed abnormal scintiscans with a low MU and high OE in one or more of the glands, in 17/20 patients submitted to scintigraphy (Table 1), that were confirmed by SUS in 15 cases. In the two cases, which were positive on SGS but negative on SUS, a labial biopsy confirmed the diagnosis made by SGS. In the remaining three cases of SjS the SUS and SGS findings were normal. Figure 1 shows early destructive changes and

stage II changes in SUS, in one of our patients. Figure 2 shows a normal SGS in one of our patients with SjS and a median type accumulation of the radiopharmaceutical in the salivary glands. Normal dynamic acquisition curves for 30 sec for the parotid and the submandibular glands and flat type dynamic curves for the submandibular glands are shown in Figure 3. The submandibular glands had more severe involvement regarding the parotids as expressed by their lower OE values compared to the OE of the parotids.

Discussion

Discrepancies between SUS findings and labial biopsy as in two of our cases have been reported by others [8,9]. This may be due to the early lymphocytic infiltration before actual salivary gland disease which causes no pathologic scintiscan imaging [8]. Also, to the fact that when the SjS is first diagnosed, the disease may be at a very early stage or the salivary gland participation may be slow. It is of diagnostic interest to try to correlate the normal and the abnormal SGS and SUS findings to the stage of SjS. Labial biopsy is considered a threshold for the diagnosis of the salivary component of SjS [5]. Others have shown in SjS that SGS with related clearance curves of the $^{99m}\text{Tc-PT}$ is a sensitive method for detecting minimal injuries of the salivary glands [9]. Normal findings of SGS in SjS have also been reported [9]. Others consider sequential SGS as optional in the diagnostic evaluation of the oral component of SjS [8]. Compared with clinical and histological data, SGS provides a sensitive method, even though not specific, for detecting salivary gland function in patients with SjS. The SGS findings correlated well to the stage of the SjS in our cases according to the physicians (Table 1). This point is subject to further investigation.

In conclusion, in cases of SjS, the function of the parotid and the submandibular glands was better identified by the SGS as compared to SUS. Early stages of the disease in two patients were revealed by the SGS but not by the SUS technique. Com-

Table 1. Time activity curves in the parotid and submandibular salivary glands and also ultrasonography findings, in our patients

Pts (20)	Type of time activity curve	Scintigraphy - time activity patterns		SUS findings	Clinical findings
		Parotid gland	Submandibular gland		
6	D	MU: $>0.43 \pm 0.16$ OE: 28 ± 10	$>0.43 \pm 0.13$ 17 ± 10	II	Xerostomia, xerophthalmia, dysphagia
7	C	MU: 0.22 ± 0.5 OE: 38 ± 10	0.25 ± 0.5 27 ± 10	I/II	Xerostomia, xerophthalmia, dysphagia
2	B*			I	Xerostomia
2**	B*			Normal	Xerostomia
3	A	MU: $>0.43 \pm 0.16$ OE: 47.4 ± 11.7	$>0.43 \pm 0.13$ 37.4 ± 9.8	Normal	No symptoms

* B: values between A and C closer to C

** Labial biopsy was only performed in these two patients with time activity curves (B) and normal SUS findings and was positive in both cases; MU: maximum activity; OE: outflow efficiency

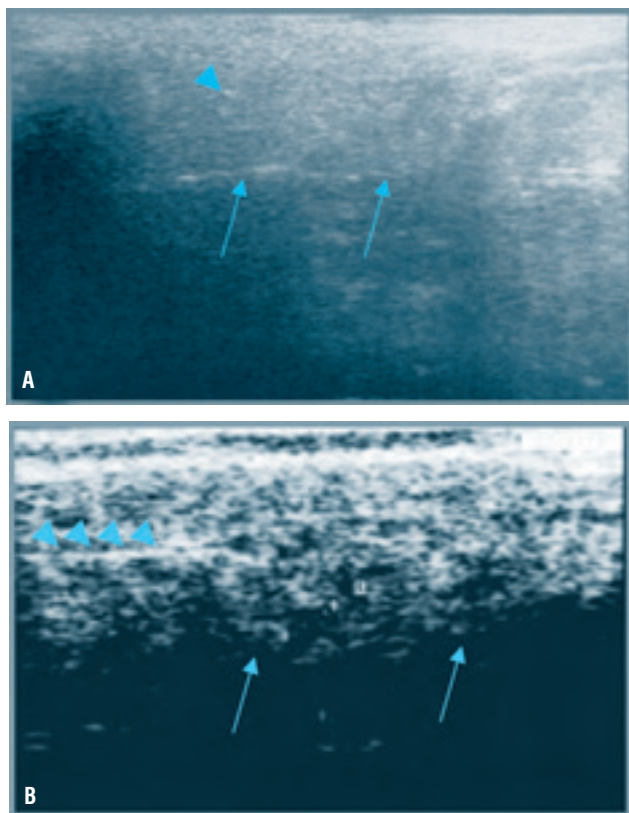


Figure 1. Typical findings in the SUS films in one of our patients. A: Regular border (arrows), normal or enlarged dimensions and punctuate hypoechoic lesions (arrowhead) were taken as early destructive changes B: Irregular border (arrows), reduced dimensions, multicystic or reticular pattern, calcification and hyperechoic stripes (arrowheads) were taken as indicating the late Stage (II) of SjS

paring clinical findings with our results as shown in Table 1, we suggest that SGS supported the diagnosis of the early or advanced stage of the disease in cases of first diagnosed SjS. Although SGS is a more complex and expensive examination, it should be preferred to SUS as being more objective, gives functional data and is more sensitive than SUS findings.

Bibliography

1. Nakuw S, Gershwin ME. Sjögren's syndrome. Chapter 282. In: *Cecil's Textbook of Medicine*, ed by Goldmann L, Ausiello D, 22nd edn, Saunders AB, New York, 2004, p 1677-1680.
2. Daniels TE. Diseases of the mouth and salivary glands. Chapter 467. In: *Cecil's Textbook of Medicine*, ed by Goldmann L, Ausiello D, 22nd edn, Saunders AB, New York, 2004, p 2426-2432.
3. Polastri F, Notarantonio A, Pancotti G, Dogliani N. The role of biopsy of the minor salivary glands in the diagnosis of Sjögren's syndrome. *Minerva Stomatol* 1992; 41: 401-407.
4. Lopez Amado M, Carcia Sarandeses A, Martinez Vidal J. Biopsy of minor salivary glands: indication and implementation. *Acta Otorrinolaringol Esp* 1993; 44: 399-401.
5. Cleary KR, Batsakis JG. Biopsy of the lip and Sjögren's syndrome. *Ann Otol Rhinol Laryngol* 1990; 99: 323-325.
6. Valesini G, Priori R, Borsetti A, et al. Clinical serological correlations in the evaluation of Sjögren's syndrome. *Clin Exp Rheumatol* 1989; 7: 197-202.
7. Calcagni ML, Di Giuda D, De Rossi G. Salivary gland disorders. In: Mur-

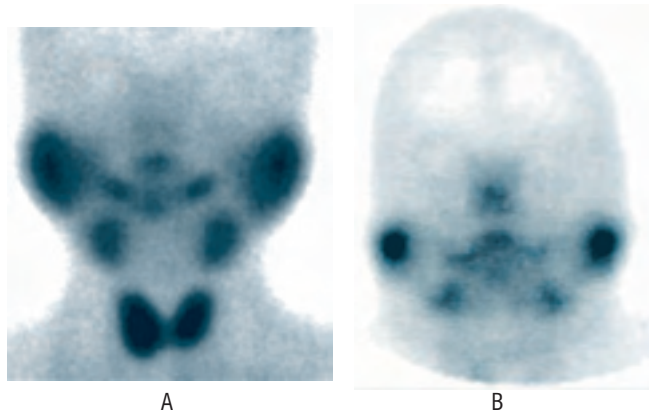


Figure 2. Typical findings in the SGS in one of our patients: A: normal, B: median type lower than normal, accumulation of the radiopharmaceutical by the parotid and the submandibular glands

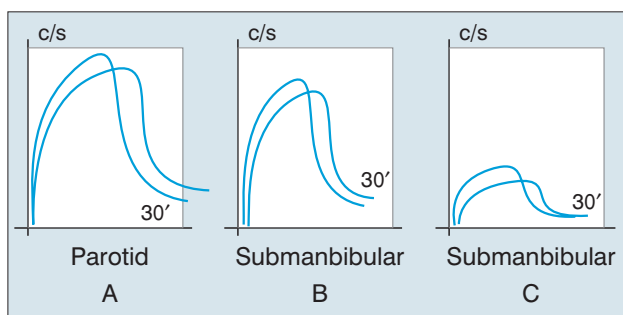


Figure 3. Activity curves indicating accumulation of the radiopharmaceutical in the parotid and the submandibular salivary gland up to 30 min. A, B: normal uptake; C: decreased uptake at the submandibular gland

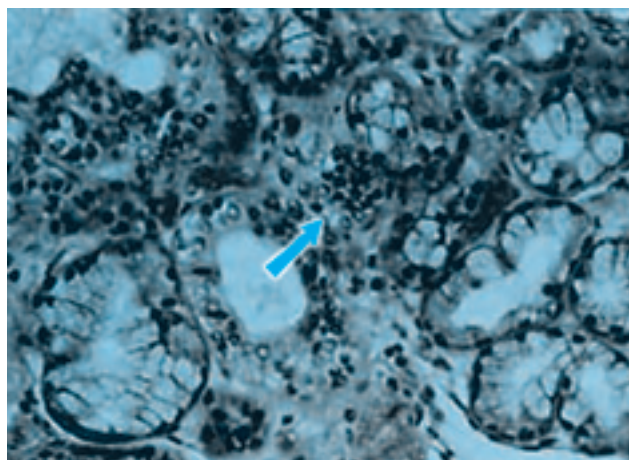


Figure 4. Labial biopsy reveals lymphocytic cells near normal ducts

- ray IPC, Ell PJ eds. *Nuclear Medicine in Clinical Diagnosis and treatment*. Churchill Livingstone; 2nd edn, 1998, vol. 1: 392-402.
8. Daniels TE, Powell MR, Sylvester RA, Talal N. An evaluation of salivary scintigraphy in Sjögren's syndrome. *Arthritis Rheum* 1979; 22: 809-814.
9. Arrago JP, Rain JD, Brocheriou C, Rocher F. Scintigraphy of the salivary glands in Sjögren's syndrome. *J Clin Pathol* 1987; 40: 1463-1467.
10. Bohuslaviszki KH, Brenner W, Wolf H, et al. Value of quantitative salivary gland scintigraphy in the early stage of Sjögren's syndrome. *Nucl Med Com* 1995; 16, 917-922.