

# Comparison of technetium-99m IgG with technetium-99m red blood cells labeling in cardiac blood-pool scintigraphy: a preliminary study

Hamid Javadi<sup>1</sup> MD,  
Isa Neshandar Asli<sup>2</sup> MD,  
Shahriar Semnani<sup>1</sup> MD,  
Sara Jallalat<sup>1</sup> MD,  
Mojtaba Ansari<sup>3</sup> MD,  
Abdullatif Amini<sup>4</sup> MD,  
Maryam Barekat<sup>4</sup> MD,  
Majid Assadi<sup>4</sup> MD

1. Golestan Research Center of Gastroenterology and Hepatology (GRCGH), Golestan University of Medical Sciences, Gorgan, Iran

2. Department of Nuclear Medicine, Taleghani Hospital and 3 Department of Nuclear Medicine, Emam Hossein Hospital, Shaheed Beheshti University of Medical Sciences, Tehran, Iran

4. The Persian Gulf Nuclear Medicine Research Center, Bushehr University of Medical Sciences, Bushehr, Iran

\*\*\*

Keywords: Cardiac blood-pool scintigraphy  
- Technetium-99m IgG  
- Technetium-99m red blood cells  
- Left ventricular ejection fraction (LVEF)

## Correspondence address:

The Persian Gulf Nuclear Medicine Research Center, The Persian Gulf Biomedical Sciences Institute, Boostan 19 Alley, Imam Khomeini Street, Bushehr, Iran  
Tel: 0098-771-2580169  
Fax: 0098-771-2541828  
E-mail: assadipoya@yahoo.com, asadi@bpums.ac.ir

Received:

28 October 2010

Accepted revised:

16 January 2011

## Abstract

This first clinical prospective study was conducted to use of technetium-99m immunoglobulin G (<sup>99m</sup>Tc-IgG) as compared with autologous <sup>99m</sup>Tc-red blood cells (RBC) in gated blood pool ventriculography. *We studied* 12 patients who referred to us for a possible diagnosis of liver hemangioma or infection. Six patients underwent gated planar blood pool (GPBP) acquisition using <sup>99m</sup>Tc-RBC and 6 GPBP acquisition using <sup>99m</sup>Tc-IgG. *The use of <sup>99m</sup>Tc-IgG* in cardiac blood pool studies provided comparable images to <sup>99m</sup>Tc-RBC. *In conclusion*, <sup>99m</sup>Tc-IgG, which is readily available and needs only a single injection, may be an attractive alternative to <sup>99m</sup>Tc-RBC for the estimation of various cardiac function parameters like left ventricular function .

*Hell J Nucl Med* 2011; 14(1): 30-33

Published on line: 26 March 2011

## Introduction

Left ventricular (LV) function and ejection fraction (EF) studied by radionuclidic echocardiographic techniques have long been diagnostic factors associated with cardiac function [1-3]. However, echocardiographic investigations (ECHO) may have poor reproducibility and be unable to diagnose some lesions like those in the endocardium and the apex [4, 5] and gated single photon emission tomography (GSPET) perfusion studies may be difficult to identify lesions with marked hypoperfusion [6]. Gated blood pool ventriculography (GBP) is usually carried out by labeling autologous red blood cells (RBC) with <sup>99m</sup>Tc-RBC [7]. Practical drawbacks of the <sup>99m</sup>Tc-RBC technique time and labor and the necessary manipulations of blood samples with a possible risk of contamination [8]. A number of studies have tried to use other blood-pool agents in addition to <sup>99m</sup>Tc-RBC [9-13].

This article presents the first clinical prospective study using <sup>99m</sup>Tc-gamma immunoglobulin (IgG) as compared with <sup>99m</sup>Tc-RBC in GBP, by measuring organ activity ratios and image quality.

## Patients and methods

The study population included 12 patients (7 men and 5 women mean age 59.92±8.07 years) who had been referred to us for possible diagnosis of liver hemangioma or infection (Table 1). None had symptoms of typical or atypical ischemic heart disease (IHD) such as chest pain, history of myocardial infarction (MI), congestive heart failure, arrhythmia or history of coronary interventions such as catheterization or coronary angioplasty.

Six patients underwent GBP acquisition using <sup>99m</sup>Tc-RBC (Fig. 1), and the remaining six cases underwent GBP with <sup>99m</sup>Tc-IgG (Fig. 2).

This study complied with the declaration of Helsinki and was approved by the Institutional Ethics Committee of Golestan University of Medical Science. All patients signed a written fully informed consent.

Technetium-99m-RBC labeling was carried out using a modified in vitro method (ex-vivo) [10, 14]. The radiopharmaceutical was administered by direct intravenous (i.v.) injection [15]. According to this technique, at least 10min after stannous chloride administration (0.5mg to 2mg), 2-3mL of blood is withdrawn from the subject into a containing <sup>99m</sup>TcO<sub>4</sub> syringe, and then administered using separate venous access to that used for the stannous chloride administration previously. More than 95% labeling efficiency was achieved by this direct technique. For <sup>99m</sup>Tc-IgG preparation, a human nonspecific polyclonal IgG solution

with a concentration of about 10mg/mL in 0.01 M phosphate buffered saline (PBS) of pH 7.4 was acquired. Protein concentration was appraised by Lowry technique [16]. The IgG was reduced by reacting with a molar excess of 2-mecaptoethanol 2000:1 (2-ME:IgG) and was incubated for 30min at room temperature. The reduced solution was then purified by eluting through a 1×15cm sephadex G25 column, using nitrogen purged phosphate buffered saline (PBS) as mobile phase. Aliquots containing 1mg of reduced protein and 20μL of previously reconstituted solution with 5mL of saline were mixed, passed through a 0.22μ membrane filter and then frozen in -80°C. The frozen products were lyophilized for 48h, sealed under vacuum, and stored at 4°C until use. For <sup>99m</sup>Tc labeling, vials of lyophilized reduced IgG were reconstituted with 740MBq of <sup>99m</sup>TcO<sub>4</sub><sup>-</sup> eluted from a <sup>99</sup>Mo/<sup>99m</sup>Tc generator (Atomic Energy Organization of Iran, Tehran, Iran) [16]. The total cost of each compound was approximately \$60.

Gated BPV images were obtained and processed with commercially available software. For LVEF assessment, an observer (H.J) delineated the initial LV contours at end systole (ES) and end diastole (ED).

Background (bg) region of interest (ROI) were also acquired by use of a 2 to 3 pixel-wide crescent-shaped region located about 2 pixels far from the posterolateral wall. After the subtraction of a bg region surrounding the LV, EF was calculated by following formula:

$$EF(\%) = [(ED \text{ counts} - ES \text{ counts})/ED \text{ counts}] * 100.$$

In addition, activities within the aforementioned bg region and the ED image of the LV were calculated and expressed in counts per pixel (c/p) to determine the LV/bg ratio.

In order to evaluate the activity ratios in different organs, regions of interest (ROI) were manually drawn over the LV, right ventricle (RV), right lung, left lung, aorta, liver, and spleen on the static anterior datasets at 20min (early) and at 180min (delayed) post injection of <sup>99m</sup>Tc-RBC (Fig. 1) and of <sup>99m</sup>Tc-IgG (Fig. 2). These ROI also were expressed in c/p. The c/p ratios between early and delayed views were compared for each ROI.

Image quality was also blindly assessed by two observers (M.M and M.A) using as criteria the simplicity of outlying the ED and ES, LV edges. Quality was classified as good, mild, or poor for both radiotracers. The data were expressed as mean±standard deviation (±SD); the Mann-Whitney *U* test was applied for quantitative comparison, and differences in proportion (categorical variables) were assessed by the chi-square test. A *P* value of <0.05 was considered statistically significant.

## Results

None of the patients had any adverse reactions such as nausea, flushing, coughing, dyspnea, muscle cramps or dizziness after the i.v. injection of <sup>99m</sup>Tc-IgG. The mean acquisition times following injection of each radiotracer are shown in Table 1. Observers 1 and 2 based upon image qualities considered both radiotracers as of good quality for all participants. The demographic data and GBPV parameters including mean count/frame, EF, peak filling rate–end diastolic volume per second(PFR-EDV/S), peak filling rate (PFR), peak emptying rate (PFR)– EDV/sec, PER and LV/BKG between the two groups were not statistically different (Table 1).

A contrast analysis of both compounds was carried out in terms of organ c/p ratios between early and delayed images. The mean c/p of the LV and the RV to the bg ratios on early and delayed views in patients with <sup>99m</sup>Tc-IgG were greater, relative to patients who had been tested with radiolabeled <sup>99m</sup>Tc-RBC (Table 2). The ten (as shown in Table 2) ratios in the early and delayed views between the two radiotracers were not significantly different (*P* value>0.05).

In addition, organ ROI c/p was compared with respect to the biodistribution of the two radiopharmaceuticals over time by subtracting ROI c/p of early acquired, from delayed ROI of the static images. This comparison showed that the washout rate of <sup>99m</sup>Tc-IgG relative to <sup>99m</sup>Tc-RBC was not significantly different (Fig. 3).

**Table 1.** The main characteristics and results of the two groups studied

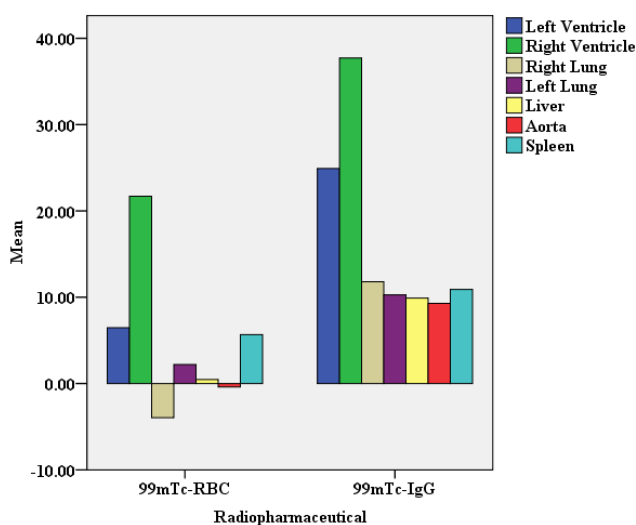
Radiopharmaceutical	<sup>99m</sup> Tc-RBC	<sup>99m</sup> Tc-IgG	<i>P</i> value
Age (year)	62.00± 8.87	57.83±7.36	0.37
Male/Female	4/2	3/3	0.55
Post injection time of acquisition (min.)	75.83±11.75	80.00±7.09	0.63
Mean count/frame	326.50±187.30	424.17±239.81	0.42
EF (%)	59.00±7.64	58.33±16.03	0.52
PFR-EDV/S	3.20 ±0.77	2.49±0.62	0.15
PFR (ms)	459.50 ±39.09	491.33±49.84	0.15
PER-EDV/S	-3.02±0.51	-2.62±0.74	0.15
PER(ms)	97.00±20.74	112.00±21.53	0.15
LV/BKG	2.55±0.99	2.11±0.78	0.52

EF, ejection fraction; PFR-EDV/S, peak filling rate–end diastolic volume per second; PFR (ms), peak filling rate in millisecond; PER-EDV/S, peak emptying rate–end diastolic volume second; PER(ms), peak emptying rate in millisecond; LV/BKG, left ventricle/ bg.

**Table 1.** The main characteristics and results of the two groups studied

Parameter	Phase	<sup>99m</sup> Tc-RBC	<sup>99m</sup> Tc-IgG	P value
LV/Liver	early	1.71±0.48	2.02±0.29	0.26
	delayed	1.78±0.48	1.93±0.30	1.00
LV/Spleen	early	1.79±1.18	2.07±0.85	0.33
	delayed	1.55±0.57	1.78±0.45	0.52
LV/Lung	early	1.43±0.48	1.70±0.18	0.33
	delayed	1.34±0.48	2.00±1.11	0.20
RV/Liver	early	2.43±0.50	2.63±0.58	0.74
	delayed	2.04±0.67	2.50±0.63	0.42
RV/Spleen	early	2.40±1.31	2.69±1.15	0.52
	delayed	1.73±0.61	2.32±0.68	0.20
RV/Lung	early	2.00±0.43	2.20±0.41	0.42
	delayed	1.68±0.80	2.51±1.24	0.26
Aorta/Liver	early	0.83±0.28	0.81±0.32	0.87
	delayed	0.88±0.30	0.83±0.31	0.87
Aorta/Spleen	early	0.83±0.49	0.79±0.40	0.52
	delayed	0.82±0.42	0.73±0.19	0.87
Aorta/Lung	early	0.67±0.16	0.67±0.22	0.87
	delayed	0.69±0.33	0.80±0.35	0.52
Liver/Spleen	early	1.05±0.66	1.05±0.46	0.63
	delayed	0.93±0.40	0.95±0.32	0.87

ROI, region of interest; LV, left ventricle; RV, right ventricle.



**Figure 3.** Comparison of the biodistribution of both radiopharmaceuticals by using c/p of ROI in different organs between early and delayed images. For this purpose, activities of early acquired ROI were subtracted from delayed ROI views of the static images.

### Discussion

Despite the advantages of planar GBPv, there are limitations, such as operator-dependent variability in determining the best septal view and underestimation of the LVEF in anterior and inferior myocardial infarction, which are overcome by the SPET mode [17, 18].

The LV and RV activity divided to bg did not differ between

the two agents, so the blood pool images with <sup>99m</sup>Tc-IgG may be adequate for clinical application.

Other <sup>99m</sup>Tc-labeled agents, such as human serum albumin (<sup>99m</sup>Tc-HSA) [10], diethylenetriamine pentaacetic-human serum albumin (DTPA-HSA) [11], and bis-diethylphosphinoethane bis-*t*-butylisocyanide (<sup>99m</sup>Tc-DEPIC) [13] have been used in GBPv acquisition [10, 11, 13]. As for these techniques, because of the rather weak binding of the radionuclide to the protein and the resulting fast extravascular diffusion [11], labeled RBC remain the radiopharmaceutical in routine practice [19].

Our work showed that <sup>99m</sup>Tc-IgG had a better washout rate from blood pools and background regions than <sup>99m</sup>Tc-RBC when used for cardiac blood-pool imaging [18]. Such an increased washout rate does not reduce effective tracer activity and the target-to-background ratios. Although we did not document the washout rate directly by obtaining sequential blood samples, the heart-to-background ratios of the two radiopharmaceuticals was an indicator for this finding.


Our findings may indicate that <sup>99m</sup>Tc-IgG is a promising agent for GBPv having a stable biodistribution and providing good image quality up to 3h post injection. Even on the delayed study, a good contrast between the LV and the surrounding organs was acquired, permitting a precise calculation of the EF value. We were unable to find a similar study in the literature. Further studies with more cases are needed to confirm these findings.

In conclusion, our results showed that the use of <sup>99m</sup>Tc-IgG in cardiac blood pool studies might be an alternative to <sup>99m</sup>Tc-RBC for the measurement of LV and EF function.

All authors declare that they have no conflicts of interest

## Bibliography

1. Tabatabaee A, Pourbehi MR, Moghaddam M et al. Comparison of influence of enoxaparin with unfractionated heparin on acute myocardial infarction with ST-segment elevation. *ISMJ* 2010; 198-205.
2. Zaret BL, Wackers FJ, Terrin ML et al. Value of radionuclide rest and exercise left ventricular ejection fraction in assessing survival of patients after thrombolytic therapy for acute myocardial infarction: results of Thrombolysis in Myocardial Infarction (TIMI) phase II study. The TIMI Study Group. *J Am Coll Cardiol* 1995; 26: 73-9.
3. Nichols KJ, Van Tosh A, Wang Y et al. Validation of gated blood-pool SPECT regional left ventricular function measurements. *J Nucl Med* 2009; 50: 53-60.
4. Picano E, Lattanzi F, Orlandini A et al. Stress echocardiography and the human factor: the importance of being expert. *J Am Coll Cardiol* 1991; 17: 666-9.
5. Canbaz F, Basoglu T, Yilmaz O et al. Comparison of gated planar <sup>99m</sup>Tc tetrofosmin scintigraphy with radionuclide ventriculography and echocardiography in the evaluation of left ventricular wall motion. *Ann Nucl Med* 2003; 17: 15-22.
6. Nichols K, DePuey EG, Krasnow N et al. Reliability of enhanced gated SPECT in assessing wall motion of severely hypoperfused myocardium: echocardiographic validation. *J Nucl Cardiol* 1998; 5: 387-94.
7. Daou D. SPECT radionuclide angiography: it is time for a consensus statement. *Eur J Nucl Med Mol Imaging* 2007; 34: 1729-34.
8. Rojas-Burke J. Health officials reacting to infection mishaps. *J Nucl Med* 1992; 33: 13N-4N, 27N.
9. Goins B, Phillips WT, Klipper R. Blood-pool imaging using technetium-99m-labeled liposomes. *J Nucl Med* 1996; 37: 1374-9.
10. Hambye AS, Verbeke KA, Vandermeiren RP et al. Comparison of modified technetium-99m albumin and technetium-99m red blood cells for equilibrium ventriculography. *J Nucl Med* 1997; 38: 1521-8.
11. Nishimura T, Hamada S, Hayashida K et al. Cardiac blood-pool scintigraphy using technetium-99m DTPA-HSA: comparison with in vivo technetium-99m RBC labeling. *J Nucl Med* 1989; 30: 1713-7.
12. Kelbaek H, Bulow K, Aldershvile J et al. A new <sup>99m</sup>Tc-red blood cell labeling procedure for cardiac blood pool imaging: clinical results. *Eur J Nucl Med* 1989; 15: 333-5.
13. de Klerk JM, van Rijk PP, van Dongen AJ et al. Can technetium 99m bisdiethylphosphinoethanebis-t butylisocyanide (<sup>99m</sup>Tc-DEPIC) be used for routine radionuclide ventriculography? *Eur J Nucl Med* 1991; 18: 317-20.
14. Hesse B, Lindhardt TB, Acampa W et al. EANM/ESC guidelines for radionuclide imaging of cardiac function. *Eur J Nucl Med Mol Imaging* 2008; 35: 851-85.
15. Callahan RJ, Froelich JW, McKusick KA et al. A modified method for the in vivo labeling of red blood cells with <sup>99m</sup>Tc: concise communication. *J Nucl Med* 1982; 23: 315-8.
16. Griffiths GL, Goldenberg DM, Jones AL, Hansen HJ. Preparation of a pure <sup>99m</sup>Tc-F(ab')<sub>2</sub> radioimmunoconjugate by direct labeling methods. *Nucl Med Biol* 1994; 21: 649-55.
17. Massardo T, Jaimovich R, Lavados H et al. Comparison of radionuclide ventriculography using SPECT and planar techniques in different cardiac conditions. *Eur J Nucl Med Mol Imaging* 2007; 34: 1735-46.
18. Harel F, Finnerty V, Ngo Q et al. SPECT versus planar gated blood pool imaging for left ventricular evaluation. *J Nucl Cardiol* 2007; 14: 544-9.
19. Srivastava SC, Straub RF. Blood cell labeling with <sup>99m</sup>Tc: progress and perspectives. *Semin Nucl Med* 1990; 20: 41-51.



Prof.B.Kokkas

The summit of mt. Olympus from an airplane, Macedonia, Greece