

Reduced grey matter metabolism due to white matter edema allows optimal assessment of brain tumors on ^{18}F -FDG-PET

**Michael Pourdehnad MD,
Sandip Basu MBBS (Hons),
DRM, DNB, MNAMS,
Paulo Duarte MD,
Aubrey S. Okpaku MD,
Babak Saboury MD,
Roland Hustinx MD,
Abass Alavi MD, PhD (Hon),
DSc (Hon)**

Division of Nuclear Medicine
University of Pennsylvania
School of Medicine
Hospital of the University
of Pennsylvania

Keywords: ^{18}F -FDG - PET
- Brain tumor
- Grey matter
- White matter - Edema

Correspondence address:

Prof. Abass Alavi MD, PhD(Hon),
DSc (Hon) 110 Donner Building
3400 Spruce Street
Philadelphia, PA 19104
Email:
abass.alavi@uphs.upenn.edu

Received:

21 June 2011

Accepted:

28 June 2011

Abstract

The main aim of this research was to demonstrate that the cortical and subcortical grey matter hypometabolism as revealed by fluorine-18 fluorodesoxyglucose-positron emission tomography (^{18}F -FDG-PET) imaging in brain tumors is related to associated edema as demonstrated by magnetic resonance imaging (MRI). This in turn enhances the ability to assess disease activity in the tumor and the degree of loss of cerebral function in the adjacent and distant structures. *We evaluated* brain T1 and T2 weighted MRI and ^{18}F -FDG-PET scans of 29 patients (19 adult, 10 pediatric) with history of brain tumor. Tumor histology types included 21 gliomas, 1 melanoma, 1 primitive neuroectodermal tumor, 3 medulloblastomas and 3 ependymomas. The majority of scans were performed within the same week (94% <1 month). The extent of hypo and hypermetabolism was assessed on the ^{18}F -FDG-PET scans. A template of 12 regions of interest (ROI) was applied and the laterality indices of the regional counts (signal intensity) were computed. Extent of edema, enhancement, and anatomical change were assessed on the MRI scans. Extent of edema in the same ROI was evaluated by a 6-point semiquantitative scale and laterality indices were generated. Metabolic activity of the grey matter was correlated with the extent of edema using these indices. *In all cases* where edema was present, significant hypometabolism was observed in the adjacent structures. Overall, there was a strong correlation between the extent of edema and severity of hypometabolism ($r=0.92$, $P=0.01$). This was true regardless of the location of edema, whether there was history of radiation treatment ($r=0.91$, $P=0.03$), or not ($r=0.97$, $P=0.17$). *In conclusion*, edema independent of underlying variables appeared to contribute significantly to cortical and sub-cortical grey matter hypometabolism observed in patients with brain tumors. This would indicate that brain tumors can be successfully assessed by ^{18}F -FDG-PET and therefore the efforts for utilizing other tracers may not be justified.

Hell J Nucl Med 2011; 14(3): 219-223

Published on line: 10 November 2011

Introduction

Studies with fluorine-18 fluorodesoxyglucose-positron emission tomography (^{18}F -FDG-PET) of patients with brain tumors frequently demonstrate areas of extensive hypometabolism in the cortex and subcortical nuclei. Frequently this is attributed to radiation or chemotherapy or other treatment related effects. In this study, we hypothesized that edema, as a consequence of breakdown in blood-brain barrier, regardless of underlying factors including therapeutic interventions, is the predominant cause of such observation. Therefore ^{18}F -FDG-PET imaging will remain an effective modality for examining and managing patients with brain tumors.

Patients and methods

Patient population

Brain magnetic resonance imaging (MRI) and ^{18}F -FDG-PET scans of 29 patients (19 adult, 10 pediatric) with history of A brain tumor were evaluated. Tumor histology types included 12 glioblastoma multiformes, 1 anaplastic astrocytoma, 3 astrocytomas not otherwise specified (NOS), 2 oligodendroglioma (1 anaplastic), 1 ganglioglioma, 2 gliomas NOS, 1 melanoma, 1 primitive neuroectodermal tumor (PNET), 3 medulloblastomas, and 3 ependymomas. Twenty-five patients (86%) had prior surgical resection. Twenty patients (69%) had prior radiation treatment. Patients' age at time of imaging ranged from 4-64 years. Mean adult age was 42 years. Mean pediatric age was 11 years.

Imaging studies

The majority of PET and MRI studies were performed within the same week (94%<1 month). FDG-PET was performed on a brain PET scanner (Head PENN PET, USA). After fasting over-

night, patients were administered 5.81MBq/kg body weight ^{18}F -FDG intravenously. Patients were then kept in a dark, quiet room lying supine for one hour. Images were acquired for 40min. Studies with ^{18}F -FDG-PET were then reconstructed with three-dimensional reconstruction algorithms.

Brain MRI was performed on a 1.5 Tesla magnet per routine clinical protocol. Sagittal spin echo T1, axial FSE T2, axial inversion recovery, axial gradient echo, 3D volumetric spoiled gradient recalled (SPGR), and post gadolinium axial images were obtained.

Uptake of ^{18}F -FDG was assessed by utilizing a template of regions of interest (ROI) which was coregistered with PET scans and manually adjusted for any anatomical distortions. The following regions were assessed: frontal lobes, temporal lobes, parietal lobes, occipital lobes, posterior cingulate gyrus, cerebellum, thalamus, and basal ganglia. Counts from ROI representing the same brain anatomic structures were summed over all the slices and divided by the number of pixels in each area. ($\Sigma \text{ROIcounts}/\Sigma \text{ROIpixels}$). Thereafter, a laterality index (LI_{PET}) of the count/pixel obtained from each region was calculated. This was done by finding the difference between right and left count/pixel in the same region and then dividing by the average of right and left count/pixel by using the formula $\text{LI}_{\text{PET}} = (\text{Right} - \text{Left} / \text{Right} + \text{Left}) \times 200\%$. The LI_{PET} was expressed as a percentage. An LI_{PET} of greater than 10% was considered significant based upon prior experience.

The extent of T2 signal abnormality, contrast enhancement, and anatomical change were assessed on the MRI scans. Particular attention was given to high T2 signal in white matter and other areas outside of tumor locations. The extent of increased T2 signal in the same white matter of the same regions above was evaluated by a 6-point semi-quantitative scale. A score of 0 was given when there was no increased T2 signal in the white matter. A score of 1 corresponded to increased T2 signal in less than 20% of the region, a score of 2 equaled 20%-40%, a score of 3 equaled 40%-60%, a score of 4 equaled 60%-80% and a score of 5 represented signal in greater than 80% of the region. Laterality indices (LI_{MRI}) were generated by comparing extent of increased T2 signal on right and left sides in the same region using the formula described above.

Data analysis

Each region was evaluated for decreased ^{18}F -FDG uptake and increased T2 signal. For each patient, brain regions in which both PET and MRI results demonstrated a significant LI were selected. The absolute value of each LI was then summed, giving each patient a total LI_{PET} and LI_{MRI} . Decreased ^{18}F -FDG uptake in the grey matter was correlated to the extent of increased T2 signal in the white matter using these total LI values. Regression analysis was performed. Regions which contained known tumor site were excluded from the ROI. Therefore, all significant LI_{PET} values represented decreased ^{18}F -FDG uptake in the grey matter and not increased uptake due to tumor activity on one side.

Results

The imaging studies were analyzed for concordance between decreased ^{18}F -FDG uptake and increased T2 signal on PET and MRI, respectively. As expected, the majority of

patients with brain tumors demonstrated both findings. Significantly decreased ^{18}F -FDG uptake ($\text{LI}_{\text{PET}} > 10\%$) in cortical or subcortical brain regions was identified in 25 of the 29 patients (86%). Of the 25 with significantly reduced ^{18}F -FDG uptake abnormalities, 22 patients (88%) had elevated T2 signal on MRI (mean $\text{LI}_{\text{PET}} = 64 \pm 47$). Three patients (12%) had no evidence of increased T2 signal (mean $\text{LI}_{\text{PET}} = 31 \pm 22$). The first patient (#1) was an 11 year old male with glioblastoma multiforme in the left frontal lobe status post resection and radiation treatment. The decreased ^{18}F -FDG uptake was noted in the left thalamus and basal ganglia and the contralateral cerebellum. The second patient (#2) was a 35 years old male with glioblastoma multiforme also in the left frontal lobe, status post resection, with the same PET findings as patient #1. The third patient (#3) was a 24 years old female with a "glioma" caudal to the thalamus extending to the pons status post resection and radiation. Severely decreased ^{18}F -FDG uptake was noted in the contralateral cerebellum.

Cortical suppression was generally more extensive than the abnormalities detected on MRI. Of the 22 patients with decreased ^{18}F -FDG uptake and high-signal T2 findings, seventeen had cortical suppression in additional areas that were remote from regions with T2 abnormalities. These remote regions were often the subcortical nuclei and the cerebellum but also included cortical regions. In five of the patients, the suppression was only limited to the region of high signal on T2-weighted images. The cortical suppression (average LI_{PET}) in remote areas was lower than in areas adjacent to T2 signal abnormalities (20% vs. 26% respectively, $P = 0.016$).

Conversely, 24 of the 29 patients (83%) demonstrated increased T2 signal on MRI. Of these 24, 22 patients (92%) had evidence of significantly decreased ^{18}F -FDG uptake by PET (mean $\text{LI}_{\text{MRI}} = 294 \pm 196$). The other 2 patients had no significant decrease in ^{18}F -FDG uptake (mean $\text{LI}_{\text{MRI}} = 89 \pm 19$). The first patient (#1) was a 14 years old male with medulloblastoma in the posterior fossa with no prior resection or radiation. The increased T2 signal was reported as active tumor extending through the white matter. The second patient (#2) was a 49 years old female with anaplastic astrocytoma in the temporal lobe with no prior resection or radiation. The increased T2 signal was reported as glioma infiltrating into the inferior temporal lobe. Both these patients had abnormally increased ^{18}F -FDG uptake corresponding to active tumor.

Only 2 of the 29 patients had neither decreased ^{18}F -FDG uptake on PET nor increased T2 signal on MRI. The first patient was a 47 years old female with a melanoma brain tumor status post right parietal craniotomy and the second patient was a 47 years old female with medulloblastoma in the left cerebellum status post resection and radiation. Both of these patients had no evidence of increased T2 signal on MRI and only had abnormal ^{18}F -FDG uptake at the site of resection.

A total of 8 patients had evidence of contralateral cerebellar diaschisis demonstrated by decreased ^{18}F -FDG uptake in cerebellar hemisphere contralateral to the tumor side. One patient had increased T2 signal in the right occipital lobe while apparently decreased ^{18}F -FDG uptake in the opposite left occipital lobe ($\text{LI}_{\text{PET}} = 30$). This was a 50 years old male with glioblastoma multiforme in the right temporal lobe status post resection and radiation. Upon

review, the patient had enhancement on MRI in the right temporal lobe with extension into the occipital lobe as well as increased T2 signal in the right temporal, parietal and occipital lobes. The unexpected lateralization of the ^{18}F -FDG uptake may have been due to increased uptake on the side ipsilateral to the T2 signal abnormality secondary to tumor spread.

In order to investigate the relationship between the extent of increased T2 signal on MRI and the severity of decreased ^{18}F -FDG uptake in the adjacent grey matter on PET, regression analysis was performed. Subcortical regions were excluded from this analysis since lesions elsewhere in the brain often caused decreased ^{18}F -FDG uptake in these structure. The results demonstrated a significant correlation between LI_{PET} and LI_{MRI} (Fig. 1 and 3) in cortical regions in those patients who had any evidence of decreased ^{18}F -FDG uptake and adjacent T2 signal in the same brain region (Pearson coefficient (R)=0.920; P=0.005). Therefore, in patients with brain tumors, the greater the extent of T2 signal seen on MRI, the greater the degree of decreased ^{18}F -FDG uptake found in the adjacent grey matter on PET.

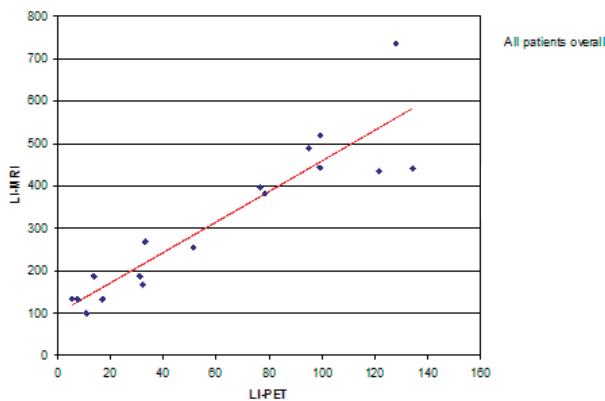


Figure 1. Correlation plot between LI_{PET} and LI_{MRI} in cortical regions in 22 patients having evidence of decreased FDG uptake and increased T2 signal in the same brain region.

Patients were divided into two subgroups according to prior radiation treatment to assess if there was any affect on the correlation of decreased ^{18}F -FDG uptake and increased T2 signal in adjacent cortical regions. Twenty patients had radiation therapy prior to the imaging studies. Of these, 16 (80%) had increased T2 signal on MRI. All of these patients demonstrated decreased ^{18}F -FDG uptake by PET. Conversely, of the four that had no abnormal T2 signal on MRI, 3 (75%) also showed decreased ^{18}F -FDG uptake. These patients were described above as having decreased ^{18}F -FDG uptake in subcortical regions only. Nine patients had no radiation treatment prior to the imaging studies. Of these, six (67%) had increased T2 signal on MRI. All of the patients with decreased ^{18}F -FDG uptake by PET had increased T2 signal. Conversely, there were two patients with abnormal T2 signal who had normal cortical and subcortical ^{18}F -FDG uptake. These were the two patients discussed above with abnormal T2 signal reported as tumor infiltration. Patients with prior radiation in our study population did not demonstrate significantly higher LI_{PET} or LI_{MRI} values. The mean LI_{PET} in patients with prior radiation was $67 \pm 52\%$ versus $50 \pm 33\%$ in those with no prior radiation (P=0.51).

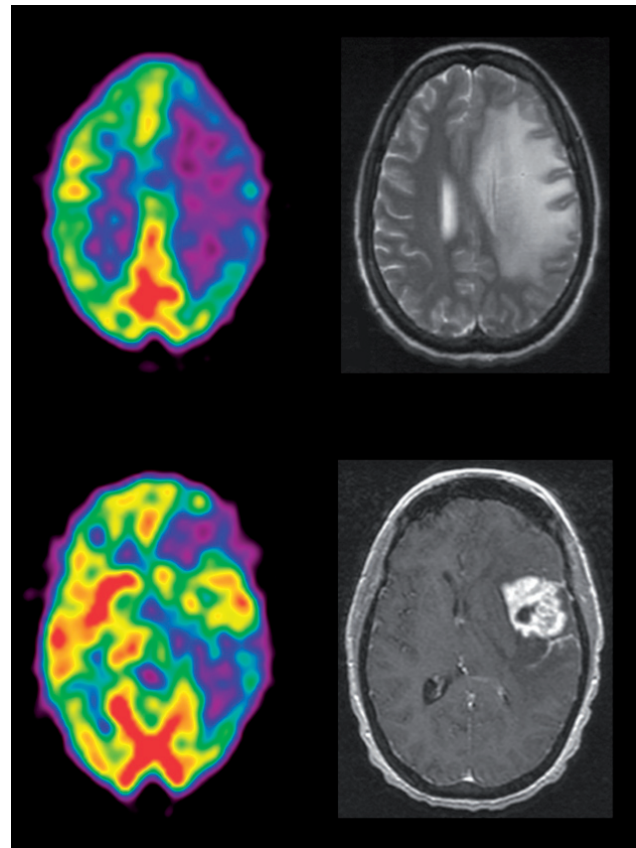


Figure 3. A patient with active tumor and extensive edema. ^{18}F -FDG-PET (left sided column) demonstrated hypermetabolism in the tumor and hypometabolism at the site of edema on the MRI images (right sided column).

The mean LI_{MRI} in patients with prior radiation was $336 \pm 196\%$ versus $284 \pm 153\%$ in those with no prior radiation (P=0.58).

Regression analysis was also performed in each subgroup to see if prior radiation had an affect on the correlation between the degree of decreased ^{18}F -FDG uptake in cortical gray matter and the extent of abnormal T2 signal in the adjacent brain regions. In both patient groups, those with and those without prior radiation treatment, high correlation was observed (R=0.91; P=0.033 and R=0.97; P=0.174) (Fig. 2 and 4).

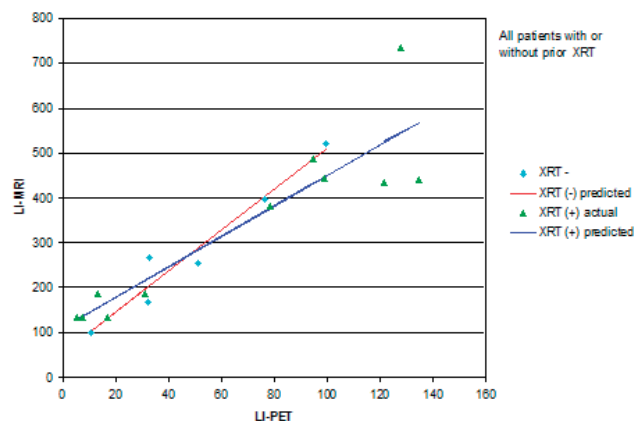


Figure 2. Comparison of correlation between the degree of decreased ^{18}F -FDG uptake in cortical gray matter and the extent of abnormal T2 signal in the adjacent brain regions in 22 patients with and without prior radiation treatment.

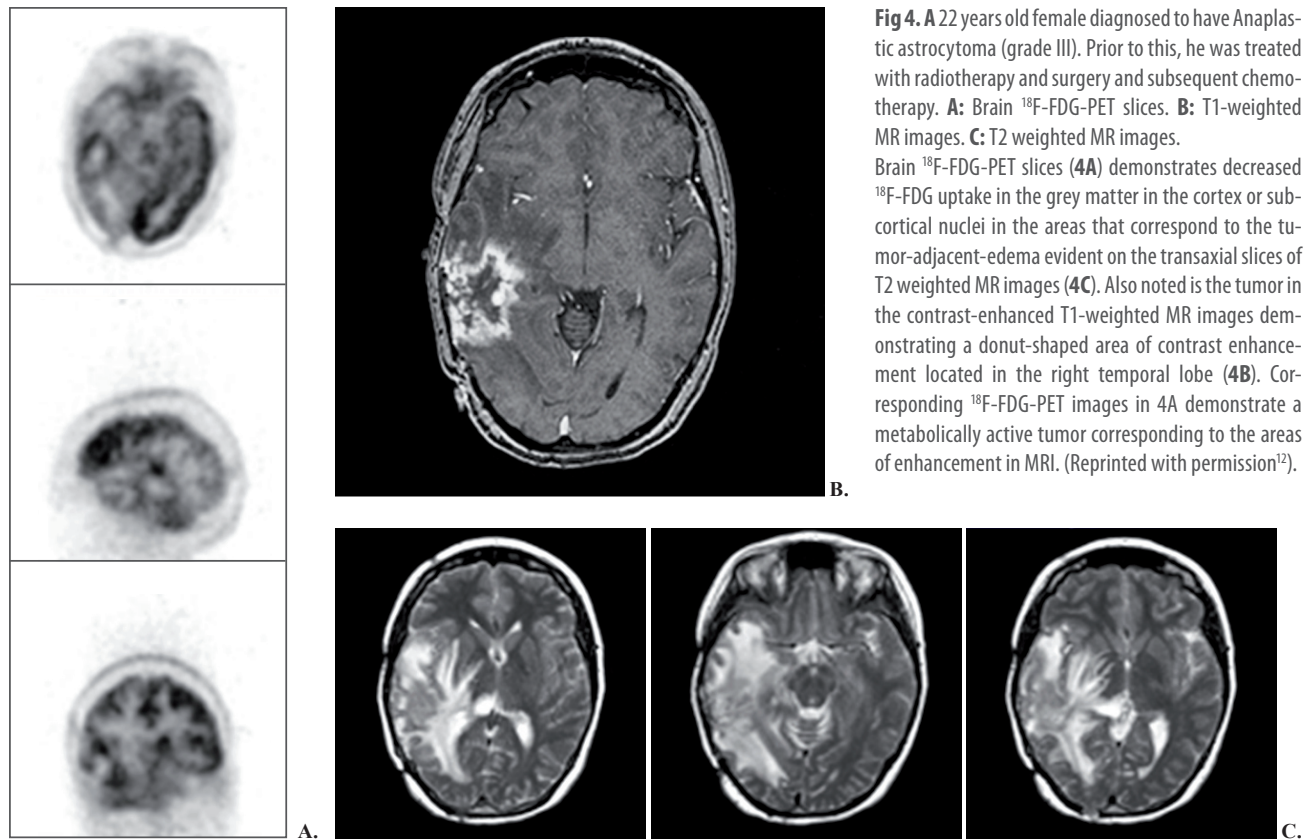


Fig 4. A 22 years old female diagnosed to have Anaplastic astrocytoma (grade III). Prior to this, he was treated with radiotherapy and surgery and subsequent chemotherapy. **A:** Brain ^{18}F -FDG-PET slices. **B:** T1-weighted MR images. **C:** T2 weighted MR images.

Brain ^{18}F -FDG-PET slices (**4A**) demonstrates decreased ^{18}F -FDG uptake in the grey matter in the cortex or subcortical nuclei in the areas that correspond to the tumor-adjacent-edema evident on the transaxial slices of T2 weighted MR images (**4C**). Also noted is the tumor in the contrast-enhanced T1-weighted MR images demonstrating a donut-shaped area of contrast enhancement located in the right temporal lobe (**4B**). Corresponding ^{18}F -FDG-PET images in **4A** demonstrate a metabolically active tumor corresponding to the areas of enhancement in MRI. (Reprinted with permission¹²).

Discussion

Peritumoral brain edema (PBE) is commonly associated with various brain tumors. Several factors have been described to produce this; however, the exact etiopathogenic mechanism has not yet been fully elucidated. It is presumed to be due to an increase of extravascular space secondary to the leakage of plasma constituents across an injured blood-brain barrier. Radiologically, the edema roughly corresponds to the hypodense area on CT and hypointense area on T1W or hyper-intense zone on T2W-MRI that surrounds the contrast-enhanced part of the tumor. Tumor volume is an important determinant of the extent of edema. In a recent study, it was suggested that aquaporin-4 (AQP-4) could be play an important role in alteration of blood-brain barrier leading to contrast enhancement and perilesional edema [1]. Expression AQP-4 was increased in brain tumors compared to normal brain but distribution and intensity of expression depend upon the type of tumor [1]. Furthermore it has been observed that in glioma-associated brain edema, AQP4 is coregulated by osmotic pressure and hypoxia, with predominance of osmotic regulation, and its expression level increased with higher glioma grades [2]. Despite the regional variations amongst the various types of tumors, the edema is vasogenic in all cases and glucocorticosteroids are presently the drugs of first choice in the treatment of vasogenic central nervous system (CNS) edema [3-5] related to the brain tumors. Edema associated with brain tumors plays a major role in determining symptoms caused by cerebral tumors. Often edema cause additional mass effect, exceeding the mass induced by the tumor itself and resulting in increased intracranial pressure. It also leads to

neurological disturbances by disrupting tissue homeostasis and reducing local blood flow [6-9]. Regional cerebral blood flow (rCBF) in peritumoral brain edema is found to be decreased because of increased interstitial pressure. Impaired blood flow might lead to local hypoxia, altered metabolism, and disturbed ion homeostasis, thus causing neurological sequelae. In one study, it was observed that rCBF in peritumoral brain edema during steroid treatment was still decreased and was in a range in which it may cause neurological sequelae [10].

Studies with ^{18}F -FDG-PET of patients with brain tumors frequently demonstrate areas of extensive hypometabolism in the cortex and subcortical nuclei [2, 11, 12]. Often these findings are attributed to radiation or chemotherapy induced injuries or other treatment related effects. We hypothesized that edema, as a consequence of breakdown in blood-brain barrier, regardless of underlying factors, is the predominant cause of such dysfunction. This was the main factor in initiating the present analysis. In the present study, we observed that independent of underlying variables, edema appears to contribute significantly to cortical and sub-cortical grey matter hypometabolism observed in patients with brain tumors. A strong correlation between the extent of edema and severity of hypometabolism was also observed in the present study. This observation would indicate a clear cut evidence for white matter edema adjacent to the grey matter sites that can be evident on structural imaging like on MR or CT images, as the cause of hypometabolism on PET images. It is imperative that these effect may be secondary to edema causing both mass effect and direct toxicity to axons, possibly blood vessel damage from radiation (particularly in areas which lack collaterals), or deafferentiation.

The findings observed in this study warrant further investigation and if validated and proven further, it would have significant impact in the interpretation of ^{18}F -FDG-PET studies in the patients with brain tumors. The implications of this hypometabolism and resulting dysfunction are significant particularly when the edema extends to the vital structures like the visual cortex where it can cause significant loss of function in the affected visual cortex [12] including homonymous hemianopsia. Therefore this effect should be taken into consideration in interpreting brain PET studies and communicating the findings with the referring physicians.

One must recognize that the presence of edema decreases cortical and subcortical grey matter uptake of ^{18}F -FDG and as such, enhances visualization of the tumor in patients with brain tumors. This phenomenon has not been appreciated and recognized by the practitioners of the field. Therefore, the need for developing new radiotracers for assessing brain tumors may not well justified. In addition, delayed imaging with ^{18}F -FDG-PET imaging is increasingly being employed for improving the sensitivity of this technique and optimal characterization of a variety of malignancies. This is also applicable to brain tumors [13], delayed imaging in brain tumors reveals significantly high contrast with time. With delayed imaging, tumor activity increases while the reverse occurs in the normal grey matter.

The results from this observation imply that ^{18}F -FDG-PET imaging will remain the study of choice in assessing patients with brain tumors. The presence of edema and delayed imaging will allow optimal visualization of the brain tumors in any location in the cerebral structures. Since there is some controversy about the underlying mechanism for the uptake of tracers other than ^{18}F -FDG, further studies are warranted to verify and validate the finding from this research.

The authors declare that they have no conflicts of interest.

Bibliography

1. Dua RK, Devi BI, Yasha TC. Increased expression of Aquaporin-4 and its correlation with contrast enhancement and perilesional edema in brain tumors. *Br J Neurosurg* 2010; 24(4): 454-9.
2. Mou K, Chen M, Mao Q et al. AQP-4 in peritumoral edematous tissue is correlated with the degree of glioma and with expression of VEGF and HIF-alpha. *J Neurooncol* 2010; 100(3): 375-83.
3. Weissman DE. Glucocorticoid treatment for brain metastases and epidural spinal cord compression: a review. *J Clin Oncol* 1988; 6(3): 543-51.
4. Koehler PJ. Use of corticosteroids in neuro-oncology. *Anticancer Drugs* 1995; 6(1): 19-33.
5. Ruderman NB, Hall TC. Use of Glucocorticoids in the Palliative Treatment of Metastatic Brain Tumors. *Cancer* 1965; 18: 298-306.
6. Reulen HJ, Huber P, Ito U, Groger U. Peritumoral brain edema. A keynote address. *Adv Neurol* 1990; 52: 307-15.
7. Hino A, Imahori Y, Tenjin H et al. Metabolic and hemodynamic aspects of peritumoral low-density areas in human brain tumor. *Neurosurgery* 1990; 26(4): 615-21.
8. Marmarou A, Takagi H, Shulman K. Biomechanics of brain edema and effects on local cerebral blood flow. *Adv Neurol* 1980; 28: 345-58.
9. Uematsu H, Maeda M, Itoh H. Peritumoral brain edema in intracranial meningiomas evaluated by dynamic perfusion-weighted MR imaging: a preliminary study. *Eur Radiol* 2003; 13(4): 758-62.
10. Behrens PF, Ostertag CB, Warnke PC. Regional cerebral blood flow in peritumoral brain edema during dexamethasone treatment: a xenon-enhanced computed tomographic study. *Neurosurgery* 1998; 43(2): 235-40; discussion 40-1.
11. Basu S, Alavi A. Molecular imaging (PET) of brain tumors. *Neuroimaging Clin N Am* 2009; 19(4): 625-46.
12. Hustinx R, Pourdehnad M, Kaschten B, Alavi A. PET imaging for differentiating recurrent brain tumor from radiation necrosis. *Radiol Clin North Am* 2005; 43(1): 35-47.
13. Spence AM, Muzi M, Mankoff DA et al. ^{18}F -FDG PET of gliomas at delayed intervals: improved distinction between tumor and normal gray matter. *J Nucl Med* 2004; 45(10): 1653-9.

