

# Currently applied cross-sectional diagnostic modalities and imaging guided interventional modalities for treatment of neuroendocrine tumors

**Vasileios D. Souftas MD, PhD, Alexandros Chatzistefanou, MD**

*Department of Radiology and Medical Imaging, Democritus University of Thrace, University Hospital of Alexandroupolis, Alexandroupolis, Greece*

Stratigou Makrygianni 1-Kikonon, 681 00, Alexandroupolis, Greece, Tel: +306944863219, +302551076540, Fax- +302551030313, Email: vsouftas@med.duth.gr

*Hell J Nucl Med 2011; 14(3): 213-218*

*Published on line: 10 November 2011*

## Abstract

Technological advances in conventional cross-sectional diagnostic imaging have allowed important modalities like ultrasonography, endoscopic ultrasonography, multi-detector computed tomography, nuclear medicine single photon emission tomography, positron emission tomography and magnetic resonance imaging to exhibit an increasingly important role in the diagnosis and management of patients with neuroendocrine tumors (NET). The arterial supply of metastatic lesions provides promising treatment options through the arterial route, hence transcatheter arterial embolization has a key role in the therapeutic management of metastatic NET. The various transcatheter methods of NET treatment are discussed, including radio-embolization. Imaging-guided percutaneous interventional radiologic methods of ablation are also discussed as applicable for the effective management of primary and metastatic NET. An approach to represent the physical and technical principles on which ablative methods rely and their clinical significance has been attempted.

## Introduction

Neuroendocrine tumors (NET) are rare tumors arising from a putative common precursor, the amine precursor uptake and decarboxylation (APUD) cell. These cells are believed to have common embryological origin from the ectodermal ridge and spread throughout the body to form a network with common structural and functional features [1, 2]. Neuroendocrine tumors also include chromaffin cells, which develop from neural crest cells and are histologically closely related to melanoma, pheochromocytoma and medullary carcinoma of the thyroid [2, 3]. All NET exhibit the potential to synthesize and secrete hormones. Functioning tumors are those in which hormone secretion by the tumor results in a clinical syndrome, thus presenting relatively early and may be a challenge for the practitioner to localize them as they are usually small. Non-functioning tumors are those in which either there is no hormone secretion or hormone secretion results in a non recognizable clinical syndrome and generally go unrecognized presenting much later mass effects [1-4]. The NET can be divided into pancreatic endocrine tumors and carcinoid tumors [2, 3]. The malignant potential of NET varies. Malignancy is more common in

some types, such as gastrinoma, whereas in others, such as insulinoma, malignancy is rare. Clinical behavior is often difficult to predict [2]. In some cases, the tumors are associated with genetic disorders such as the multiple endocrine neoplasia type 1 (MEN 1) and type II (MEN 2), von Hippel–Lindau and neurofibromatosis type 1 syndromes [3, 5, 6]. Patients with neuroendocrine carcinomas have an increased risk of developing synchronous and metachronous non-endocrine malignancies while the familial risk for patients with NET is also increased [3].

We shall focus on the role of cross-sectional imaging methods in the depiction of primary NET or of their metastatic spread in the liver and other organs and on the capabilities of imaging modalities regarding the treatment of their metastatic disease.

## Diagnostic modalities

Currently used diagnostic imaging modalities for NET detection mainly include radionuclide studies such as nuclear medicine single photon emission tomography and positron emission tomography (PET), as well as non-radionuclide imaging methods, namely ultrasonography (US), endoscopic ultrasonography (EUS), multi-detector computed tomography (MDCT), and magnetic resonance imaging (MRI). Fusion imaging techniques (PET/MDCT, PET/MRI) are also selectively used.

Functional imaging of NET became possible with the development of somatostatin receptor scintigraphy (SRS) imaging using indium-111 (<sup>111</sup>In)-octreotide, which when combined with anatomical imaging provides enhanced detection. The low spatial resolution of SRS is a major limit for an accurate identification of NET [7, 8]. A major improvement has been achieved by combining receptor and PET imaging through the use of gallium-68 (<sup>68</sup>Ga-1,4,7,10-tetraazacyclododecane-1,4,7,10-tetraacetic acid-<sup>68</sup>Ga-DOTA) complexes that have a much better sensitivity than other imaging modalities [9]. Gallium-68 is available from an in-house germanium generator and has been utilized for labelling somatostatin analogues for PET imaging of NET with promising results, especially when combined with computed tomography (CT) imaging. Positron emission tomography using fluorine-18-fluoro-deoxy-glucose (<sup>18</sup>F-FDG) is a powerful functional modality for oncological imaging. Unfortunately, <sup>18</sup>F-FDG is not

accumulated in NET except in the case of dedifferentiated tumors and tumors with high proliferative activity [10]. Based on the concept of APUD cells, the <sup>18</sup>F- and carbon-11 (<sup>11</sup>C)-labelled amine precursors, L-dihydroxyphenylalanine and 5-hydroxy-L-tryptophan (5-HTP) have also been utilized for PET imaging of NET [10, 11]. Carbon-11 is a cyclotron product with a half life of 20min, which essentially constitutes a significant drawback. In comparative studies of patients with a variety of NET, <sup>11</sup>C-5-HTP-PET was better than CT and SRS by visualizing additional small lesions. With oral premedication with carbidopa tumor uptake by <sup>11</sup>C-5-hydroxytryptophan (<sup>11</sup>C-5-HTP)-PET examination could be increased and the urinary radioactivity concentration considerably reduced. This concept may also be applied to 3,4-dihydroxy-6-<sup>18</sup>F-fluoro-L-phenylalanine (<sup>18</sup>F-L-DOPA)-PET, a method which in a limited number of studies has gained additional diagnostic information in NET patients compared to SRS and morphological imaging. Iodine-131 metaiodobenzyl guanidine (<sup>131</sup>I-MIBG) is also a valuable functional method for imaging and treatment of NET [11-13]. Fusion imaging techniques, such as PET/CT provide very good anatomic detection but may have limited availability as well as the high cost of use.

Ultrasonography of modern applied technology with the use of intravenous (i.v.) contrast agents with micro-bubbles, as well as EUS provide very good spatial resolution and information regarding tumor vasculature and lesions in parenchymal organs such as pancreas prior to surgical treatment [10]. Spiral CT with multiple rows of detectors (MDCT), MRI, with the use of various i.v. "contrast agents", as well as newer imaging techniques diffusion-weighted-MRI (DW-MRI) or functional (fMRI) provide unique possibilities regarding diagnosis, precise assessment of disease quantification and treatment response [2, 10, 14-17].

Diffusion weighted imaging (DWI) explores the random movement of water molecules in the body and can be exploited in clinical practice to provide indirect assessments of tissue properties such as cellularity, gland formation, perfusion, and cell death. In highly vascular tumors, intravascular water diffusion will account for a significant proportion of the DW signal and the opposite. By performing DWI, quantitative analysis is possible with the calculation of the apparent diffusion coefficient (ADC). Values of ADC are inversely related with tumor cellularity and reductions in ADC correlate with response to cytotoxic treatment [15, 17].

Angiography and portal/hepatic veins sampling for hormone gradients have been widely used in patients with functioning NET [18-21]. In recent years, with the advancement in functional tumor localization imaging techniques, the use of these invasive techniques has declined [22]. Higher levels of sensitivity in the detection of non functioning NET are achieved when multiple imaging methods are combined [2, 10].

### Trans-catheter intra-arterial treatment

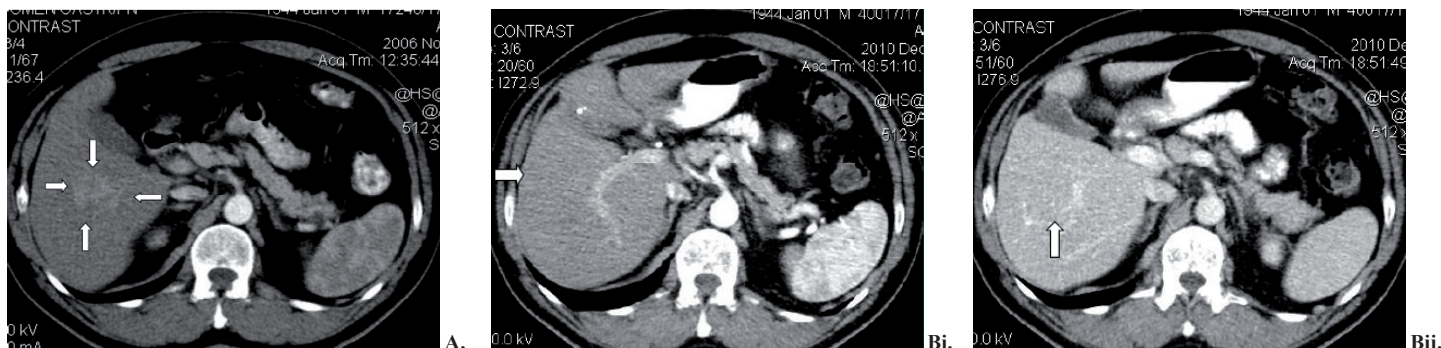
Neuroendocrine tumors are slowly growing neoplasms and 75% (25%-90%) of patients present with hepatic metastases at the time of diagnosis. Size and growth of liver metastases are considered as having a prognostic value [23-25]. Surgical resection is considered the first-line treatment for patients with hepatic metastases of NET. Due to the diffuse pattern of distribution of hepatic metastases

however, resection for cure is possible in only 10% of these patients at the time of diagnosis [26, 27]. Therefore, a large portion of patients are candidates for palliation. Although medical palliative treatments have been effective in controlling hormonal symptoms they have not been always sufficient in controlling tumor growth [28]. Moreover, the rate and median duration of objective response to systemic chemotherapy has been disappointing, and the survival rate does not substantially increase. These disappointing results are even more profound in patients with hepatic metastases of midgut origin. Hormonal treatment in combination with cytoreductive surgery, have been used as a first- or second-line option. Neuroendocrine tumors frequently produce multiple growth factors including vascular endothelial growth factor, platelet-derived growth factor, insulin-like growth factor, basic fibroblast growth factor, and transforming growth factor, as well as expressing receptors for these and other growth factors such as epidermal growth factor receptor. A number of novel treatments are now focused directed on these growth factors or their receptors in NET, including a monoclonal antibody to vascular endothelial growth factor (bevacizumab) as well as small-molecule inhibitors of the intracellular tyrosine kinase domain of vascular endothelial growth factor receptor or other growth factor receptors [28, 30-32].

The arterial supply of metastatic lesions provides promising treatment options through the arterial route. There are various interventional radiologic palliative options in the management of metastatic NET and among them, transcatheter hepatic arterial embolization (TACE) methods are effective in controlling hormonal symptoms and tumor growth. Transcatheter hepatic artery embolization using particles of varying size, a chemotherapeutic agent or using multiple agents and particles as well as radio-embolization by using radioactive microspheres labeled with yttrium-90 (<sup>90</sup>Y) or lutetium-177 (<sup>177</sup>Lu) are used in the management of metastatic or primary hepatic NET [33-47].

"Bland" TACE with particles alone are used for ischemic cell death and "terminal vessel blockade" in order to maximize tumor ischemia and necrosis while preserving normal hepatic parenchyma. The effect of profound ischemia is instantaneous and imaging findings of tumor necrosis are seen within 24h. Contrast media if injected are retained within the embolized tumor, and "gas bubbles" may be seen within days and may persist for weeks. Necrosis and liquefaction of the tumor following TACE exhibit low density and lack of enhancement following contrast administration and are indicative of response to treatment. Treated tumors slowly decrease in size, and may eventually disappear [33-36].

Traditionally TACE has been performed by injecting an emulsion of one or more chemotherapeutic agents dissolved in water mixed with lipiodol either in combination with an embolic agent, or followed by an embolic agent. This technique has rather unconvincing results [37-41]. The use of particles binding with the chemotherapeutic agent, DC beads (Biocompatibles, Surrey, UK), HepaSphere (Biosphere Medical, Roissy CDG Cedex, France) comprises biocompatible, non-resorbable hydrogel beads capable of being loaded with anthracyclin derivatives such as doxorubicin and results in higher tumor concentrations and lower systemic concentrations of doxorubicin or other chemotherapeutic agents such as irinotecan as compared to intra-arterial injected doxorubicin [42-45].



**Figure 1 (A, B):** A 67 years old man with primary hepatic neuroendocrine carcinoma, histologically confirmed. **A.** Axial CT image, arterial phase, before TACE and percutaneous RFA. **Bi, ii.** Follow-up 4 years later with no evidence of relapse.

The TACE technique may combine the effects of interstitial high dose radiotherapy and arterial micro-embolization (targeted radiotherapy) by using <sup>90</sup>Y or <sup>177</sup>Lu to treat patients with non-resectable NET liver metastatic disease, with encouraging results. Yttrium-90 as a pure beta rays emitter with an average range of tissue penetration of 5mm is used. The standard dose administered is 2GBq in 50X10<sup>6</sup> in the form of resin microspheres. Lutetium-177 is alternatively used as another beta rays emitter radionuclide. [41, 46, 47].

Hepatic NET metastases respond to almost any embolization method [33-38]. The experience of our department is in conform with this statement (Fig. 1A, Bi, Bii). Small patient groups, variable chemoembolization methods, the presence of crossover and suboptimal “bland” embolization technique however, conspire to rather uncertain results. Others sum up that TACE is “the definitive treatment of patients with symptomatic NET metastases” [40]. There is currently no strong evidence to support the use of one method of embolization over another. “Bland” embolization techniques may be effective in “avascular” hepatic metastases [36].

### Imaging guided percutaneous ablation

Surgical resection is the gold standard for treatment of NET but only 10%-20% of patients with metastases are actually candidates for resection due to the extent of the disease. Most of those who undergo resection will recur with a median recurrence time of 21 months. The 5 and 10 years recurrence rates are 84% and 94%, respectively [48, 49]. A major surgical resection may stimulate liver regeneration and local growth factors thus, ablative methods may be preferable, provided they effectively treat a small even deeply localized tumor. Ablative techniques, are associated with less morbidity compared to surgical resection and can be used repeatedly with greater ease in order to treat a recurrence. The treatment of liver metastases is important both for control of symptoms and to slow disease progression, despite little chance of cure [50-55]. Because of this natural course of metastatic NET, interventional radiologic imaging guided, percutaneous ablation exhibits some potential advantages over resection. In cases that the majority of patients are expected to recur, it makes intuitive sense to treat them with the least morbid and least invasive option without compromising their oncologic outcome. Ablative techniques may be applied by the guidance of US, EUS, CT, MRI or by fusion imaging systems like PET/CT [54, 56-61].

Navigation system technologies facilitate the eradication of the lesions in combination with the ablative methods, and provide a safe approach of neoplasms hardly accessible through percutaneous methods. Some of the methods enrolled, deliver energy or chemicals in order to ablate the tumor-lesions as described below.

Heating thermal ablation is a growing technique that results in coagulation and necrosis of tissues. Mammalian tissues are very sensitive to temperature changes. At 55°C, for example, tissue death results within 2sec, at 45°C within 15min, at 50°C within 20sec, and at 100°C within less than 1sec. Therefore, it is clear that at 100°C cell death is instantaneous. However, very high temperatures are not preferred because the charred tissue will prevent the spread of thermal energy away from the active electrode or antenna. Therefore, a gradual elevation of energy deposition is suggested [54, 56].

A number of reviews during the past decade promoted radiofrequency ablation (RFA) as the gold standard of thermal tumor destruction, [49-55, 57-61]. The patient treated is actually part of the RFA circuit, thus tissue conductivity is important in achieving an adequate ablation zone. The RFA electrode acts as the cathode of an electrical circuit, which is closed by the application of dispersing pads on the patient’s thighs. However, the RF electrode itself is not the source of heat. It sets adjacent molecules into motion, by generating an alternating electromagnetic (EM) field. The dipole molecules, mostly water, immediately next to the RF electrode tip attempt to remain aligned in the direction of the current and are forced to vibrate as rapidly as alternating current is applied. Molecules that are further away from the electrode are set into motion by other vibrating molecules near them. The frictional energy losses between adjacent molecules result in local energy deposition and temperature increase. The molecules adjacent to the electrode are the source of heat, which is transmitted further by tissue conductivity. Better outcomes are associated with a gradual elevation of energy deposition. The objective is to heat tissues between 50°-100°C for 4-6min without causing charring or vaporization. When the target lesion abuts a blood vessel of 3mm or larger, the effects of RFA are minimized because the flowing blood prevents large temperature variations in the part of the tumor near the lesion, thereby keeping the tissue “cooler”. The goal of RFA technique is also to ablate a zone of healthy tissue analogous to a “surgical margin” around the target tumor, with a diameter of 0.5-1.0cm. The main concern however is based on the difficulty in truly identifying

exact tumor margins and the not so uncommon scenario of microscopic tumor extension beyond those confines. For a 2cm tumor, one would need to produce an ablation of approximately 3-4cm [59].

Percutaneous RFA techniques are more effective when metastatic lesions are small, scant in number, combined with percutaneous arterial embolization or chemoembolization, or if they are combined with per os chemotherapeutic agents administered at 24h or 48h [59, 62, 63]. Response rates from 80%–95% are reported for liver metastases of gastrointestinal endocrine tumors and responses have lasted up to three years [50-53]. Although RFA has not been shown to extend life, its ability to control local metastases with low morbidity has led to its increasing use for the treatment of limited small NET metastases [50, 52].

Microwave ablation (MWA) refers to the use of all electromagnetic (EM) methods for inducing tumor destruction by using devices with frequencies of at least 900MHz. The tumor is localized with imaging guided techniques and a thin (14.5-gauge/17-gauge) MW antenna is placed directly into the lesion. A MW generator emits an EM wave through the exposed, non-insulated portion of the antenna. Cellular death via coagulation necrosis is induced, by means of EM MW that agitate water molecules in the surrounding tissue, producing friction and heat. Microwave ablation offers many of the benefits of RFA but has several other theoretical advantages that may increase its effectiveness in the treatment of tumors such as consistently higher intra-tumoral temperatures, larger tumor ablation volumes, faster ablation times, ability to use multiple applicators, improved convection profile, optimal heating of cystic masses, and less procedural pain. In addition, MWA does not require the placement of grounding pads. Microwave ablation has a promising outcome in the treatment of primary and secondary liver disease, primary and secondary lung malignancies, renal and adrenal tumors, and bone metastases [54, 64].

Cryoablation induces intracellular and extracellular ice crystals that result in rupture of cell membrane, and osmotic cell dehydration. Cryoablation induces also occlusion of small blood vessels, resulting in cell hypoxia and complete homogenous necrosis of tissue reaching -19.4°C or lower. The method uses argon gas for freezing at -190°C and helium for thawing (35°C) by using 17-gauge probes, coaxial in design. A thin inner tube carries the gas to the tip where it expands and cools by the Joule-Thompson effect [53, 57, 65]. There is little experience related to this technique.

Electroporation is an upcoming technique that increases cell membrane permeability by changing the trans-membrane potential and subsequently disrupting the lipid bilayer integrity to allow transportation of molecules across the cell membrane via nano-size pores called "irreversible electroporation" (IRE). Application of very high voltage electrical pulses induces irreversible disruption of cell membrane integrity resulting in cell death without the need for additional injury. It creates a sharp boundary between the treated and untreated area in vivo, suggesting that IRE has the ability to sharply delineate the treated area from the non-treated, and that treatment planning can be precisely performed according to mathematical calculations. As opposed to thermal techniques, IRE is very effective in creating tissue death in micro-to millisecond ranges of treatment time. Thermal techniques usually require at least 20min to hours. There appears to be complete ablation to the margin of blood vessels

without compromising the functionality of the blood vessels. Preclinical investigations have shown that IRE can be an effective strategy for targeted ablation of solid tumors, and have prompted its clinical evaluation [66, 67].

*In conclusion*, technological advances, especially PET/CT and MRI, have allowed in cross sectional diagnostic imaging methods to exhibit an increasingly important role in the management of patients with NET. Interventional palliative options in the treatment of metastatic NET and among them transcatheter hepatic arterial embolization and imaging-guided percutaneous ablation methods have been shown to be effective in controlling hormonal symptoms and tumor growth.

*The authors declare that they have no conflicts of interest.*

### Bibliography

1. Modlin IM, Oberg K, Chung DC et al. Gastroenteropancreatic neuroendocrine tumours. *Lancet Oncol* 2008; 9: 61-72.
2. Reznik RH. CT/MRI of neuroendocrine tumours. *Cancer Imaging* 2006; 6: S163-S177.
3. Arnold R. Endocrine tumours of the gastrointestinal tract: Introduction: definition, historical aspects, classification, staging, prognosis and therapeutic options. *Best Pract Res Clin Endocrinol Metab* 2005; 19: 491-505.
4. Kaltsas G, Androulakis IJ, de Herder WW, Grossman AB. Paraneoplastic syndromes secondary to neuroendocrine tumours. *Endocr Relat Cancer* 2010; 17: R173-R193.
5. Marx SJ, Agarwal SK, Heppner C et al. The gene for multiple endocrine neoplasia type 1: recent findings. *Bone* 1999; 25: 119-22.
6. Koch CA. Molecular pathogenesis of MEN2-associated tumors. *Fam Cancer* 2005; 4: 3-7.
7. Montravers F, Grahek D, Kerrou K et al. Can fluorodihydroxyphenylalanine PET replace somatostatin receptor scintigraphy in patients with digestive endocrine tumors? *J Nucl Med* 2006; 47: 1455-62.
8. Gerasimou G, Moravidis E, Gotzamani-Psarrakou A. Somatostatin receptor imaging with <sup>111</sup>In-pentetreotide in gastro-intestinal tract and lung neuroendocrine tumors-Impact on targeted treatment. *Hell J Nucl Med* 2010; 13: 158-62.
9. Buchmann I, Henze M, Engelbrecht S et al. Comparison of <sup>68</sup>Ga-DOTATOC PET and <sup>111</sup>In-DTPAOC (Octreoscan) SPECT in patients with neuroendocrine tumours. *Eur J Nucl Med Mol Imaging* 2007; 34: 1617-26.
10. Rockall AG, Reznik RH. Imaging of neuroendocrine tumours (CT/MR/US). *Best Pract Res Clin Endocrinol Metab* 2007; 21: 43-68.
11. Sundin A, Garske U, Orlefors H. Nuclear imaging of neuroendocrine tumours. *Best Pract Res Clin Endocrinol Metab* 2007; 21: 69-85.
12. Lapińska G, Bryszewska M, Fijołek-Warszewska A et al. The diagnostic role of <sup>68</sup>Ga-DOTATATE PET/CT in the detection of neuroendocrine tumours. *Nucl Med Rev Cent East Eur* 2011; 14: 16-20.
13. Oommen R, Shanthly N, Subramani N et al. In-house preparation of iodine -131 metaiodo benzyl guanidine for scintigraphy of neuroendocrine tumors. Fourteen years experience in South India. *Hell J Nucl Med* 2007; 10: 164-6.
14. Liapi E, Geschwind J-F, Vossen JA et al. Functional MRI evaluation of tumor response in patients with neuroendocrine hepatic metastasis treated with transcatheter arterial chemoembolization. *AJR* 2008; 190: 67-73.

15. Koh D-M, Collins Dj. Diffusion-Weighted MRI in the body: applications and challenges in oncology. *AJR* 2007; 188: 1622-35.
16. Kamel IR, Bluemke DA, Eng J et al. The role of functional MR imaging in the assessment of tumor response after chemoembolization in patients with hepatocellular carcinoma. *J Vasc Interv Radiol* 2006; 17: 505-12.
17. Taouli B, Koh D-M. Diffusion-weighted MR imaging of the liver. *Radiology* 2010; 254: 47-66.
18. Miller DL, Doppman JL, Metz DC et al. Zollinger-Ellison syndrome: technique, results and complications of portal venous sampling. *Radiology* 1992; 182: 235-41.
19. Thom AK, Norton JA, Doppman JL et al. Prospective study of the use of intraarterial secretin injection and portal venous sampling to localize duodenal gastrinomas. *Surgery* 1992; 112: 1002-8.
20. Doppman JL, Miller DL, Chang R et al. Gastrinomas: localization by means of selective intraarterial injection of secretin. *Radiology* 1990; 174: 25-9.
21. Lo CY Chan FL, Tam SC et al. Value of intra-arterial calcium stimulated venous sampling for regionalization of pancreatic insulinomas. *Surgery* 2000; 128: 903-9.
22. Metz C, Jensen RT. Gastrointestinal neuroendocrine tumors: pancreatic endocrine tumors. *Gastroenterology* 2008; 135: 1469-92.
23. Libicher M, Bovenschulte H. Arterielle Embolisierung von Lebermetastasen neuroendokriner Tumoren. *Radiologe* 2009; 49: 233-41.
24. Barakat MT, Meeran K, Bloom SR. Neuroendocrine tumours. *Endocr Relat Cancer* 2004; 11: 1-18.
25. Norton JA. Endocrine tumours of the gastrointestinal tract: surgical treatment of neuroendocrine metastases. *Best Pract Res Clin Gastroenterol* 2005; 19: 577-83.
26. Tomassetti P, Campana D, Piscitelli L et al. Endocrine pancreatic tumors: factors correlated with survival. *Ann Oncol* 2005; 16: 1806-10.
27. Chamberlain RS, Canes D, Brown KT et al. Hepatic neuroendocrine metastases: does intervention alter outcomes? *J Am Coll Surg* 2000; 190: 432-45.
28. Strosberg JR, Kvols LK. A review of the current clinical trials for gastroenteropancreatic neuroendocrine tumours. *Expert Opin Investig Drugs* 2007; 16: 219-24.
29. McEntee GP, Nagorney DM, Kvols LK et al. Cytoreductive hepatic surgery for neuroendocrine tumors. *Surgery* 1990; 108: 1091-6.
30. Oberg K, Kvols L, Caplin M et al. Consensus report on the use of somatostatin analogs for the management of neuroendocrine tumors of the gastroenteropancreatic system. *Ann Oncol* 2004; 15: 966-73.
31. Yao JC. Molecular targeted therapy for carcinoid and islet-cell carcinoma. *Best Pract Res Clin Endocrinol Metab* 2007; 21: 163-72.
32. Shah T, Caplin M. Biotherapy for metastatic endocrine tumours. *Best Pract Res Clin Gastroenterol* 2005; 19: 617-36.
33. Gupta S, Yao JC, Ahrar K et al. Hepatic artery embolization and chemoembolization for treatment of patients with metastatic carcinoid tumors: the MD Anderson experience. *Cancer J* 2003; 9: 261-7.
34. Gupta S, Johnson MM, Murthy R et al. Hepatic arterial embolization and chemoembolization for the treatment of patients with metastatic neuroendocrine tumors: variables affecting response rates and survival. *Cancer* 2005; 104: 1590-602.
35. Eriksson BK, Larsson EG, Skogseid BM et al. Liver embolizations of patients with malignant neuroendocrine gastrointestinal tumors. *Cancer* 1998; 83: 2293-301.
36. Brown KT, Koh BY, Brody LA et al. Particle embolization of hepatic neuroendocrine metastases for control of pain and hormonal symptoms. *J Vasc Interv Radiol* 1999; 10: 397-403.
37. Gupta S, Johnson MM, Ahrar K et al. Hepatic arterial embolization & chemoembolization for the treatment of patients with metastatic neuroendocrine tumor. *Cancer* 2005; 104: 1590-602.
38. Roche A, Girish B, de Baère T et al. Trans-catheter arterial chemoembolization as first-line treatment for hepatic metastases from endocrine tumors. *Eur Radiol* 2003; 13: 136-40.
39. Ruutaiainen AT, Soulen MC, Tuite CM et al. Chemoembolization & bland embolization of neuroendocrine tumor metastases to the liver. *J Vasc Interv Radiol* 2007; 18: 847-55.
40. Ho AS, Picus J, Darcy MD et al. Long-Term outcome after chemoembolization & embolization of hepatic metastatic lesions from neuroendocrine tumor. *AJR* 2007; 188: 1201-7.
41. Strosberg JR, Cheema A, Kvols LK. A review of systemic and liver-directed therapies for metastatic neuroendocrine tumors of the gastroenteropancreatic tract. *Cancer Control* 2011; 18: 127-37.
42. Malagari K, Pomoni M, Spyridopoulos TN et al. Safety profile of sequential transcatheter chemoembolization with DC Bead™: results of 237 hepatocellular carcinoma (HCC) patients. *Cardiovasc Intervent Radiol* 2011; 34: 774-85.
43. Lammer J, Malagari K, Vogl T et al. Prospective randomized study of doxorubicin-eluting-bead embolization in the treatment of hepatocellular carcinoma: results of the PRECISION V study. *Cardiovasc Intervent Radiol* 2010; 33: 41-52.
44. De Baere T, Deschamps F, Teriitheau C et al. Transarterial chemoembolization of liver metastases from well differentiated gastroenteropancreatic endocrine tumors with doxorubicin-eluting beads: Preliminary results. *J Vasc Interv Radiol* 2008; 19: 855-61.
45. Fiorentini G, Alberti C, Del Conte A et al. Intra-arterial hepatic chemoembolization (TACE) of liver metastases from ocular melanoma with slow-release irinotecan-eluting beads. Early results of phase II clinical study. *In vivo* 2009; 23: 131-8.
46. Hoffmann RT, Paprottka P, Jakobs TF et al. Arterial therapies of non-colorectal cancer metastases to the liver (from chemoembolization to radioembolization). *Abdom Imaging* 2011 [Epub ahead of print]
47. King J, Quinn R, Glenn DM et al. Radioembolization with selective internal radiation microspheres for neuroendocrine liver metastases. *Cancer* 2008; 113: 921-9.
48. Ng KK, Poon RT. Radiofrequency ablation for malignant liver tumor. *Surg Oncol* 2005; 14: 41-52.
49. Goldberg SN, Solbiati L, Hahn PF et al. Large-volume tissue ablation with radio frequency by using a clustered, internally cooled electrode technique: laboratory and clinical experience in liver metastases. *Radiology* 1998; 209: 371-9.
50. O'Toole D, Ruzsiewicz P. Chemoembolization and other ablative therapies for liver metastases of gastrointestinal endocrine tumours. *Best Pract Res Clin Gastroenterol* 2005; 19: 585-94.
51. Gillams A, Cassoni A, Conway G et al. Radiofrequency ablation of neuroendocrine liver metastases: the Middlesex experience. *Abdom Imaging* 2005; 30: 435-41.
52. Elvin A, Skogseid B, Hellman P. Radiofrequency ablation of neuroendocrine liver metastases. *Abdom Imaging* 2005; 30: 427-34.
53. Gurusamy KS, Pamecha V, Sharma D, Davidson BR. Palliative cytoreductive surgery versus other palliative treatments in patients with unresectable liver metastases from gastro-enteropancreatic neuroendocrine tumours. *Cochrane Database Syst Rev* 2009; (1): CD007118.

54. Flanders VL, Gervais DA. Ablation of liver metastases: current status. *J Vasc Interv Radiol* 2010; 21: S214-S22.
55. Goldberg SN, Stein MC, Gazelle GS et al. Percutaneous radiofrequency tissue ablation: optimization of pulsed-radiofrequency technique to increase coagulation necrosis. *J Vasc Interv Radiol* 1999; 10: 907-16.
56. Goldberg SN, Gazelle GS, Mueller PR. Thermal ablation therapy for focal malignancy: a unified approach to underlying principles, techniques, and diagnostic imaging guidance. *AJR Am J Roentgenol* 2000; 174: 323-31.
57. Seo DW. EUS-Guided Antitumor Therapy for Pancreatic Tumors. *Gut Liver* 2010; 4: S76-S81.
58. Schmidt D, Trubenbach J, Brieger J et al. Automated saline-enhanced radiofrequency thermal ablation: initial results in ex vivo bovine livers. *AJR Am J Roentgenol* 2003; 180: 163-5.
59. Hong K, Georgiades C. Radiofrequency ablation: mechanism of action and devices. *J Vasc Interv Radiol* 2010; 21: S179-S86.
60. Moug SJ, Leen E, Horgan PG et al. Radiofrequency ablation has a valuable therapeutic role in metastatic VIPoma. *Pancreatol* 2006; 6: 155-9.
61. Venkatesan AM, Kadoury S, Abi-Jaoudeh N et al. Real-time FDG PET guidance during biopsies and radiofrequency ablation using multimodality fusion with electromagnetic navigation. *Radiology* 2011; 260: 848-56.
62. Ahmed M, Lukyanov AN, Torchilin V et al. Combined radiofrequency ablation and adjuvant liposomal chemotherapy: effect of chemotherapeutic agent, nanoparticle size, and circulation time. *J Vasc Interv Radiol* 2005; 16: 1365-71.
63. Ahmed M, Liu Z, Lukyanov AN et al. Combination radiofrequency ablation with intra tumoral liposomal doxorubicin: effect on drug accumulation and coagulation in multiple tissues and tumor types in animals. *Radiology* 2005; 235: 469-77.
64. Lubner MG, Brace CL, Hinshaw JL, Lee FT Jr. Microwave tumor ablation: mechanism of action, clinical results, and devices. *J Vasc Interv Radiol* 2010; 21: S192-S203.
65. Erinjeri JP, Clark TWI. Cryoablation: Mechanism of Action and Devices. *J Vasc Interv Radiol* 2010; 21: S187-S91.
66. Lencioni R. Loco-regional treatment of hepatocellular carcinoma. *Hepatology* 2010; 52: 762-73.
67. Lee EW, Thai S, Kee ST. Irreversible electroporation: a novel image-guided cancer therapy. *Gut Liver* 2010; 4: S99-S104. 