

Chondroid hamartoma presenting as solitary pulmonary nodule: Results of dual time point ^{18}F -fluorodeoxyglucose-PET and comparison with ^{18}F -fluorothymidine PET and histopathology

To the Editor: The dual time point fluorine 18-fluorodeoxyglucose-positron emission tomography (^{18}F -FDG-PET) characteristics of chondroid hamartoma presenting as solitary pulmonary nodule is described in this report. Hamartoma derives from the Greek word hamartia: sin. A 45 years old female was referred for ^{18}F -FDG-PET study in whom contrast enhanced computed tomography (CT) scan of thorax demonstrated a well defined soft tissue density mass in the anterior segment of left upper lobe of 4x3cm that showed contrast enhancement (Fig 1). There was no evidence of calcification and/or necrosis in the lesion. A suspicion of malignancy was raised in the CT report in view of small increase in diameter of the lesion on CT compared to a previous one. The whole body ^{18}F -FDG-PET (Fig. 2a and b) showed mild tracer uptake at baseline ^{18}F -FDG-PET and standardized uptake value maximum or SUVmax1 1.9, which decreased further in the delayed image SUVmax2 1.2. This was a decrease of 36.84% compared to baseline value, (SUVmax2-SUVmax1) x100/SUVmax1. Another PET study with fluorine 18-fluorothymidine (^{18}F -FLT) on a different day showed negligible tracer uptake (Fig. 3), very faintly appreciable visually in the standard gray scale. Overall, both functional imaging examinations were highly suggestive of a benign lesion. Computed tomography guided fine needle aspiration cytology of the lesion was confirmatory of benign chondroid hamartoma (Fig. 4).

Pulmonary hamartomas constitute 5%-8% of all solitary lung tumors and about 75% of all benign lung tumors. They have little or no malignant potential, and most of them are

asymptomatic. They are composed of tissues that are normally present in the lung, including fat, epithelial tissue, fibrous tissue, and cartilage. However, they exhibit disorganized growth [1]. Accurate imaging interpretation and diagnosis are important because bronchogenic carcinoma is an important differential diagnosis [2]. Frequently they are discovered as an incidental coin lesion on a routine chest radiograph [3]. Popcorn calcification is virtually diagnostic on chest X-rays [3]. It is important to appreciate that a CT scan may be often inconclusive especially if the hamartoma atypically lacks cartilage and fat cells. In a recent report of squamous cell carcinoma developing in the setting of pulmonary hamartoma, hypermetabolism was noted in only half of the mass that correlated with the site of malignancy in the lesion [4]. Imaging by both labelled somatostatin analogue technetium 99m-depreotide ($^{99\text{m}}\text{Tc}$ -depreotide) and thallium 201-chloride can also be helpful in excluding malignancy [5].

As for treatment, peripheral tumors are usually simply observed after diagnosis; central tumors may be excised. Overall prognosis is excellent, though there are rare reports of malignant transformation [6, 7].

The importance of partial volume corrected SUV and uptake in the reticuloendothelial system has been emphasized in the literature to differentiate false positive studies for lung carcinoma in various benign conditions [8-11]. Partial volume correction of SUVs is of particular value in small malignant lesions where it aids in accurate assessment of disease activity and estimating the correct SUV [9]. Dual time point ^{18}F -FDG-

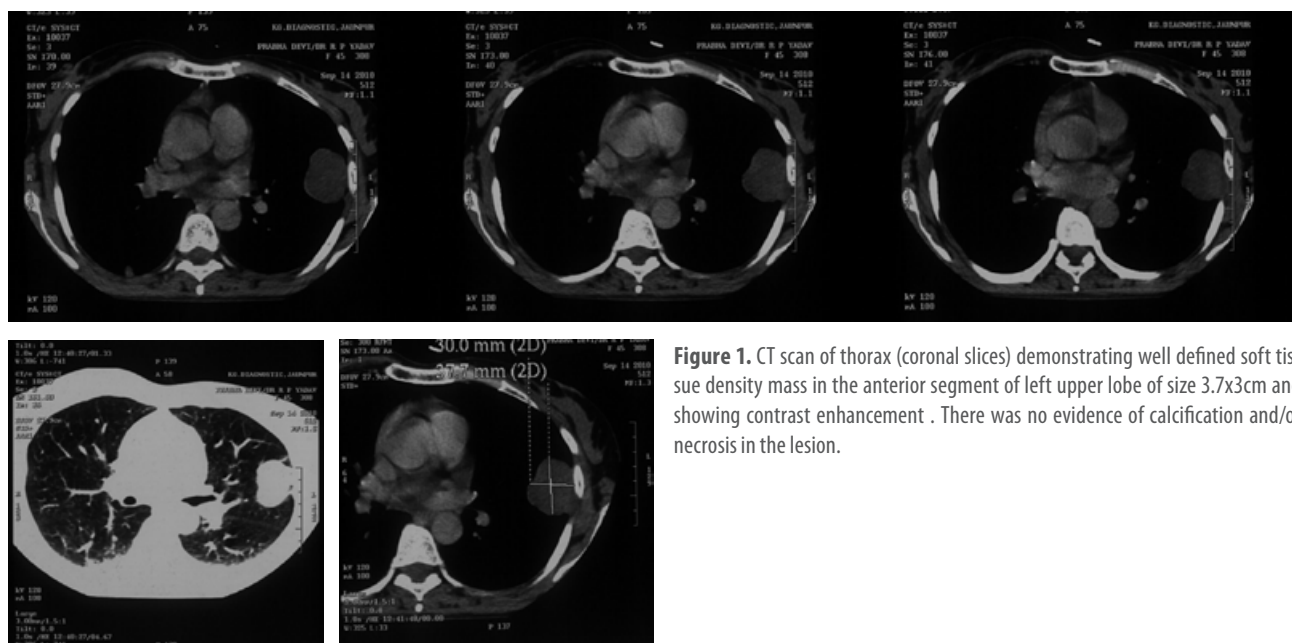


Figure 1. CT scan of thorax (coronal slices) demonstrating well defined soft tissue density mass in the anterior segment of left upper lobe of size 3.7x3cm and showing contrast enhancement. There was no evidence of calcification and/or necrosis in the lesion.

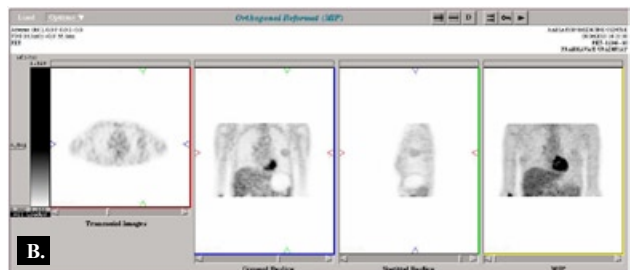
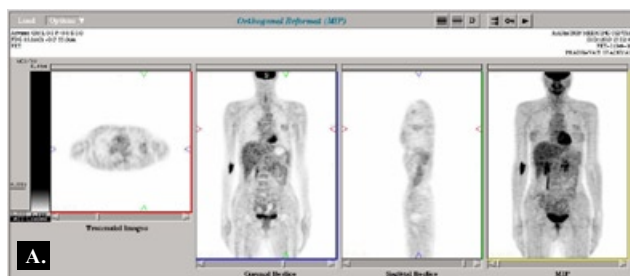


Figure 2A and B. Whole body ^{18}F -FDG-PET demonstrating mild tracer uptake at baseline ^{18}F -FDG-PET (SUVmax 1.9) which decreased further in the delayed image (SUVmax 1.2).

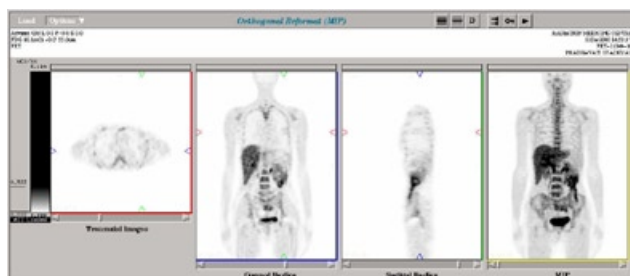


Figure 3. ^{18}F -FLT-PET showing negligible tracer uptake, very faintly appreciable visually in the standard gray scale.

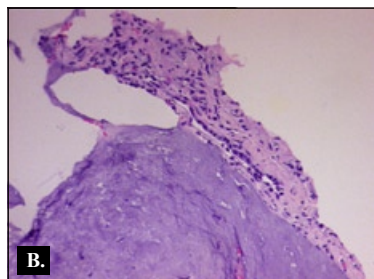
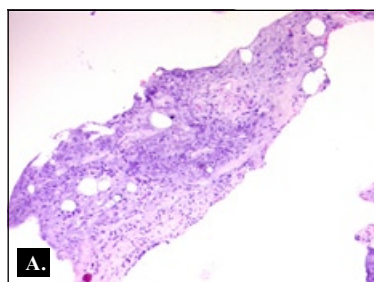


Figure 4a and b. Core biopsy of lung mass shows predominantly cartilage with myxoid areas admixed with a few adipocytes. A small gland lined by benign epithelial cells is seen towards the end of the biopsy.

PET appears to play an important role in enhancing the confidence of diagnosis [9]. In case of malignancy, this maneuver usually shows a rising SUVmax in delayed imaging, while benign lesions are described to show a falling trend, as was observed in the present case [9]. This was further substantiated by the finding in the ^{18}F -FLT-PET that virtually did not show any appreciable uptake in the lesion. FLT is thought

to be relatively more specific compared to ^{18}F -FDG in that it, being a cell proliferation tracer, usually does not concentrate in benign lesions.

In conclusion, we showed mild uptake of ^{18}F -FDG in the lesion and even lower in the delayed image, which indicated the benign nature of the lesion. The ^{18}F -FLT-PET did not show any tracer uptake in this lesion.

The authors declare that they have no conflicts of interest

Bibliography

- Zakharov V, Schinstine M. Hamartoma of the lung. *Diagn Cytopathol* 2008; 36(5): 331-2.
- Jacob S, Mohapatra D, Verghese M. Massive chondroid hamartoma of the lung clinically masquerading as bronchogenic carcinoma. *Indian J Pathol Microbiol* 2008; 51(1): 61-2.
- Park CM, Goo JM. Images in clinical medicine. "Popcorn" calcifications in a pulmonary chondroid hamartoma. *N Engl J Med* 2009; 360(12): e17.
- Lee BJ, Kim HR, Cheon GJ et al. Squamous cell carcinoma arising from pulmonary hamartoma. *Clin Nucl Med* 2011; 36(2): 130-1.
- Boundas D, Arsos G, Karatzas N et al. The contribution of conventional nuclear molecular imaging in characterising the nature of a growing solitary pulmonary nodule. Report of a case. *Hell J Nucl Med* 2007; 10(1): 29-32.
- Wood B, Swarbrick N, Frost F. Diagnosis of pulmonary hamartoma by fine needle biopsy. *Acta Cytol* 2008; 52(4): 412-7.
- Guo W, Zhao YP, Jiang YG et al. Surgical treatment and outcome of pulmonary hamartoma: a retrospective study of 20-year experience. *J Exp Clin Cancer Res* 2008; 27: 8.
- Bural G, Torigian DA, Houseni M et al. Tumor metabolism measured by partial volume corrected standardized uptake value varies considerably in primary and metastatic sites in patients with lung cancer. A new observation. *Hell J Nucl Med* 2009; 12(3): 218-22.
- Basu S, Alavi A. Partial volume correction of standardized uptake values and the dual time point in FDG-PET imaging: should these be routinely employed in assessing patients with cancer? *Eur J Nucl Med Mol Imaging* 2007; 34(10): 1527-9.
- Bural GG, Torigian DA, Chen W et al. Increased ^{18}F -FDG uptake within the reticuloendothelial system in patients with active lung cancer on PET imaging may indicate activation of the systemic immune response. *Hell J Nucl Med* 2010; 13(1): 23-5.
- Sager S, Ergul N, Ciftci H, Cermik F. False positive ^{18}F -FDG-PET/CT findings in a patient with talc pleurodesis. *Hell J Nucl Med* 2010; 13(2): 179-80.

Sandip Basu¹ MBBS (Hons), DRM, DNB, MNAMS, Saikat Nandy¹ MSc, M.G.R., Rajan¹ MSc, PhD, Mukta Ramadwar² MBBS, MD, Surendra H Moghe¹ BSc

¹ Radiation Medicine Centre, Bhabha Atomic Research Centre, Tata Memorial Centre Annexe, Parel, Mumbai,

² Department of Pathology, Tata Memorial Hospital, Mumbai.

Sandip Basu MBBS

Radiation Medicine Centre (BARC), Tata Memorial Hospital Annexe, Jeebai Wadia Road, Parel, Mumbai 400 012, E-mail: drsanb@yahoo.com

Hell J Nucl Med 2011;14(2):

Published on line: 16 June 2011