

Description of the thyroid hormone resistance syndrome illustrated by such a case, which had two different carcinomas and was mistreated with iodine-131

Jianjun Xue MM, Xi Jia MM,
Juan Li MM, Rui Gao MD,
Fenru Zhang MM,
Aimin Yang MD

Department of Nuclear Medicine,
First Affiliated Hospital of the Xi'an
Jiaotong University School of
Medicine, Xi'an, Shaanxi,
710061, China

Keywords: Papillary thyroid
carcinoma
-Nasal-small cell neuroendocrine
carcinoma
-Resistance to thyroid hormones
-Iodine-131 therapy

Correspondence address:

Aimin Yang MD. Department of
Nuclear Medicine, First Affiliated
Hospital of the Xi'an Jiaotong
University School of Medicine,
277#, Yanta West Road, Xi'an,
Shaanxi Province, China, 710061
Work phone: +86-29-85323644
yangaimin@mail.xjtu.edu.cn

Received:

6 October 2015

Accepted revised:

25 November 2015

Abstract

Objective: Hyperthyroidism with increased serum thyroid hormones and also increased thyroid stimulating hormone (TSH) is described as the resistance thyroid hormone (RTH) syndrome. This syndrome may be due to various factors including tumors. We describe the different types of RTH syndrome and mention that this syndrome may be misdiagnosed and mistreated. To illustrate the RTH syndrome we describe such a case which also had two different carcinomas. This case was treated with anti-thyroid drugs, triiodothyroacetic acid and iodine-131 (^{131}I). In the following 5.5 years after ^{131}I treatment, TSH progressively increased and was not suppressed by normal doses of L-thyroxine (L-T4). A thyroid nodule was diagnosed as papillary thyroid carcinoma (PTC) and a small cell neuroendocrine carcinoma was diagnosed in the nasal septum. Under L-T4 replacement treatment and after ablation of both carcinomas, TSH returned to normal. Small cell neuroendocrine carcinomas accompanied with PTC, are extremely rare causes of RTH. **Conclusion:** A description of the resistance to thyroid hormone syndrome is presented and this syndrome is illustrated by a referring case which could be of a selective pituitary type or due to the neuroendocrine tumor.

Hell J Nucl Med 2015; 18(3):247-251

Published online: 5 December 2015

Introduction

It is known that increased serum thyroid stimulating hormone (TSH) is common in hypothyroidism and in pituitary tumors and other tumors, while in a few of these tumors TSH shows resistance to thyroid hormones (RTH). Very rarely, small cell neuroendocrine carcinoma (SCNEC) secreting TSH together with papillary thyroid carcinoma may accompany the above. It is difficult to distinguish if the increased TSH and the RTH are due to SCNEC to papillary thyroid carcinoma (PTC), other tumors or other factors.

A detailed description of the RTH syndrome is illustrated in a female patient, presented with hyperthyroidism. This syndrome could, also be due to the selective pituitary type of RTH and not to the neuroendocrine tumor. Finally, after first mistreatment the patient was correctly treated.

The pathogenesis and classification of RTH

The resistant TH syndrome is due to a group of diseases characterized by high serum free triiodo thyronine (FT3) and/or free thyroxine (FT4), accompanied by elevated or normal TSH due to the target organ reactivity for decreased TH. The incidence of RTH is about 1:40000-50000 [1, 2]. The disease is autosomal dominant genetic due to mutations of the thyroid hormone receptor β gene (THR β) which cause reduced affinity of the receptor of TH [3, 4].

Clinical manifestations of RTH vary. Patients may have normal thyroid function, hyperthyroidism, hypothyroidism, usually accompanied by goiter. Resistant TH syndrome has 3 types: a) the systemic resistance type, b) the selective pituitary type (PRTH) and c) the selective peripheral resistance type. Characteristic features are that the very high doses of TH cannot normalize serum TSH, while the peripheral tissues do not respond to the excess of TH.

The systemic resistance type of RTH, affects the pituitary gland and the surrounding tissues. It is divided into two subtypes: a) with compensatory normal thyroid function and

b) with hypothyroidism. The compensatory normal thyroid function type has less resistance to TH, has goiter but no hyperthyroidism. The hypothyroidism subtype includes goiter, poor intelligence and underdevelopment of the patient.

In the PRTH type the pituitary gland does not respond to TH, while the peripheral tissues are not affected. There may be two reasons for this disease [3, 4], one is the pituitary T3 receptor beta 1 and beta 2 gene mutations. These mutations decrease the affinity of T3 to thyroid hormone receptor (THR). Another reason is that the activity of type 5' iodine enzyme in the pituitary decreases and the production of pituitary T3 receptors declines, which cannot effectively inhibit TSH secretion from the pituitary gland, leading to increased serum TSH, increased T3 and T4 synthesis and goiter. Clinical manifestations are: mild or moderate hyperthyroidism, without exophthalmos, or pretibial myxedema or other signs of Grave's disease.

The main feature of the selective peripheral resistance type is that the surrounding tissues are not sensitive to TH, while the pituitary gland responds normally to TH. Clinically there is hypothyroidism and goiter.

The diagnosis and treatment of RTH

The diagnosis of RTH depends on the confirmation of the THR β gene. If there are any of the following signs or symptoms, RTH may be considered: a) Goiter, no thyroid function abnormalities, and serum TH repeatedly elevated. b) Goiter, hypothyroidism, serum TH elevated. c) Goiter, hyperthyroidism, elevated serum TSH and TH, and pituitary tumors excluded. d) After the use of larger doses of TH preparations, hypothyroidism is still marked. e) After using a variety of treatments for hyperthyroidism, the disease is not easy to control, while pituitary TSH tumors are excluded. f) Family members have: elevated or normal TSH levels, mental retardation, delayed epiphyseal maturation, stippling like bones, congenital deafness, negative perchlorate test, and negative thyroglobulin (TG) and thyroid microsomal antibodies (TMAB).

Factors that can lead to high serum TSH should be recognized, like: pituitary TSH tumors or pituitary excessive secretion of TSH or TRH, or TSH secretion stimulated by other factors.

Patients without clinical symptoms generally do not need treatment. Those who have symptoms of hypothyroidism need high doses of thyroid hormones and those with hyperthyroidism need symptomatic treatment. The principle of treatment for PRTH is that treatment should not only try to inhibit the secretion of TSH, but also should not aggravate the symptoms of hyperthyroidism. We commonly use triiodoacetic acid (TRIAc), a thyroid hormone analogue, that can suppress TSH secretion without increasing peripheral TH. Other drugs such as octreotide, levodopa and the dopaminergic agonist bromocriptine, can in short term suppress TSH and TH, but their long-term effect is not significant. The antithyroid drugs, surgery and iodine-131 (^{131}I) treatment should not be used, because although they can reduce the level of TH and alleviate symptoms, they can stimulate TSH secretion and lead to cell proliferation of the

pituitary. We must avoid using these treatments as possible. Gurnell et al (1998) and Marazuela et al (2008) have reported patients with RTH and hyperthyroidism, pituitary hyperplasia after ^{131}I treatment and surgical thyroidectomy [5, 6]. Theoretically, long term elevated TSH levels could lead to a pituitary TSH tumor or to thyroid carcinoma, but so far there is only one case reported with a pituitary tumor [7]. A few studies also show that hypersecretion of TSH may be associated with the incidence of thyroid cancer, but whether the PTC of the patient described below was associated with excessive secretion of TSH by the PTC or by the SCNEC is still a question [8, 9].

We describe below in detail a case with RTH in order to illustrate the difficulties in diagnosing and treating the RTH syndrome.

A female, 29 years old patient had for three years hyperthyroidism, increased serum T3, T4, FT3, FT4 and TSH and was misdiagnosed and mistreated for 5.5 years. After that, nasal SCNEC, PTC and RTH were diagnosed. We reviewed the literature in order to decide about the cause of RTH.

The patient had a small goiter and symptoms of hyperthyroidism, mainly palpitations, sweating and frequent defecations. Her serum T3 was 473ng/dL (reference value, 65-240ng/dL), T4 27.5 μg /dL (reference value, 5.5-13 μg /dL), FT3 was 14.5pmol/L (reference value, 2.8-8.5pmol/L), FT4 was 50.3pmol/L (reference value, 9.5-26.5pmol/L), TSH was 10.4 μIU /mL (reference value, <10 μIU /mL). Thyroglobulin antibodies and TMAB were negative. She was diagnosed as having hyperthyroidism.

Her mental state, her intelligence and body development were normal. She lisped and was deaf from her left ear and partly deaf from her right ear. From her past history she had pneumonia at the age of two and was treated with unknown doses of streptomycin. At the same age she gradually developed hearing loss accompanied by language barriers and lisps. Audiometry showed neurosensory hearing loss. She did not report a similar syndrome or any thyroid disease in her family history. Her period started at 11 years and was irregular.

After treated with methimazole 30mg/d for six months and with 10-15mg/d for 3 years, she was still hyperthyroid as above so she referred again to us. The patient had tachycardia, syncope, blood pressure 160/100mmHg, height 163cm and weight 56kg.

She had no exophthalmos and her goiter was still small, soft with no nodules. She had no hands tremor, no vascular murmur and no anterior tibia myxedema. Routine urine, blood including serum proteins, tests and thyroid antibodies were normal. Human chorionic gonadotropin, follicular stimulating hormone, luteinizing hormone, estrogen and progesterone were normal. Magnetic resonance imaging of the skull and the sella were normal. Thyroid scanning with technetium-99m showed diffuse thyroid enlargement.

After stopping methimazole treatment for one month, we performed the T3 suppression test. The test showed that the replacement dose of L-T3 (50-100 μg /d) did not suppress TSH, while the high dose of L-T3 (200 μg /d) partially inhibited the synthesis and secretion of TSH.

She then received TRIAC 0.375mg/d for half a year, but her goiter did not significantly change, neither the TH and TSH le-

Table 1. Serum thyroid function before and after ^{131}I treatment

Date	T4 ($\mu\text{g/dL}$) Reference 4.2-13.5	T3 ($\mu\text{g/dL}$) Reference 0.8-2.2	Ft4 (pmol/L) Reference 9.05-25.5	Ft3 (pmol/L) Reference 2.91-9.08	TSH ($\mu\text{IU/mL}$) Reference 0.25-5	TGAb Reference <30%	TMAb Reference <20%
Before ^{131}I treatment *	20.0	3.37	54.9	17.7	5.07	5.48	1.88
3.5-5.5yrs after ^{131}I	10.2-13.0	1.4-2.1	/	/	46.0-90.8	3.6-5.1	2.4-4.9

* Stopped antithyroid drugs for three weeks

vels.

Because the anti-thyroid drug treatment was not effective, the patient received ^{131}I treatment with 444MBq. At that time, her goiter increased, but remained soft, with no nodules, or vascular murmur (Table 1). Thyroid peroxidase antibodies were <15.0U/mL (reference value <15.0U/mL). The 24hr thyroid ^{131}I uptake rate was 49%, the effective ^{131}I half-life was 6 days. Three months later hypothyroidism appeared. Then she was given L-T4 100 μg per day. She did not become hyperthyroid while TSH increased gradually up to 90.8 $\mu\text{IU/mL}$ (Table 1).

After 5 years from her first visit to our department we palpated a nodule in the right lobe of the thyroid. Cervical ultrasound showed multiple solid nodules with calcification in the right lobe of the thyroid. Her parathyroid hormone and serum calcium were normal. Fine-needle puncture of the larger nodule showed PTC. Otolaryngology examination showed a soft granulation-like neoplasia at the rear end of nasal septum in the right nasal cavity while the CT scan showed right inferior turbinate hypertrophy (Figure 1). Electronic laryngoscopy showed a nasal mucosal smooth surface tumor, which is back projected (Figure 2).

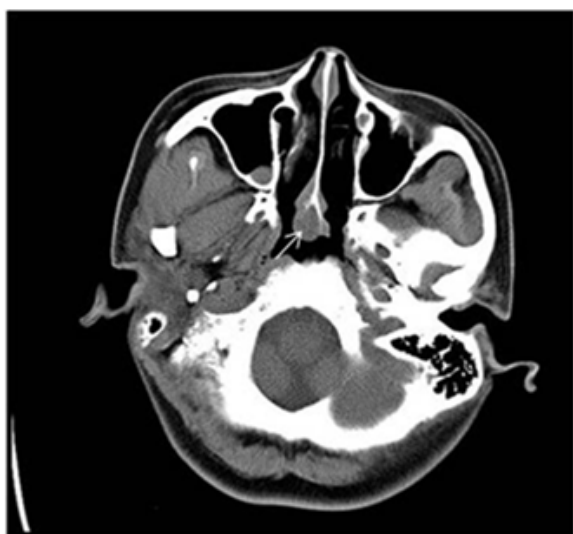


Figure 1. CT showed hypertrophy of the inferior turbinate.

By general anesthesia she underwent total thyroidectomy with cervical lymph nodes dissection, and endoscopic nasal

tumor resection. The tumor in the right lobe of the thyroid was about 2cmx1cmx1cm, hard and mildly adhered to the surrounding tissues. Figure 3 shows the thyroid papillary carcinoma in the right lobe.

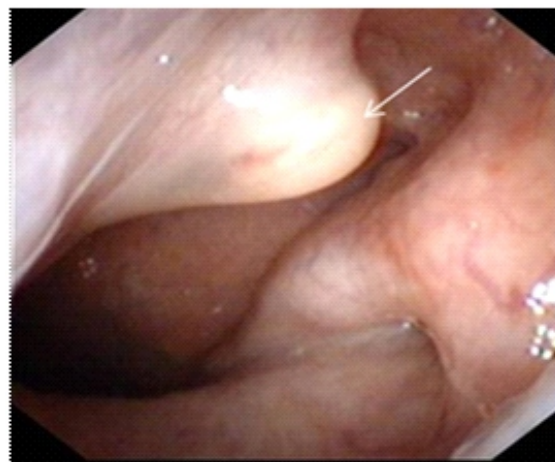


Figure 2. Electronic laryngoscopy showed a neoplasm in the nasal septum.

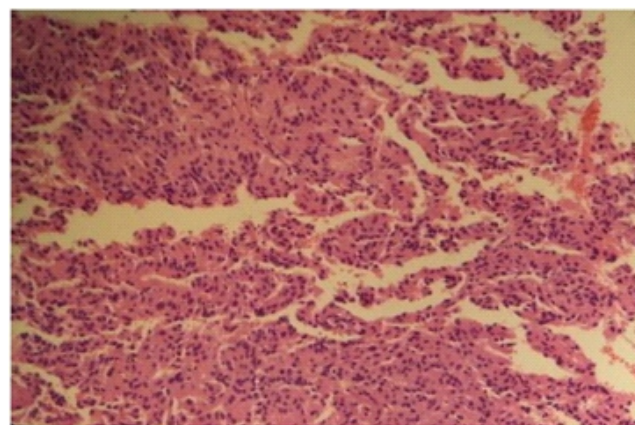


Figure 3. Thyroid papillary carcinoma of a nodule in the right thyroid lobe.

The left and the right recurrent laryngeal nerve lymph nodes, and the right common carotid lymph nodes had no metastases. Nasal-small cell invasive, poorly differentiated neuroendocrine carcinoma is shown in Figure 4.

The PTC was type pT1bN0M0, while the SCNEC was pT3N0M0. The patient was given the EP scheme chemotherapy (etoposide 100mg on days 1-5 and cisplatin 40mg on days 1-3) in 6 cycles and also a course of radiotherapy (IMRT

Table 1. Serum thyroid function before and after ^{131}I treatment

Date	T4 ($\mu\text{g/dL}$) Reference 4.2-13.5	T3 ($\mu\text{g/dL}$) Reference 0.8-2.2	Ft4 (pmol/L) Reference 9.05-25.5	Ft3 (pmol/L) Reference 2.91-9.08	TSH ($\mu\text{IU/mL}$) Reference 0.25-5	TGAb Reference <30%	TMAb Reference <20%
Before operation	9.73	1.70	23.3	5.83	45.0	4.90	3.96
After: 10 days- 7 months	7.4-13.5	0.73-1.37	16.8*	2.94*	1.0-5.3	2.3-5.0	2.0-5.8
8 months- 27 months	12.0-17.7	0.8-1.8	22.0**	5.36**	0.51-4.0	2.7-4.3	1.7-3.5

*: after 30 days, **: at 12 months after operation

4MV-X line DT50Gy/25f). Four, 12 and 18 months after operation the patient's review of Tg, thyroid ultrasound, CT of the paranasal sinuses, chest and abdomen, bone scintigraphy and electronic endoscopy showed no obvious abnormalities. Under L-T4 suppression therapy, thyroid hormones and TSH were normal (Table 2).

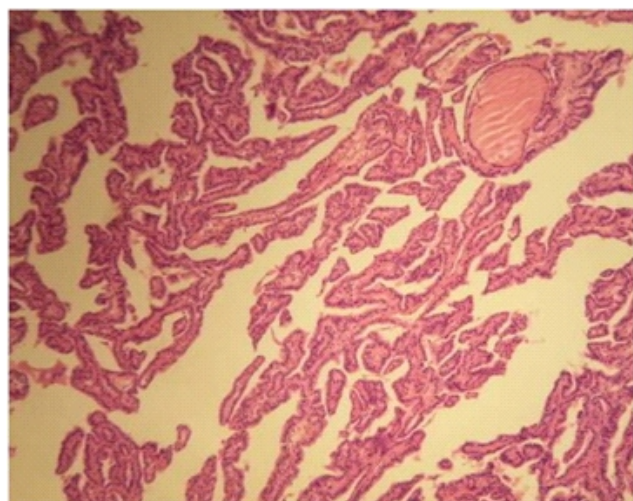


Figure 4. Nasal-small cell neuroendocrine carcinoma.

The diagnosis and treatment of RTH

In this exemplary case, TH and TSH were increased and accompanied by symptoms of hyperthyroidism. Pituitary MRI showed no abnormalities. TGAb, TMAb, TSHAb and other auto antibodies were negative. The 1-10 exon mutation was not found when the patient and her parents' thyroid hormone receptor β gene (THR β) were examined [10, 11]. According to these results, we could exclude a pituitary TSH tumor and Graves' disease. High doses of L-T3 could partially inhibit the synthesis and secretion of TSH. Treatment with TRIAC for six months failed to decrease the TSH and TH levels significantly. The reason may be, severe resistance of the pituitary TSH, inadequate dosage of TRIAC, or a short medication time. Data have shown that in about 15% of RTH cases we cannot detect THR β mutations [12]. It has

been reported that pituitary RTH was unrelated to THR β gene mutation [10].

Pituitary RTH can easily be misdiagnosed as hyperthyroidism [13]. Actually, there are cases wrongly using ^{131}I treatment as in our case [14, 15]. There are also some other cases of RTH which were treated with ^{131}I [5, 13, 16]. At present, we could not find any reports about TSH dynamic changes after ^{131}I treatment or after surgery for PRTH.

Sivakumar and Chairdarun (2010) reported one case of Grave's disease with hypothyroidism after ^{131}I treatment, using L-T4 325 $\mu\text{g/d}$ by which they could just maintain normal levels of TSH. The THR β test confirmed Grave's disease combined with RTH [13].

In the case described, TSH progressively increased up to 90.8 $\mu\text{IU/mL}$, thus we should have considered the possibility of exogenous TSH secretion. According to Mohammed et al. (1998) [16], hypothyroidism which appears in RTH hyperthyroidism after treated by ^{131}I was quite difficult to treat. After cancer surgery in the nasal cavity, TSH was suppressed by L-T4 replacement therapy, suggesting that the pituitary had normal response to TH, which is inconsistent with the above report, and contradicts with the mechanism of the elevated TSH in PRTH and indicates that the patient's elevated TSH could be due to SCNEC secretion. The TSH secretion in SCNEC may be considered as being in accord with results of the L-T3 suppression test, TRIAC treatment and of the negative THR β mutation.

Nasal SCNEC is an extremely rare, highly malignant tumor and accompanied with PTC is even rarer. We found no such report in the literature. Due to the rapid progression of nasal SCNEC, in our case, survival may be poor [17, 18]. Others reported a 5 years survival rate in only 27.5% of these cases. Conversely, PTC develops slowly, with good prognosis, Mazzaferri and Young (1981) [19] followed-up 576 cases with PTC for 10 years. Only 6 died, and the others had a low risk for death. Differentiated thyroid carcinoma (DTC), of 1-2cm confined within the thyroid gland, does not recommend or oppose to ^{131}I treatment [20, 21].

This patient who had surgery 27 months before is now in good physical condition, has a good quality of life, and there are no signs of tumor recurrence. Nevertheless she needs a lo-

nger follow-up.

In conclusion, a description of the resistance to thyroid hormone (RTH) syndrome is presented and illustrated by a female patient, presented with hyperthyroidism. It is discussed whether the RTH syndrome was of a selective pituitary type or due to the neuroendocrine tumor. After first mis-treatment, the patient was correctly treated.

The authors declare that they have no conflicts of interest

Bibliography

1. Tajima T, Jo W, Fujikura K et al. Elevated free thyroxine levels detected by a neonatal screening system. *Pediatr Res* 2009; 66: 312-6.
2. Lafranchi SH, Snyder DB, Sesser DE et al. Follow-up of newborns with elevated screening T4 concentrations. *J Pediatr* 2003; 143: 296-301.
3. Jie Zhu, Jinrong Li. Further Recognition of thyroid hormone resistance. *Medical Recapitulate* 2004; 10: 183-4.
4. Jun shen, Maohua Yu. Research progress in thyroid hormone resistance. *Foreign Medical Sciences (Section of Endocrinology)* 2002; 22: 81-4.
5. Gurnell M, Rajanayagam O, Barbar I et al. Reversible pituitary enlargement in the syndrome of resistance to thyroid hormone. *Thyroid* 1998; 8: 679-82.
6. Marazuela M, Nattero L, Moure D et al. Thyroid hormone resistance and pituitary enlargement after thyroid ablation in a woman on levothyroxine treatment. *Thyroid* 2008; 18: 1119-23.
7. Safer JD, Colan SD, Fraser LM et al. A pituitary tumor in a patient with thyroid hormone resistance: a diagnostic dilemma. *Thyroid* 2001; 11: 281-91.
8. Jonklaas J, Sarlis NJ, Litofsky D et al. Outcomes of patients with differentiated thyroid carcinoma following initial therapy. *Thyroid* 2006; 16: 1229-42.
9. Peishun Wang, Honghao Li, Tianli Huang et al. Serum thyroid stimulating hormone level and risks of differentiated thyroid cancer. *Chin Arch Gen Surg (Electronic Edition)* 2011; 5: 512-5.
10. Bingyin Shi, Jing Liang. Clinical and THRβ gene mutation study on pituitary thyroid hormone resistance syndrome. *Journal of Xi'an Jiao Tong University (Medical Science)* 2008; 29: 663-6.
11. Jingfang Liu, Bingyin Shi. Clinical analysis of 10 patients with thyroid hormone resistance. *Journal of Xi'an Jiao Tong University (Medical Science)* 2011; 32: 393-5.
12. Jiskra J, Límanová Z. Resistance to thyroid hormones. *Cas Lek Cesk* 2014; 153: 137-41.
13. Sivakumar T, Chaidarun S. Resistance to thyroid hormone in a patient with coexisting Graves' disease. *Thyroid* 2010; 20: 213-6.
14. Changtian Guan. One case of Selective Pituitary thyroid hormone resistance syndrome. *Chin J Nucl Med* 2004; 24: 125.
15. Chao Ma, Anren Kuang, Changtian Guan. Selective Pituitary thyroid hormone resistance syndrome: a case report and review of the literature. *West China Med J* 2005; 20: 129-30.
16. Mohammed IA, Aldasouqi S, Schnute R et al. The syndrome of resistance to thyroid hormone, misdiagnosed and treated as thyrotoxicosis. *Endocr Pract* 1998; 4: 391-5.
17. E Babin, V Rouleau, PO Vedrine et al. Small cell neuroendocrine carcinoma (SNEC) of the sinonasal tract is a rare disease. *Laryngol and Otology* 2006, 120: 289-97.
18. Haiyan Zhang, Linying Xue, Qingfang Cheng. Nasal Neuroendocrine Carcinoma: A Report of 6 Cases. *J Fudan Univ (Med Sci)* 2001; 28: 337-9.
19. Mazzaferri EL, Young RL. Papillary thyroid carcinoma: a 10 year follow-up report of the impact of therapy in 576 patients. *Amer J Med* 1981; 70: 511-8.
20. Head and Neck Surgery Group, Editorial Board of Chinese Journal Otorhinolaryngology Head and Neck Surgery. Discussion on Clinical guideline of differentiated thyroid carcinoma. *Chinese J Otorhinolaryngol Head and Neck Surgery* 2011; 46: 881-8.
21. Chinese society of Nuclear Medicine. Clinical guideline for ¹³¹I therapy of differentiated thyroid cancer (2014). *Chin J Nucl Med Moll Imaging* 2014; 34: 264-78.