

The early diagnosis of testicular natural killer/T-cell lymphoma

Pei Shu¹ MD,
Wenwu Ling² PhD,
Chenjing Zhu¹ PhD,
Jianchao Wang³ MD,
Chong Jiang⁴ MD,
Weiwei Zhang⁴ MD,
Yue Xiao³ MD,
Xuelei Ma¹ PhD

* Pei Shu, Wenwu Ling, and Chenjing Zhu contributed equally to this work.

1. State Key Laboratory of Biotherapy and Cancer Center, West China Hospital, Sichuan University, and Collaborative Innovation Center for Biotherapy, Chengdu, China
2. Department of Ultrasound, West China Hospital, Sichuan University, Chengdu, China
3. West China Hospital, Sichuan University, Chengdu, China
4. Department of Radiology, West China Hospital, Sichuan University, Chengdu, China

Keywords: -Testicular natural killer/T-cell lymphoma.
- Contrast-enhanced ultrasound
- Positron emission tomography/computed tomography

Corresponding author:

Xuelei Ma PhD,
State Key Laboratory of Biotherapy and Cancer Center, West China Hospital, Sichuan University, and Collaborative Innovation Center for Biotherapy. No. 17, section 3, Renmin Road South, Chengdu, Sichuan 610041, China.
Fax: +86 2885502796
drmaxuelei@gmail.com

Received:

14 August 2016

Accepted revised:

31 October 2016

Abstract

Testicular natural killer/T-cell lymphoma is a rare aggressive extranodal lymphoma associated with Epstein-Barr virus infection. Time to diagnose is crucial as the disease is rapidly progressive and fatal. Early suspicion is documented by imaging studies and testicular biopsies which are key factors for diagnosing testicular natural killer/T-cell lymphoma. However, no reports have described the results of imaging studies. In this paper, contrast-enhanced ultrasonography (CEUS), fluorine-18-fluorodeoxyglucose-positron emission tomography/computed tomography (¹⁸F-FDG PET/CT) and tumor biopsies were all diagnostic of testicular natural killer/T-cell lymphoma. The CEUS showed a clear hyperenhancement which strongly indicated malignant tumor. *In conclusion*, in our study, CEUS as a first line easy test, may help physicians to make an early diagnosis of the very rare case of testicular T-lymphoma.

Hell J Nucl Med 2016; 19(3): 275-277

Epub ahead of print: 8 November 2016

Published online: 10 December 2016

Introduction

Extranodal natural killer/T-cell lymphoma is a rare subtype of non-Hodgkin's lymphoma and is extremely rare when it is found in the testes [1, 2]. Diffuse large B-cell lymphoma with an aggressive clinical course constitutes more than 70% of testicular lymphomas [3]. Testicular natural killer/T-cell lymphoma is a rare entity with tumor cells expressing CD56, either primarily or secondarily. Diagnostic workup of the testicular natural killer/T-cell lymphoma involves clinical examination, imaging results and testicular tumor biopsies [4].

Contrast-enhanced ultrasound (CEUS), is a new US modality which can visualize small vessels. The second-generation contrast medium, is able to detect and characterize lymphoma with a high sensitivity and specificity. We reported a case in which CEUS played a central role in early diagnosing testicular natural killer/T-cell lymphoma.

This report has been approved by the Institutional Review Board and patients gave their informed consent.

Case Report

A 39 years old man was referred to the Department of Head and Neck Oncology, Cancer Center, of West China Hospital. He had a history of stuffy nose diagnosed in another hospital as a deviation of nasal septum and was treated with diorthosis for deflection of the nasal septum. The nasal biopsy showed inflammation only. Few months later, the patient had a painful testicular mass accompanied by night sweats. The results of physical examinations were unremarkable except for the left testicular mass. Routine laboratory tests showed elevated aspartate aminotransferase/alanine transaminase (AST/ALT) about four times above normal limits, Epstein Barr virus (EBV) IgG positive and HbsAg positive which indicated the potential of active hepatitis B infection.

Computed tomography (CT) of the testis was carried out using contrast agent but showed only blurry images. Gray-scale US showed round hypoechoic formation compared to normal parenchyma, which is common in all testicular lesions and hardly showed cells differentiation. As the patient refused to undergo radical orchiectomy, we performed contrast-enhanced ultrasonography (CEUS) which allowed visualization of testi-

cular micro-vascularization with microbubbles well-distributed in the testis at a 8.35sec after the intravenous injection of microbubbles contrast media. Furthermore, a clear hyper-enhancement was shown in the surrounding testicular tissues (Figure 1). This was a strong indication of malignant tumor in the setting of the nodule in the testis. Compared to normal testicular structures, the testicular NK/T-cell lymphoma after the injection of microbubbles contrast media, showed a shorter rise time as 8.35sec, a shorter time to reach peak intensity as 38.69sec and a higher peak intensity as 8.31dB (Figure 2). We re-estimated the biopsy result sent from an outside institution and found dense and diffuse proliferation of medium to large sized atypical lymphoid cells population. The tumor cells were positive for clusters of differentiation CD3 and CD56. What's more, EBV-encoded small RNA (EBER)-in situ hybridization (ISH) had a positive result with a negative result in CD20. Based on the radiological images and the biopsy results, we preliminary diagnosed testicular natural killer/T-cell lymphoma. To verify, we used fluorine-18-fluorodeoxyglucose positron emission tomography/computed tomography (^{18}F -FDG PET/CT) scan, which is increasingly used for diagnosis, staging and response to treatment of lymphomas.

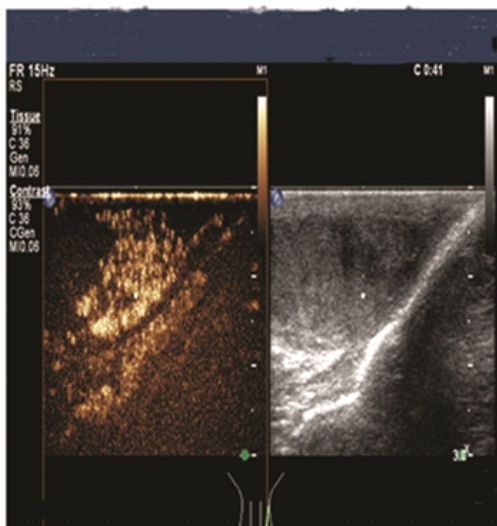


Figure 1. Testicular NK/T cell lymphoma shows a clear hyper-enhancement in CEUS (left) but not in color-coded sonography (right).

The image of ^{18}F -FDG PET/CT showed increased ^{18}F -FDG uptake in many areas of the body. The maximum standardized uptake value SUV was 30 and the SUVmax in the testis was 9.5 (Figure 3). The abnormal ^{18}F -FDG uptake in the testis and the biopsy results proved testicular lymphoma which was in accordance with the result of CEUS.

Discussion

Enatural killer/T-cell lymphoma which is a rare type of non-

Hodgkin's lymphoma often invades the midline part of human body such as the nasal cavity and nasopharynx [5].

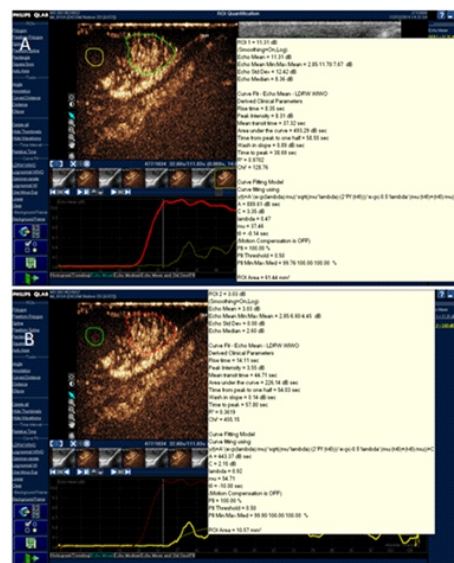


Figure 2. The image of normal testicular structures showed in 57.8sec peak intensity as 3.55dB (A) and the image of testicular lymphoma showed the peak intensity at 38.69sec and 8.31dB (B).

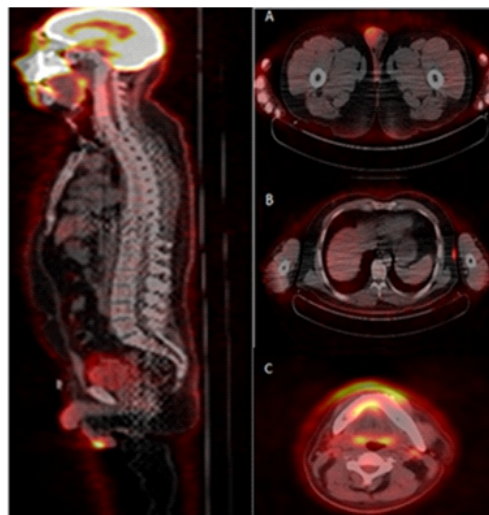


Figure 3. The image shows increased ^{18}F -FDG uptake in both nasal cavities, nasal septum, superior alveolar, upper gum © subcutaneous soft tissue nodules of the left chest wall, subcutaneous soft tissue of the left abdominal wall (B) and left testicle (A).

The disease also presents in extranodal sites such as the testis. Al-Hakeem (2007) reported the first case of primary testicular natural killer/T-cell lymphoma which was diagnosed by radical orchiectomy and pathology and staged by computed tomography (CT) scans of the chest and abdomen plus bilateral bone marrow biopsies [4]. In our study, the characteristics of the natural killer/T-cell lymphoma were typical, as the nasal tissue biopsy showed dense and diffuse proliferation of medium to large sized atypical lymphoid population expressing CD3 and CD56. Further examinations were accordingly performed to confirm the diagnosis. Computed tomography of the testis revealed unidentified testicular mass

with rounded hypoechoic formations compared with normal parenchyma on US and hardly showed differentiation. On the contrary, the lesion was visualized as having high glucose uptake on ^{18}F -FDG PET/CT.

Diagnosis of testicular natural killer/T-cell lymphoma is often difficult and depends on pathology. Although biopsy is the gold standard, may harm the testes physical functions or the psychology of the patient. It is useful to make an early diagnosis, for better treatment and prognosis [6-8].

Computed tomography and US are traditional methods in diagnosing testicular lesions but have poor specificities. Recent reports showed that the ^{18}F -FDG PET/CT was accurate and reliable in diagnosing and staging lymphoma. The pooled sensitivity and specificity of ^{18}F -FDG PET/CT in the diagnosis of natural killer/T-cell lymphoma were 0.95 (95% CI: 0.89-0.98) and 0.40 (95% CI: 0.09-0.78), respectively [4]. However, the radiation and high cost of PET/CT call for another diagnostic method.

The CEUS has been used in the detection and differentiation of lesions in parenchymatous organs due to the recent development of microbubble contrast media and imaging techniques. Thus the CEUS has the potential in diagnosing the extra-nodular natural killer/T lymphoma and might help in the preoperative assessment of testicular masses with hyper-vascularization as a key characteristic in the diagnosis of malignancy [9]. In our case, the testicular mass presented a clear hyper-enhancement in contrast to the surrounding testicular tissues in the CEUS mode. This was a strong indication of malignancy and showed the role of CEUS in diagnosing testicular natural killer/T-cell lymphoma. We believe that CEUS can be a quick, reliable, and easy to apply diagnostic procedure for testicular lymphoma. What's more, CEUS can prevent in some patients orchietomy and biopsy.

In conclusion: To our knowledge, this is the first study describing the features of testicular natural killer/T-cell lymphoma using CEUS. The continuous real-time imaging and the cost savings makes CEUS superior to CT and ^{18}F -FDG PET/CT. In addition, adverse events are rare and the technology may be available even in remote and poor areas. However, further evaluation of the use of CEUS in the diagnosis of testicular lymphoma is needed.

The authors declare that they have no conflicts of interest

The authors declare that they have no conflicts of interest

Bibliography

1. Au WY. Clinicopathologic features and treatment outcome of mature T-cell and natural killer-cell lymphomas diagnosed according to the World Health Organization classification scheme: a single center experience of 10 years. *Annals Oncol* 2005; 16: 206.
2. Kobayashi T, Hangaishi A, Yamamoto G. Successful treatment of secondary NK/T-cell lymphoma of the testis. *Annals Hematol* 2013; 92: 997.
3. Al-Abbadi MA, Hattab EM, Tarawneh M. Primary testicular and paratesticular lymphoma: a retrospective clinicopathologic study of 34 cases with emphasis on differential diagnosis. *Arch Pathol & Labor Med* 2007; 131: 1040.
4. Al-Hakeem DA, Fedele S, Carlos R. Extranodal NK/T-cell lymphoma, nasal type. *Oral Oncol* 2007; 43: 4.
5. Suzuki R. Pathogenesis and treatment of extranodal natural killer/T-cell lymphoma. *Semin Hematol* 2014; 51: 42.
6. Zhou X, Lu K, Geng L. Utility of PET/CT in the Diagnosis and Staging of Extranodal Natural Killer/T-Cell Lymphoma: A Systematic Review and Meta-Analysis. *Medicine* 2014; 93: e258.
7. Karantanis D, Subramaniam RM, Peller PJ. The value of [^{18}F] fluorodeoxyglucose positron emission tomography/computed tomography in extranodal natural killer/T-cell lymphoma. *Clin Lymph & Myeloma* 2008; 8: 94.
8. Hu YJ, Liang JH, Fan L. Application of ^{18}F -FDG PET/CT images in the newly diagnosed extranodal NK/T cell lymphoma. *J Experim Hematol/Chinese Association of Pathophysiology* 2015; 23: 127 (in chinese).
9. Lock G, Schmidt C, Helmich F. Early experience with contrast-enhanced ultrasound in the diagnosis of testicular masses: a feasibility study. *Urology* 2011; 77: 1049.