

Central nervous system disorders affecting the heart—insights from radionuclide imaging

Alexandros Georgakopoulos M.D, Nikoletta Pianou M.D, Constantinos Anagnostopoulos M.D, PhD, FRCP, FRCR, FESC

Centre for Clinical and Translational Research; Biomedical Research Foundation of the Academy of Athens, 4 Soranou Ephessiou Street, PC 11527, Greece. Tel: +302106597126/+302106597067, Fax: +302106597502, cdanagnostopoulos@bioacademy.gr

Hell J Nucl Med 2016; 19(3): 189-192

Epub ahead of print: 8 November 2016

Published online: 10 December 2016

Abstract

There is a growing research activity focusing on the brain heart cross-talk. A great variety of brain disorders affect the heart and recent developments in neurosciences have revealed the particular role of specific neuroanatomic sites on heart rhythm and rate, myocardial function and vascular tone. Cardiac radionuclide imaging plays a pivotal role in this setting, since not only helps elucidating underlying pathobiological mechanisms but in addition, it promises exciting possibilities for early identification of patients at risk of developing cardiovascular manifestations of certain neurological diseases.

Introduction

There is a growing research activity focusing on the brain heart cross-talk. A great variety of brain disorders affect the heart and recent developments in neurosciences have revealed the particular role of specific neuroanatomic sites on heart rhythm and rate, myocardial function and vascular tone. Cardiac radionuclide imaging plays a pivotal role in this setting, since not only helps elucidating underlying pathobiological mechanisms but in addition, it promises exciting possibilities for early identification of patients at risk of developing cardiovascular manifestations of certain neurological diseases.

There is a growing interest in understanding the interactions between the brain and heart driven by the need to identify, at an early stage, patients at risk for developing cardiovascular manifestations due to neurological diseases. The central nervous system (CNS) by modulating excitatory and inhibitory influences on autonomic discharge can regulate arterial pressure, vasomotor tone as well as cardiac output, rate, rhythm and metabolism. Important developments in neuroanatomy and neurophysiology have made a major contribution in identifying the role of specific sites such as insular cortex, amygdala and hypothalamus in modulating heart rhythm and rate, myocardial function and vascular tone. It is now clear that insular cortex is associated with the generation of arrhythmias and release of cardiac enzymes by vascular disease or epileptic phenomena. Specifically, involvement of the right insula can influence the generation of tachyarrhythmias and a pressor response, whilst involvement of the corresponding left, induces bradycardia and a depressor response [1]. Amygdala is considered as a mediator of cardiovascular responses to emotional stimuli and particularly of negative stress responses [2]. Furthermore, damage to the hypothalamus is correlated with myocardial necrosis in subarachnoid hemorrhage [3]. Additionally, the brainstem is essential in mediating autonomic tone of the cardiovascular system [4].

Understanding of the brain-heart cross talk has been greatly enhanced during the last decade by observations from a variety of clinical settings. Many causes can affect the CNS including brain or spinal cord injury resulting from trauma, infections (meningitis, encephalitis), degeneration (Parkinson's, Alzheimer's disease), tumors, vascular (stroke, subarachnoid hemorrhage) and functional (in epilepsy disorders) [5]. In the section below we discuss briefly the main observations derived from cardiac radionuclide imaging studies in the setting of brain disorders, with an emphasis on their patho-physiological significance and potential implications for management decisions.

Investigation of the brain heart cross-talk by cardiac radionuclide imaging

Neurogenic stress cardiomyopathy (NSC)

Neurogenic stress cardiomyopathy is developed secondary to severe acute neurologic injury. It has been intensely investigated during the last decade and it is now known that brain damage resulting in increased intracranial pressure induces an autonomic storm with elevation in tissue catecholamine levels. Inflammation with elevated levels of cytokines has also been reported. Cardiac involvement is expressed either in terms of electrocardiographic signs (e.g. long Q-T syndrome

and torsade de points, S-T-segment depression, T-wave inversion, and ventricular as well as supraventricular arrhythmias), or in the form of left ventricular (LV) wall motion abnormalities, myocardial necrosis enzyme release, and increased B-type natriuretic peptide [6].

A common cause of NSC is Subarachnoid hemorrhage (SAH) that occurs following aneurysm rupture and is associated with poor outcome and high mortality. Neurogenic stress cardiomyopathy may be complicated by neurogenic stunned myocardium with massive release of catecholamines which may cause transient cardiac dysfunction with a variety of abnormalities including electrocardiographic changes, like arrhythmias, LV dysfunction and necrosis [7]. Prunet et al. (2014) studied the modification in cardiac metabolism after SAH. They reported that in hemodynamically stable acute phase of SAH, cardiomyopathy is characterized by diffuse and heterogeneous fluorine-18-fluorodeoxyglucose (¹⁸F-FDG) uptake and abnormal iodine-123-metaiodobenzylguanidine (¹²³I-MIBG) uptake (heart to mediastinal (H/M) average count ratio <1.75) in contrast to myocardial perfusion which appears normal. The topography and extent of metabolic defects and innervation abnormalities were largely overlapped, pointing to the conclusion that metabolic shifts occurred secondarily to neurocardiogenic injury rather than myocardial ischemia [8].

Takotsubo cardiomyopathy (TTC) is a type of NSC. Takotsubo cardiomyopathy for years was considered to affect only Asians but in 2003, the first study of TTC in Caucasians revealed that has a widespread distribution [9]. Massive catecholamine release and increased cardiac sympathetic activity are the main pathophysiological facets of TTC [10]. The main clinical manifestation is transient reversible, systolic LV dysfunction. Overall, 90% of patients with TTC are women, mainly postmenopausal [11]. Takotsubo cardiomyopathy is often misdiagnosed, as an acute coronary syndrome (ACS). This is because the symptoms of TTC are very similar to ACS however, a TTC episode can occur without any cardiac symptoms. Contrary to ACS, the coronary arteries are typically non-obstructed. Furthermore, cardiac arrest, arrhythmias and cardiogenic shock are observed less frequently. A characteristic clinical point of reference in TTC is a preceding intense physical or emotional event [12]. In the acute phase of TTC, myocardial perfusion imaging studies often demonstrate a resting defect with associated systolic LV dysfunction. Normalization of perfusion and left ventricle ejection fraction (LVEF) occurs after 1-3 months [13,14]. Other studies which suggested a catecholamine induced metabolic disorder as the main factor of TTC, demonstrated reduced ¹⁸F-FDG uptake in the apical region of the LV that is disproportional to the minimal reduction of perfusion in the same region [12]. In the acute phase of TTC, positron emission tomography (PET) studies have demonstrated reduced myocardial blood flow (MBF) and coronary flow reserve (CFR) (Figure 1) [13, 15], whilst others, normal hyperaemic flow response to vasodilation in the apical regions with compensatory increase in the basal segments [15]. Studies with ¹²³I-MIBG showed diffusely reduced myocardial uptake and increased tracer washout indicating impaired

sympathetic neuronal function and increased sympathetic activity, respectively [16].

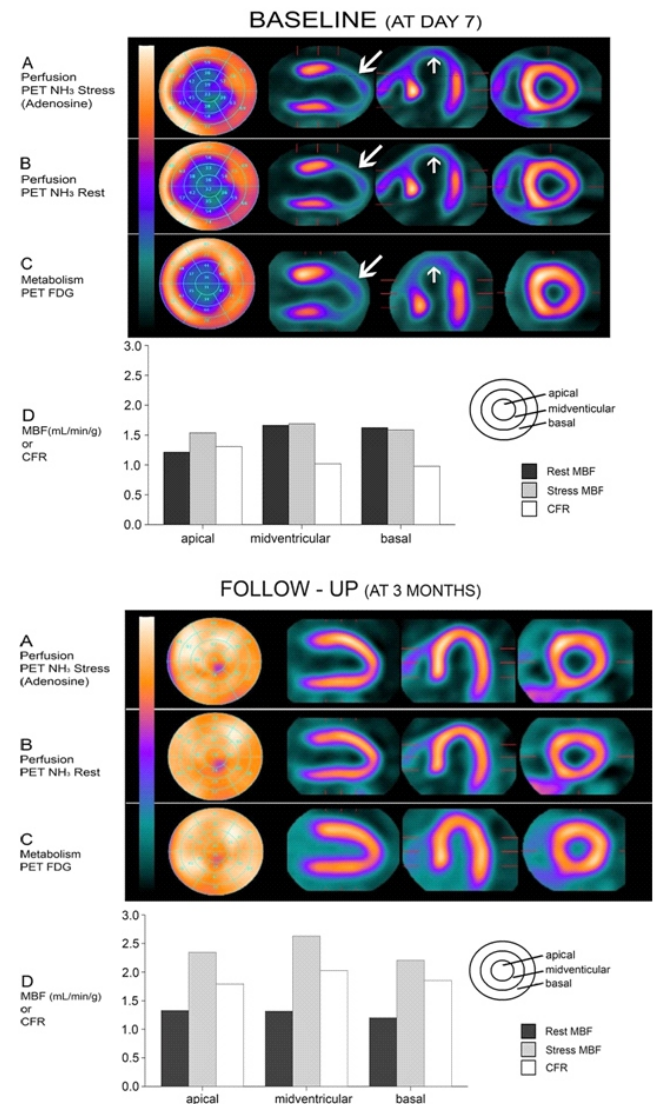


Figure 1. A combined perfusion/metabolism positron emission tomography (PET) study in a patient with Takotsubo cardiomyopathy at the initial phase and 3 months later. Perfusion baseline study shows an extensive area of decreased tracer uptake in the apex and mid-ventricular segments without reversibility during stress test and a congruent defect on fluorine-18-fluorodeoxyglucose PET study. Hyperaemic myocardial blood flow and coronary flow reserve were globally reduced in the apical, mid ventricular and basal segments of the left ventricle. Three months later full recovery was observed. "Reproduced from [Ghadri JR, Ruschitzka F, Lusher TF, Templin C. Takotsubo cardiomyopathy: still much more to learn. Heart 2014; 100: 1804-12] with permission from BMJ Publishing Group Ltd."

Intracranial atherosclerosis

Intracranial atherosclerosis is a major cause of stroke worldwide but little is known about its relationship with occult coronary artery disease (CAD). Arenillas et al. (2005) studied 65 first-ever transient ischemic attack or ischemic stroke patients (mean age 64.7±8.2) with intracranial stenoses and absence of known CAD. Hypertension was present in 73.8% of patients. More than 50% of these patients

have demonstrated myocardial perfusion defects on stress-rest single photon emission tomography (SPET) suggesting occult CAD. Anterior, septal or apical defects were present in 26% and inferior or lateral wall abnormalities in 74% of these patients. The frequency of myocardial ischemia depending on the location of the symptomatic intracranial stenosis was as follows: 75% when the vertebrobasilar arteries were involved vs. 62,5% and 35% in case of involvement of the intracranial internal carotid artery (ICA) and middle cerebral artery (MCA) respectively. In patients with symptomatic MCA or vertebrobasilar stenoses, the coexistence of an asymptomatic intracranial (ICA) stenosis implied a significant increase in the probability of silent myocardial ischemia. The maximum risk (100%) was observed for those patients with symptomatic vertebrobasilar stenosis and coexistent asymptomatic intracranial ICA stenosis [17].

Epilepsy

Seizures may affect cardiac function with consequences as arterial hypertension, cardiomyocyte damage, severe arrhythmias or sudden unexpected death in epilepsy patients (SUDEP) [18]. Seizures can cause transient LV systolic dysfunction. Most cases of SUDEP may occur during the seizure activity [19]. Temporal lobe epilepsy (TLE) appears to be related with sympathetic hyperfunction, cardiovascular autonomic dysregulation and cardiac arrhythmias. Hilz MJ et al. (2003) using ^{123}I -MIBG SPET investigated in TLE patients the relationship between the outcome of epilepsy surgery and that of autonomic function. They reported that TLE patients have had an increased sympathetic modulation and impaired ^{123}I -MIBG uptake. The latter did not change significantly in patients with good outcome, but it decreased further after surgery ($P < 0.05$) in patients with persistent seizures indicating that such patients are at an increased risk of arrhythmias and risk of sudden death [20]. In another study, Druschky et al. (2001) have assessed the possible effects on autonomic function of carbamazepine (CBZ), a medication used primarily for the treatment of epilepsy and neuropathic pain. Iodine-123-MIBG uptake was compared in 11 TLE patients on CBZ, 11 patients off CBZ and 16 healthy controls. The late H/M ratio of ^{123}I -MIBG uptake in TLE patients was not significantly different (1.88 vs. 1.75, $P = 0.9$) between subgroups with and without CBZ treatment, indicating a lack of short-term effect of CBZ on post-ganglionic sympathetic cardiac innervation. However, in consistence with similar studies in the literature, the H/M ratio was significantly lower in chronic TLE patients compared to controls (1.75 vs. 2.14, $P = 0.001$), indicating sympathetic cardiac dysfunction and increased risk of cardiac instability and arrhythmias [21].

Neurodegenerative disease

Several studies have demonstrated that Idiopathic Parkinson's disease (IPD) is related with multiple autonomic complications, as cardiac postganglionic presynaptic sympathetic denervation [22]. Wong et al. (2012) examined with ^{11}C hydroxyephedrine-PET whether cardiac sympathetic denervation in IPD affects the LV in a clear regional pattern as oppose to a more global pattern. They have shown that

cardiac sympathetic denervation in IPD is extensive, and affects most patients at an early disease stage. In addition, they have demonstrated the existence of a characteristic segmental pattern of cardiac sympathetic denervation that prevails and involves the proximal lateral LV wall most severely, with relative sparing of the anterior and proximal septal walls [23]. In a different study on Parkinson's disease (PD), Chung et al. (2011) using ^{123}I -MIBG analyzed the relationship between uptake and clinical characteristics of patients with different subtypes: [akinetic rigid (ART), mixed (MT) and tremor dominant (TDT)]. The ^{123}I -MIBG uptake values differed significantly between the ART and TDT subtypes. Additionally, the ^{123}I -MIBG uptake was inversely correlated with the severity of hypokinesia in the ART subtype ($r = -0.75$; $P = 0.01$) and the MT subtype ($r = -0.8$; $P = 0.02$) but it wasn't correlated with the severity of any of the parkinsonian symptoms in the TDT subtype. They concluded that hypokinesia is strongly associated with sympathetic myocardial degeneration and that the latter can identify the progression of the disease in patients with the ART and MT subtypes of PD [24].

Multiple system atrophy (MSA) is defined as an adult-onset, rapidly progressive, multisystem, neurodegenerative fatal disease of undetermined aetiology, characterized clinically by varying severity of parkinsonian features, cerebellar, autonomic, urogenital dysfunction and corticospinal disorders. Autonomic failure is present both in MSA and in PD [25]. Although the clinical presentation of dysautonomia in these two disorders may overlap, the mechanisms of autonomic nervous system dysfunction seem to be different [26]. Courbon et al. (2003) based on the hypothesis that postganglionic sympathetic denervation of the heart is an indicator for PD, demonstrated that cardiac ^{123}I -MIBG SPET pattern can differentiate PD from MSA. They analyzed ^{123}I -MIBG myocardial uptake in 8 PD patients with normal autonomic testing, 10 PD patients with abnormal autonomic testing and 10 MSA patients. Both planar and SPET studies were performed. Global ^{123}I -MIBG myocardial uptake was assessed as H/M ratio, whilst regional uptake was determined by SPET. The mean H/M ratios of MSA patients were higher compared to PD groups and in addition, PD patients with normal autonomic testing had significantly higher H/M than PD patients with abnormal autonomic testing (2.52 ± 0.60 vs. 1.83 ± 0.50 vs. 1.24 ± 0.40 , respectively, $P < 0.0001$). Moreover, in patients with MSA or PD and normal autonomic testing, ^{123}I -MIBG uptake was analyzed in five regions of the LV: anterior wall, inferior wall, septum, lateral wall and apex. Compared to MSA, PD patients showed a regional reduction in uptake in all regions particularly at the apex and the inferior wall. These results illustrate that ^{123}I -MIBG SPET is a sensitive test for early diagnosis of silent autonomic dysfunction [27] in PD patients.

Idiopathic rapid eye movement (REM) sleep behavior disease (RBD) is believed to be an early phase of neurodegenerative diseases such as PD. A markedly reduced cardiac ^{123}I -MIBG uptake, such as seeing in PD, is characteristic in idiopathic RBD and it is associated with the loss of sympathetic terminals. The latter supports the hypothesis that idiopathic RBD in older patients is a premotor manifestation of Lewy bo-

dies disease (LBD) [28]. Lewy body disease is the second most common cause of dementia after Alzheimer's disease with difficult differential diagnosis from other neurodegenerative diseases [29]. It has an accelerated progression that worsens after an incorrect treatment. Cardiac ¹²³I-MIBG imaging can help early clinical confirmation or exclusion of LBD. A H/M cut off point of 1.36 has been reported to differentiate LBD from the other dementias with sensitivity and specificity of 94% and 96% respectively [30].

In conclusion, involvement of the cardiovascular system occurs frequently in many neurological disorders, and there is a growing interest in an in depth understanding of the brain-heart cross talk. Recent studies (mostly of modest size) in patients with neurological problems have been focusing on unraveling underlying pathophysiology and identifying at an early stage patients at risk of developing cardiac events. In this setting, nuclear medicine techniques may have an important role, however, their precise contribution in management decisions and cost-effectiveness have yet to be determined in larger prospective studies.

Bibliography

1. Ay H, Koreshtez WJ, Benner T et al. Neuroanatomic correlates of stroke-related myocardial injury. *Neurology* 2006; 66: 1325-9.
2. Cheung RT, Hachinski VC, Cechetto DF. Cardiovascular response to stress after middle cerebral artery occlusion in rats. *Brain Res* 1997; 747: 181-8.
3. Furlan JC, Fehlings MG. Cardiovascular complications after acute spinal cord injury: pathophysiology, diagnosis and management. *Neurosurg Focus* 2008; 25: E13.
4. Cote JH. Landmarks in understanding the central nervous control of the cardiovascular system. *Exp Physiol* 2007; 92: 3-18.
5. Dombrowski K, Laskowitz D. Cardiovascular manifestations of neurologic disease. Handbook of clinical Neurology, Neurologic aspects of systemic disease, Part 1. *Elsevier* 2014; 119: 1-17.
6. Mazzeo AT, Micalizzi A, Mascia L et al. Brain-heart crosstalk: the many faces of stress-related cardiomyopathy syndromes in anaesthesia and intensive care. *Br J Anaesth* 2014; 112: 803-15.
7. Papanikolaou J, Makris D, Zakyntinos E. The role of nuclear cardiac imaging in redefining neurogenic stunned myocardium in subarachnoid hemorrhage: a deeper look into the heart. *Crit Care* 2014; 18: 490.
8. Prunet B, Basely M, D'Aranda E et al. Impairment of cardiac metabolism and sympathetic innervation after aneurysmal subarachnoid hemorrhage: a nuclear medicine imaging study. *Crit Care* 2014; 18: R131
9. Desmet WJ, Adriaenssens BF, Dens JA. Apical ballooning of the left ventricle: first series in white patients. *Heart* 2003; 89: 1027-31.
10. Chen W, Dilsizian V. Cardiac sympathetic disturbance in Takotsubo cardiomyopathy. *JACC Cardiovasc Imaging* 2016; 9: 991-3.
11. Schneider B, Athanasiadis A, Stollberger C et al. Gender differences in the manifestation of takotsubo cardiomyopathy. *Int J Cardiol* 2013; 166: 584-8.
12. Ghadri JR, Ruschitzka F, Lüscher TF, Templin C. Takotsubo cardiomyopathy: still much more to learn. *Heart* 2014; 100: 1804-12.
13. Ghadri JR, Saguner AM, Templin C et al. [CME ECG 42. Chest pain. Takotsubo cardiomyopathy]. *Praxis (Bern 1994)* 2013; 102: 1207-9.
14. Hurst RT, Prasad A, Askew JW III et al. Takotsubo cardiomyopathy: a unique cardiomyopathy with variable ventricular morphology. *JACC Cardiovasc Imaging* 2010; 3: 641-9.
15. Christensen TE, Ahtarovski KA, Bang LE et al. Basal hyperaemia is the primary abnormality of perfusion in Takotsubo cardiomyopathy: a quantitative cardiac perfusion positron emission tomography study. *Eur Heart J Cardiovasc Imaging* 2015; 16: 1162-9.
16. Verberne HJ, van der Heijden DJ, van Eck-Smit BL, Somsen GA. Persisting myocardial sympathetic dysfunction in Takotsubo cardiomyopathy. *J Nucl Cardiol* 2009; 16: 321-4.
17. Arenillas JF, Candel-Riera J, Romero-Farina G et al. Silent myocardial ischemia in patients with symptomatic intracranial atherosclerosis. *Stroke* 2005; 36: 1201-6.
18. Finsterer J, Wahbi K. CNS-disease affecting the heart: brain-heart disorders. *J Neurol Sci* 2014; 345: 8-14.
19. Al-Najafi S, Rosman H. Seizure-Induced Myocardial Stunning: A possible Cardiac Link to Sudden Unexpected Death in Epilepsy (SUDEP). *Seizure* 2015; 24: 137-9.
20. Hilz MJ, Platsch G, Druschky K et al. Outcome of epilepsy surgery correlate with sympathetic modulation and neuroimaging of the heart. *J Neurol Sci* 2003; 216: 153-62.
21. Druschky A, Hilz MJ, Hopp P et al. Interictal cardiac autonomic dysfunction in temporal lobe epilepsy demonstrated by [¹²³I]metaiodobenzylguanidine-SPECT. *Brain* 2001; 124: 2372-82
22. Goldstein DS. Imaging of the autonomic nervous system: focus on cardiac sympathetic innervations. *Semin Neurol* 2003; 32: 423-33.
23. Wong KK, Raffel DM, Koeppe RA et al. Pattern of cardiac sympathetic denervation in idiopathic Parkinson disease studied with ¹¹C hydroxyephedrine PET. *Radiology* 2012; 265: 240-7.
24. Chung EJ, Kim EG, Kim MS et al. Differences in myocardial sympathetic degeneration and the clinical features of the subtypes of Parkinson's disease. *J Clin Neurosci* 2011; 18: 922-5.
25. Gilman S, Low P, Quinn N et al. Consensus statement on the diagnosis of multiple system atrophy. American Autonomic Society and American Academy of Neurology. *Clin Auton Res* 1998; 8: 359-62.
26. Senard JM, Valet P, Durrieu G et al. Adrenergic supersensitivity in parkinsonians with orthostatic hypotension. *Eur J Clin Invest* 1990; 20: 613-9.
27. Courbon F, Brefel-Courbon C, Thalamas C et al. Cardiac MIBG scintigraphy is a sensitive tool for detecting cardiac sympathetic denervation in Parkinson's disease. *Mov Disord* 2003; 18: 890-7.
28. Miyamoto T, Miyamoto M, Inoue Y et al. Reduced cardiac ¹²³I-MIBG scintigraphy in idiopathic REM sleep behavior disorder. *Neurology* 2006; 67: 2236-8.
29. McKeith IG, Mintzer J, Aarsland D et al. Dementia with Lewy bodies. *Lancet Neurol* 2004; 3: 19-28.
30. Estorch M, Camacho V, Paredes P et al. Cardiac ¹²³I-metaiodobenzylguanidine imaging allows early identification of dementia with Lewy bodies during life. *Eur J Nucl Med Mol Imaging* 2008; 35: 1636-41.