

Clinical value of radionuclide small intestine transit time measurement combined with lactulose hydrogen breath test for the diagnosis of bacterial overgrowth in irritable bowel syndrome

Yanli Ning¹ MSc,
Cen Lou² MSc,
Zhongke Huang² MSc,
Dongfang Chen¹ MSc,
Huacheng Huang² MB,
Liang Chen² MB,
Bucheng Zhang² MB,
Ning Dai³ MD,
Jianmin Zhao³ MD,
Xia Zhen³ MD

1. Department of Nuclear Medicine,
Hangzhou Xiasha Hospital,
Hangzhou 310016, Zhejiang,
P.R.China

2. Department of Nuclear Medicine,
Sir Run Run Shaw Hospital,
Affiliated to School of Medicine,
Zhejiang University, Hangzhou
310016, Zhejiang, P.R.China

3. Department of Gastroenterology,
Sir Run Run Shaw Hospital,
Affiliated to School of Medicine,
Zhejiang University, Hangzhou
310016, Zhejiang, P.R.China

Keywords: Irritable bowel
syndrome - Small intestinal
bacterial overgrowth
- Lactulose hydrogen breath test
- Small intestinal transit time

Corresponding author:

Cen Lou, MSc,
Department of Nuclear Medicine,
Sir Run Run Shaw Hospital,
Affiliated to School of Medicine,
Zhejiang University, 3 Qingchun
East Road,
Hangzhou 310016, Zhejiang,
P.R.China.
Tel: 00-86-571-8600-6780;
loucen126@126.com

Received:

12 April 2016

Accepted revised:

16 June 2016

Abstract

Objective: Small intestinal bacterial overgrowth (SIBO) may be a pathogenetic factor for irritable bowel syndrome (IBS). This syndrome cannot be explained by structural abnormalities and has no specific diagnostic laboratory tests or biomarkers. We studied quantitatively and semi-quantitatively, using lactulose hydrogen breath test (LHBT), small intestinal transit time (SITT) ^{99m}Tc-diethylene triamine pentaacetic acid (^{99m}Tc-DTPA) in order to examine the mobility of small intestine as an indication of bacterial overgrowth in patients. **Subjects and Methods:** Eighty nine consecutive patients who met Rome criteria for IBS were retrospectively studied. According to the diagnostic criteria, all patients were divided into two groups: the SIBO group and the non-SIBO group. The tracer was a mixture of 10g lactulose, 37MBq ^{99m}Tc-DTPA and 100mL water. The patient drank the whole mixture during 1 min and the SITT study started immediately. The SITT and the LHBT followed every 15min for up to 3h after emptying the urine bladder. Spearman's rank correlation was applied to assess the correlation of oro-cecum transit time (OCTT) between imaging and LHBT. The semi-quantitative index between the SIBO group and the non-SIBO group was analyzed with Wilcoxon's rank sum test. If there was significant group difference, the receiver operating characteristic (ROC) curve was used. $P < 0.05$ was considered significant. **Results:** The median and inter-quartile range for OCTT for the LHBT (OCTT-L) for all patients was 90min and 60min, respectively, and 75min and 45min for OCTT for the SITT study (OCTT-i). There was positive correlation between OCTT-L and OCTT-i at the 0.05 level ($R = 0.290$, $P = 0.000$). There were no differences in OCTT-i and in the rate of radioactivity (counts of regions of interest ROI) over the abdomen between the SIBO group and the non-SIBO group ($P = 0.116$ and 0.290). There were significant differences in the temporal association of the hydrogen (H_2) value with OCTT-i (H_2 -i) and OCTT-L between the two groups ($P = 0.000$ and 0.000). The areas under the curve (AUC) of H_2 -i and OCTT-L were 0.749 and 0.138 respectively. **Conclusion:** Small intestinal transit time study using a lactulose hydrogen breath test and ^{99m}Tc-DTPA is a real-time test for SIBO in IBS patients and can be used as an indicator of the disease.

Hell J Nucl Med 2016; 19(2): 124-129

Epub ahead of print: 22 June 2016

Published online: 2 August 2016

Introduction

According to Rome diagnostic criteria [1, 2] irritable bowel syndrome (IBS) is defined as a syndrome with recurrent abdominal pain or discomfort occurring at least 3d per month over a 3 months period. This syndrome is a prevalent functional gastrointestinal disorder. The diagnosis of IBS is based on clinical history, on manifested symptoms and on careful physical examination [3]. A recent study showed a prevalence ranging from 5% to 15% [3]. On medical practice based upon stool consistency, the diagnosis of IBS is further categorized with either constipation (IBS-C), diarrhea (IBS-D), mixed with alternating constipation and diarrhea (IBS-M) or as undefined (IBS-U) [4]. This syndrome cannot be explained by structural abnormalities and there is no diagnostic specific laboratory test or biomarker for it.

Over the last few years, many researches have studied the pathogenesis of IBS [5-9] focusing on psychological stress, visceral hypersensitivity, brain-gut interaction, inflammation, genetic and immunological factors, dietary and other factors. The pathophysiology of IBS is complex, not completely understood [9], and this makes treatment difficult.

In recent years, the intestinal microbiota is assumed to be an important predisposition factor for IBS [10]. Some researches implicated that small intestinal bacterial overgrowth (SIBO) might be a pathogenic factor of IBS [11-14]. Studies showed that the frequency of SIBO among patients with IBS varied from 4% to 78% [14] although the impact on IBS

remains contentious. Small intestine bacterial overgrowth is currently defined as the presence of bacteria in excess of 10^5 colony forming units per milliliter on a culture of upper gut aspirate [15, 16]. This is an invasive test, so noninvasive methods including lactulose and glucose hydrogen breath tests (LHBT and GHBT) and especially LHBT have been used to diagnose SIBO [13, 15, 17]. The principle of LHBT is to detect hydrogen or methane gas produced by bacterial fermentation of unabsorbed intestinal lactulose excreted by breath [18]. Because of relative changes that occur in orocecum transit time (OCTT), LHBT is not standardized and thus difficult to be used as a diagnostic criterion for IBS [19]. Instead monitoring lactulose transit time becomes an easier and quite important test.

In nuclear medicine, the small intestinal transit time (SITT) study has been widely carried out for examining the movement function of small intestine [20]. Some scholars have proposed that radionuclides can be used to monitor lactulose transit [13, 20], but just a few studies have been reported on this issue [17, 20]. The aim of the present study was to study the clinical value of SITT with technetium-99m-diethylene triamine pentaacetic acid (^{99m}Tc -DTPA) for diagnosing SIBO in IBS patients on the basis of LHBT, including qualitative and semi-quantitative evaluation. This study could provide clinical evidence for eliminating the effect of OCTT on LHBT and for reducing false positive LHBT results.

Patients and Methods

This study was approved by the ethical committee of Sir Run Run Shaw Hospital (Reference number 20070823-2) and all patients signed an informed consent for this study.

Patients

Eighty nine consecutive patients who met Rome criteria for IBS [1, 2] were studied. All patients had no alarm symptoms and no evidence of relevant organic disease on colonoscopy, routine blood tests or fecal microbiology. The relevant organic diseases included tumor, infection, autoimmune disease and inflammatory bowel disease. No patient had received antibiotics in the previous four weeks and any prokinetic agents in the previous week. The inclusion criteria were considered and basic information of all patients was received by the doctors from the department of gastroenterology.

Small intestinal transit time study and LHBT

To minimize basal hydrogen excretion, all patients were asked to fast at least 12 hours before and during the test, avoiding foods containing incompletely absorbed carbohydrates on the previous evening, such as bread, pasta, corn, garlic, shallot, potatoes and other [21]. Extra-intestinal factors influencing breath hydrogen (H_2) concentration, such as cigarette smoking, physical exercise and hyperventilation, were also avoided during the test [22].

The tracer was in a mixture of 10g lactulose containing 15mL Duphalac, (Solvay Pharmaceuticals B.V., Weesp, The

Netherlands) and 0.5mL, 37MBq of ^{99m}Tc -DTPA, with radiochemical purity above 95% (HTA Company Ltd, Beijing, China) and 100mL water [13, 23]. The H_2 breath concentration of the end-expiratory breath sample was measured by a portable analyzer with sensitivity of $\pm 1\text{ppm}$ (Micro H_2 Meter; Micro Medical Limited, Basingstoke, UK) by the doctors from the department of gastroenterology. Dual head single photon emission tomography (SPET) (Millennium VG, General Electric, Milwaukee, WI, USA) was used for the SITT study. The planar image of the abdomen was acquired for all patients, with low-energy high-resolution collimators, 2.0 zoom, 256 \times 256 matrix and supine position of the patient for 1 min.

Before the examination, the patient used 30mL of anti-septic mouthwash (1.5% compound borax solution; Winguidehp, Shanghai, China) to eliminate lactulose fermentation by oropharyngeal bacteria. The baseline H_2 breath concentration was measured three times. Then the patient drank the whole mixture during 1 min and SITT was measured immediately, then LHBT was measured and both every 15min for up to 3h after emptying the urine bladder.

After processing by Xeleris 3 Function Imaging Workstation, the images of ^{99m}Tc -DTPA were reviewed with qualitative and semi-quantitative analysis, in a blinded manner, by two nuclear medicine doctors independently. The qualitative results aimed to locate cecum and to provide diagnosis of SIBO in IBS patients. The semi-quantitative results aimed to record OCTT of the SITT study (OCTT-i, $\geq 10\%$ of the administered dose), to record the temporal association of H_2 value (H_2 -i), to delineate the region of interest (ROI) of the cecum and to calculate the rate (R) of counts of the ROI over the abdomen in anterior imaging [24]. The OCTT of LHBT (OCTT-L) was the time of initial rise of the concentration of H_2 (involving at least two consecutive values $\geq 5\text{ppm}$ above baseline).

Diagnostic criterion

The diagnostic criterion of SIBO was based on the results of Miller MA's research [25], which was the time of initial H_2 rise (involving at least two consecutive measurements of $\geq 5\text{ppm}$ above baseline) commenced at least 15min before an increase in radioactivity ($\geq 10\%$ of the administered dose) in the cecum region. This criterion has also been accepted by J. Zhao et al. (2014) [13].

Statistical analysis

All semi-quantitative results were expressed as mean \pm SD. Since these results were not conformed to the normal distribution, were expressed by median and inter-quartile range. For all patients, Spearman's rank correlation was applied to assess the correlation of OCTT-i and OCTT-L. The OCTT-i, R, H_2 -i and OCTT-L between SIBO group and non-SIBO group were analyzed with Walloon's rank sum test. For OCTT-i, R, H_2 -i or OCTT-L, if there was significant difference, the receiver operating characteristic (ROC) curve was established. $P < 0.05$ was considered significant.

Results

Basic information

A total of 89 patients with IBS (47 males, 42 females, average age 45.75 ± 12.94 years) were studied. Their body mass index (BMI) was 22.10 ± 5.80 . The proportions of IBS-D, IBS-M, IBS-C and IBS-U were 70.78% (63/89), 23.60% (21/89), 3.37% (3/89) and 2.25% (2/89), respectively. According to the diagnostic criteria, all patients were divided into two groups: the SIBO group (21 males, 14 females, average age 43.49 ± 12.53 years) and the non-SIBO group (26 males, 28 females, average age 47.20 ± 13.10 years), Table 1, Figure 1. Patients in both groups had similar age and sex (Table 1), but with significant differences in body mass index (BMI) ($P < 0.05$). The positive rate of SIBO in IBS patients was 39.33% (35/89).

Table 1. Baseline demographic factors of IBS patients in the two groups

Characteristics	SIBO group (n=35)	Non-SIBO group (n=54)	P value
Age (years), mean \pm SD	43.49 ± 12.53	47.20 ± 13.10	0.290
Gender: male/female	21/14	26/28	0.274
BMI	24.17 ± 6.84	19.79 ± 3.04	0.000

BMI: body mass index

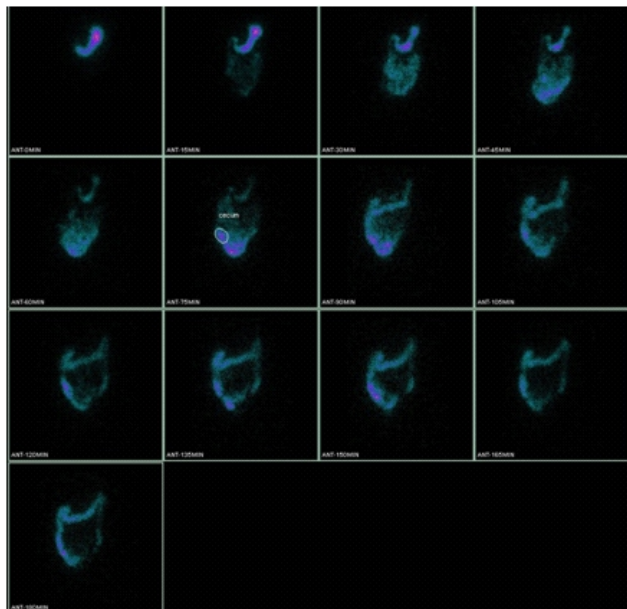


Figure 1. The image of small intestinal transit time study (white line was the ROI of the cecum). This was the image of a female, 44 years old, an IBS-D patient without SIBO. The OCTT-i was 75min and H_2 -i was 0ppm, the OCTT-L was 90min and the temporal association of H_2 value was 12ppm.

Spearman's rank correlation of OCTT-i and OCTT-L for all patients

The median and inter-quartile range of OCTT-L for all

patients was 90min and 60min, respectively, of which 75min and 45min referred to OCTT-i. There was a positive correlation between OCTT-i and OCTT-L at the 0.05 level (Figure 2).

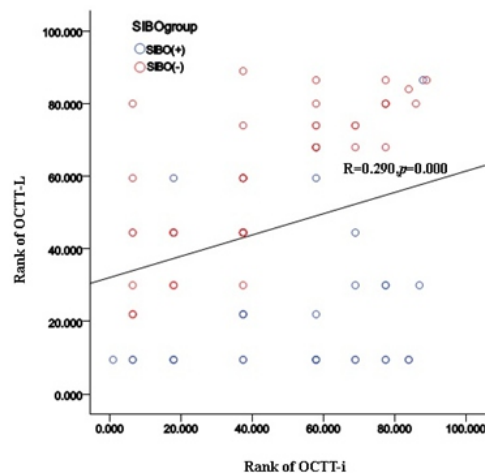


Figure 2. Correlation between OCTT-i and OCTT-L for all patients. There was positive correlation between OCTT-i and OCTT-L at the 0.05 level ($R=0.290$).

Wilcoxon's rank sum test between the two groups

Comparison among the two groups was studied with Wilcoxon's rank sum test. The mean ranks of OCTT-i, H_2 -i, and R in 24h and of OCTT-L for both groups are presented in Table 2. There were no differences in OCTT-i and R in 24h between the SIBO group and the non-SIBO group ($P=0.116$ and 0.290). There were significant differences in H_2 -i and OCTT-L between the two groups ($P=0.000$ and 0.000).

ROC curve of H_2 -i and OCTT-L

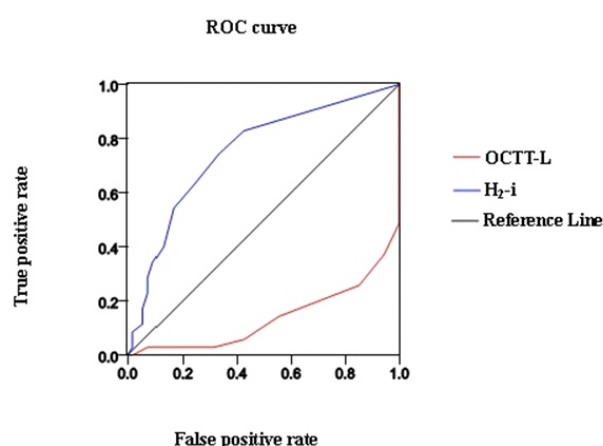
Because there were significant differences in H_2 -i and OCTT-L between the two groups, ROC curves were delineated to evaluate the diagnostic values of H_2 -i and OCTT-L for SIBO in IBS patients (Figure 3). The AUC of H_2 -i and OCTT-L were 0.749 ($P=0.000$) and 0.138 ($P=0.000$), respectively. Best H_2 -i was 5.5ppm.

Discussion

In recent years, some researches suggested that SIBO might be an important pathogenic factor for IBS, which could be verified by therapy with antibiotics [26-28]. In clinic, several methods have been used for the diagnosis of SIBO, including LHBT, GHBT, ^{14}C xylose breath test (XBT) and quantitative culture of jejunal aspirate [29, 30]. Anyhow different diagnostic methods, have been used with controversial results. Additionally, GHBT and XBT need expensive medical equipments and the quantitative culture of jejunal aspirate needs an invasive procedure, so LHBT has become an important and popular method for the diagnosis of SIBO. A limitation for LHBT is that cannot locate cecum intuitively

Table 2. The results of Wilcoxon's rank sum test

Characteristics	Mean rank of SIBO group (n=35)	Mean rank of Non-SIBO group (n=54)	z	P value
OCTT-i (min)	50.24	41.60	-1.570	0.116
H ₂ -i(ppm)	58.46	36.28	-4.113	0.000
R	41.40	47.33	-1.058	0.290
OCTT-L (min)	25.43	57.69	-5.823	0.000

**Figure 3.** The ROC curve of H₂-i and OCTT-L. The area under the curve of H₂-i (blue line) was 0.749, which offered more value to diagnosis.

and can be influenced by intestinal transit function, diets, posture, drugs etc [13, 24, 31]. The study of Miller MA et al. demonstrated that lactulose could accelerate the small bowel transit in normal subjects [25], that could generate false positive results for the diagnosis of SIBO. The abnormal rise in H₂ measured by LHBT could also be explained by variations in OCTT in patients with IBS [17], which could not support the diagnosis of SIBO. So, a kind of visible examination needs to be carried out simultaneously to confirm OCTT. The SITT study with the aid of a radiopharmaceutical can examine OCTT in the nuclear department, but there are few reports of this technique especially in patients with IBS. Other radiopharmaceuticals can also be used for imaging, like indium-111-DTPA, ^{99m}Tc-sulfur colloid, gallium-67 citrate etc. [24]. Due to its easy preparation storage and specificity, ^{99m}Tc-DTPA was the one most often used radiopharmaceuticals. Anyhow, variations in results exist due to different patients, agentia or patient's posture [24, 32]. At the same time, the tracer technique of the SITT study with a radionuclide can make up the shortfall of LHBT. The SITT study can locate the stomach, small intestine and colon. Furthermore, the anatomical side of the cecum can be located accurately and its ROI can be easily studied [24].

The study of Schatz RA et al. (2015) investigated patients' characteristics and the associated risk factors for developing SIBO using XBT [33]. Patients with symptoms of bloating,

abdominal pain, abdominal distension, weight loss, diarrhea, and/or constipation were involved in this study. The results showed lower BMI which was more prevalent in patients with SIBO [33]. In our study the BMI in the SIBO group was 24.17 ± 6.84 , higher than in the non-SIBO group, which was a significant difference. The potential explanation for this association could be that alterations in enteric flora had an impact on BMI. Our results were different with the outcomes of Schatz RA et al. (2015) [33], which could be explained as SIBO can cause malabsorption and weight loss. Such a study of course may be much more complex and warrants further studies.

The SITT study of detecting gastrointestinal motility has been much more often used. By comparing the radioactive distribution of cecum and the H₂ exhalation values of LHBT, the outcome can be more accurate showing the increase of H₂ exhalation values from small intestine or the colon [29]. Some studies have reported that OCTT of SITT and LHBT showed a good consistency [13, 23]. This could provide information about the location intuitively and for semi-quantitative results. Riordan SM et al. (1996) showed that when LHBT was based on the SITT study the diagnostic specificity increased to 100%, but the sensitivity was still low (38.9%) [23]. There have been several criteria for SIBO with LHBT using imaging [23, 25]. The study of Zhao J et al. (2014) showed that combined LHBT and SITT using a H₂ 5ppm cutoff (H₂ rise ≥ 5 ppm above baseline prior to the appearance of cecal) may identify a subgroup of IBS patients with SIBO [13, 25]. According to this criterion, our study presented the qualitative and semi-quantitative diagnosed value for SIBO in patients with IBS using LHBT with the SITT study.

A recent study (2015) showed a difference between IBS patients and healthy volunteers in OCTT-i [13] similarly to Gorard DA et al. (1995) [34]. Our study showed also no significant difference of OCTT-i in the two groups. This indicates that SITT is a feasible method for OCTT and can be used in the clinic to diagnose patients with IBS.

The value for localization and qualitative diagnosis for SITT has been confirmed, but the value of its semi-quantitative diagnosis needs to be further studied. At present, SITT studies were more focused on visible results of the transit time and the OCTT [24]. Imaging of SITT using SPET could not provide semi-quantitative results in this study. By delineating the ROI of the cecum, we used R as a semi-quantitative factor. Our study suggested that there was no difference in R between the two groups studied, which meant that the distribution of the radionuclide in the cecum was

similar in all patients with IBS. The reason for this could be that the image of the abdomen was taken in the supine position and that several minutes of concentration and of transit time had passed when the cecum was tested [24]. Of course, the choice of ROI could also influence the outcome of R. This meant that the examination could only be applied in the clinic as an anatomical tool with visual and real-time characteristics. Because all patients included in our study had similar OCTT-i to those of healthy volunteers, both SIBO and non-SIBO groups had also similar OCTT-i, so the diagnostic value of R might have limitations that needed further studies.

Riordan SM et al. (1996) considered that a H_2 value ≥ 10 ppm above baseline was the diagnostic criterion of SIBO [23], while other scholars estimated SIBO by using a higher baseline value of H_2 [35, 36]. Other studies showed no significant difference of H_2 peak and H_2 volumes in 24h, in the SIBO and the non-SIBO group for IBS patients and for healthy volunteers [13, 37, 38]. Furthermore, they found no direct correlation between the H_2 values and SIBO. Our study showed that H_2 -i in the SIBO group was significantly higher than in the non-SIBO group. The AUC of H_2 -i in the SIBO group was 0.749, which meant that H_2 -i could be a diagnostic indicator of SIBO with a moderate diagnostic clinical value. Best H_2 -i was 5.5ppm and could be used as an auxiliary diagnostic clinical index, indicating that when the temporal association of H_2 value with OCTT-i is more than 5.5ppm the IBS patient could be diagnosed as having SIBO. This diagnostic result needs to be supported by further clinic studies. We also observed that OCTT-L in the SIBO group was significantly faster than in the non-SIBO group and there was no difference of the OCTT-i between the two groups, which could indicate that SIBO existed in the SIBO group. The fact that the ROC curve showed an AUC of OCTT-L 0.138, which was lower than 0.5, indicated that the level of OCTT-L had not a clinical reference value. There was no discussion on this effect in our study.

In conclusion, our study confirms that the small intestinal transit time (SITT) study which is a visual and a real-time test for SIBO can be applied in IBS patients as an anatomical diagnostic tool with limited semi-quantitative value. The temporal association of H_2 with the SITT study is a diagnostic indicator of SIBO for IBS patients with a moderate clinical diagnostic value, due to the small sample of our study. There are no similar semi-quantitative results in medical literature. Future studies are warranted.

The authors declare that they have no conflicts of interest.

Bibliography

- Lee YJ, Park KS. Irritable bowel syndrome: emerging paradigm in pathophysiology. *World J Gastroenterol* 2014; 20(10): 2456-69.
- Longstreth GF, Thompson WG, Chey WD et al. Functional bowel disorders. *Gastroenterology* 2006; 130(5): 1480-91.
- Ballou SK, Keefer L. Multicultural considerations in the diagnosis and management of irritable bowel syndrome: a selective summary. *Eur J Gastroenterol Hepatol* 2013; 25(10): 1127-33.
- Good L, Rosario R, Panas R. New therapeutic option for irritable bowel syndrome: serum-derived bovine immunoglobulin. *World J Gastroenterol* 2015; 21(11): 3361-6.
- El-Salhy M. Recent developments in the pathophysiology of irritable bowel syndrome. *World J Gastroenterol* 2015; 21(25): 7621-36.
- O' Malley D. Immunomodulation of enteric neural function in irritable bowel syndrome. *World J Gastroenterol* 2015; 21(24): 7362-6.
- Cheung CK, Wu JC. Genetic polymorphism in pathogenesis of irritable bowel syndrome. *World J Gastroenterol* 2014; 20(47): 17693-8.
- Qin HY, Cheng CW, Tang XD et al. Impact of psychological stress on irritable bowel syndrome. *World J Gastroenterol* 2014; 20(39): 14126-31.
- Saha L. Irritable bowel syndrome: pathogenesis, diagnosis, treatment, and evidence-based medicine. *World J Gastroenterol* 2014; 20(22): 6759-73.
- Bull MJ, Plummer NT. Part 1: The Human Gut Microbiome in Health and Disease. *Integr Med (Encinitas)* 2014; 13(6): 17-22.
- Thompson JR. Is irritable bowel syndrome an infectious disease? *World J Gastroenterol* 2016; 22(4): 1331-4.
- Abbasi MH, Zahedi M, Darvish Moghadam S et al. Small bowel bacterial overgrowth in patients with irritable bowel syndrome: the first study in Iran. *Middle East J Dig Dis* 2015; 7(1): 36-40.
- Zhao J, Zheng X, Chu H et al. A study of the methodological and clinical validity of the combined lactulose hydrogen breath test with scintigraphic oro-cecal transit test for diagnosing small intestinal bacterial overgrowth in IBS patients. *Neurogastroenterol Motil* 2014; 26(6): 794-802.
- Ghoshal UC, Srivastava D. Irritable bowel syndrome and small intestinal bacterial overgrowth: meaningful association or unnecessary hype. *World J Gastroenterol* 2014; 20(10): 2482-91.
- Posserud I, Stotzer PO, Björnsson ES et al. Small intestinal bacterial overgrowth in patients with irritable bowel syndrome. *Gut* 2007; 56(6): 802-8.
- Ghoshal U, Ghoshal UC, Ranjan P et al. Spectrum and antibiotic sensitivity of bacteria contaminating the upper gut in patients with malabsorption syndrome from the tropics. *BMC Gastroenterol* 2003; 3: 9.
- Yu D, Cheeseman F, Vanner S. Combined oro-caecal scintigraphy and lactulose hydrogen breath testing demonstrate that breath testing detects oro-caecal transit, not small intestinal bacterial overgrowth in patients with IBS. *Gut* 2011; 60(3): 334-40.
- Rana SV, Malik A. Hydrogen breath tests in gastrointestinal diseases. *Indian J Clin Biochem* 2014; 29(4): 398-405.
- Portincasa P, Moschetta A, Baldassarre G et al. Pan-enteric dysmotility, impaired quality of life and alexithymia in a large group of patients meeting ROME II criteria for irritable bowel syndrome. *World J Gastroenterol* 2003; 9(10): 2293-9.
- Caride VJ, Prokop EK, Troncale FJ et al. Scintigraphic determination of small intestinal transit time: comparison with the hydrogen breath technique. *Gastroenterology* 1984; 86(4): 714-20.
- Pimentel M, Lembo A, Chey WD et al. Rifaximin therapy for patients with irritable bowel syndrome without constipation. *N Engl J Med* 2011; 364(1): 22-32.
- Thompson DG, Binfield P, De Belder A et al. Extra intestinal influences on exhaled breath hydrogen measurements during the investigation of gastrointestinal disease. *Gut* 1985; 26(12): 1349-52.
- Riordan SM, McIver CJ, Walker BM et al. The lactulose breath hydrogen test and small intestinal bacterial overgrowth. *Am J Gastroenterol* 1996; 91(9): 1795-803.
- Maurer AH. Gastrointestinal Motility, Part 2: Small-Bowel and Colon. *J Nucl Med Technol* 2016; 44(1): 12-8.
- Miller MA, Parkman HP, Urbain JL et al. Comparison of scintigraphy and lactulose breath hydrogen test for assessment of oro-cecal transit: lactulose accelerates small bowel transit. *Dig Dis Sci* 1997; 42(1): 10-8.
- Bae S, Lee KJ, Kim YS et al. Determination of rifaximin treatment period according to lactulose breath test values in non constipated irritable bowel syndrome subjects. *J Korean Med Sci* 2015; 30(6): 1000-6.

- 757-62.
27. Boltin D, Perets TT, Shporn E et al. Rifaximin for small intestinal bacterial overgrowth in patients without irritable bowel syndrome. *Ann Clin Microbiol Antimicrob* 2014; 13:49.
 28. Shah SC, Day LW, Somsouk M et al. Meta-analysis: antibiotic therapy for small intestinal bacterial overgrowth. *Aliment Pharmacol Ther* 2013; 38(8): 925-34.
 29. Rana SV, Bhardwaj SB. Small intestinal bacterial overgrowth. *Scand J Gastroenterol* 2008; 43(9): 1030-7.
 30. Ghoshal UC, Srivastava D, Ghoshal U et al. Breath tests in the diagnosis of small intestinal bacterial overgrowth in patients with irritable bowel syndrome in comparison with quantitative upper gut aspirate culture. *Eur J Gastroenterol Hepatol* 2014; 26(7): 753-60.
 31. Lee JM, Lee KM, Chung YY et al. Clinical significance of the glucose breath test in patients with inflammatory bowel disease. *J Gastroenterol Hepatol* 2015; 30(6):990-4.
 32. Maurer AH, Krevsky B. Whole-gut transit scintigraphy in the evaluation of small-bowel and colon transit disorders. *Semin Nucl Med* 1995; 25(4):326-38.
 33. Schatz RA, Zhang Q, Lodhia N et al. Predisposing factors for positive D-Xylose breath test for evaluation of small intestinal bacterial overgrowth: a retrospective study of 932 patients. *World J Gastroenterol* 2015; 21(15): 4574-82.
 34. Gorard DA, Libby GW, Farthing MJ. Effect of a tricyclic antidepressant on small intestinal motility in health and diarrhea-predominant irritable bowel syndrome. *Dig Dis Sci* 1995; 40(1):86-95.
 35. Corazza GR, Strocchi A, Gasbarrini G. Fasting breath hydrogen in celiac disease. *Gastroenterology* 1987; 93(1): 53-8.
 36. Perman JA, Modler S, Barr RG et al. Fasting breath hydrogen concentration: normal values and clinical application. *Gastroenterology* 1984; 87(6): 1358-63.
 37. Vernia P, Marinaro V, Argnani F et al. Self-reported milk intolerance in irritable bowel syndrome: what should we believe? *Clin Nutr* 2004; 23(5): 996-1000.
 38. King TS, Elia M, Hunter JO. Abnormal colonic fermentation in irritable bowel syndrome. *Lancet* 1998; 352(9135): 1187-9.



Ramon Casas. Syphilis, 1900. Poster, 80x34cm.
National Museum of Art Catalonia, Barcelona