

Current status and future challenges of brain imaging with ^{18}F -DOPA PET for movement disorders

Ferdinando Franco Calabria¹ MD,
Eros Calabria² MD,
Vincenzo Gangemi³ MD,
Giuseppe Lucio Cascini⁴ MD

1. Neuroimaging PET/MRI Research Unit, Institute of Molecular Bioimaging and Physiology, National Research Council, Catanzaro, IBFM CNR, Italy

2. Department of Diagnostic and Molecular Imaging, Interventional Radiology and Radiotherapy, PTV Foundation, University of Rome "Tor Vergata", Rome, Italy

3. Department of Experimental and Clinical Medicine, Nuclear Medicine Unit, Magna Graecia University, Catanzaro, Italy

4. Department of Diagnostic Imaging, Nuclear Medicine Unit, Magna Graecia University, Catanzaro, Italy

Keywords: ^{18}F -DOPA, PET/CT
- Kinetics in Parkinson's disease
- Molecular Imaging - PET/MRI
- Movement Disorders
- Parkinsonian Syndromes

Corresponding author:

Ferdinando Franco Calabria MD,
Institute of Molecular Bioimaging and Physiology, National Research Council, IBFM CNR,
Viale Europa 88100, Germaneto, Catanzaro, Italy, Tel: +39 328 3337036
ferdinandocalabria@hotmail.it

Received:

20 December 2015

Accepted revised:

27 February 2016

Abstract

Objective: Parkinson's disease (PD) is a neurodegenerative disorder (ND) due to progressive loss of dopaminergic neurons in the basal ganglia. The correct differential diagnosis of this disease with parkinsonian syndromes (PS) or with essential tremor (ET) is a diagnostic dilemma, considering that only PD is responsive to treatment with levodopa. Traditional imaging fails to diagnose PD because morphological alterations in the brain are usually detectable only at advanced stages. Single photon emission tomography (SPET) with cocaine analogues has recently been used in the early detection of PD. The fluoro-18-deoxyphenyl-alanine (^{18}F -DOPA) is a positron emission tomography (PET) tracer with selective in vivo affinity to the basal ganglia, due to the specific metabolism of substantia nigra. We assessed the effective use of ^{18}F -DOPA PET in brain imaging in order to describe the function of presynaptic disorders of PD, PS, ET and other movement disorders compared to SPET imaging and also discussed novel radiopharmaceuticals. The role of magnetic resonance imaging (MRI) was also discussed. **Conclusion:** The ^{18}F -DOPA PET imaging is still the best diagnostic tool for the diagnosis of PD and other movement disorders. Fluorine-18-FDG PET can play a role in the differential diagnosis between PD and other PS. The hybrid ^{18}F -DOPA PET/MRI seems to be able to play an important additional role in early diagnosis of the above syndromes.

Hell J Nucl Med 2016; 19(1):33-41

Epub ahead of print: 1 March 2016

Published online: 1 April 2016

Introduction

Parkinson's disease (PD) is a neurodegenerative disorder (ND) due to the progressive loss of dopaminergic neurons in the basal ganglia. Neurons in the putamen usually present the most severe impairment compared to those in caudate nucleus. Several ND such as progressive supranuclear palsy (PSP), multiple system atrophy (MSA) and corticobasal degeneration (CBD) are characterized by a complex of symptoms often mimicking PD. Essential tremor (ET) clinically may also mimic PD, because both have a predominant postural/action tremor. Differential diagnosis between PD, PS and ET can be difficult. In many cases, a middle term clinical follow-up is necessary. Almost 25% of patients with initial diagnosis of PD are postmortem diagnosed having ET [1-3].

In early stages and in monitoring changes of disease activity in PD and other ND, magnetic resonance imaging (MRI) and computed tomography (CT), are usually not diagnostic.

Parkinson's disease (PD) is associated with loss of vesicular monoamine transporter type 2 (VMAT2) and dopamine transporters (DAT) binding. This loss appears 13-17 years prior to the onset of the disease, as demonstrated by single photon emission tomography (SPET) with tracers imaging presynaptic receptors [4-7].

Single photon emission tomography with cocaine analogue receptors is used to study the integrity of dopaminergic neurons in PD. [8-9]. Other studies with fluorine-18-dihydroxy-phenylalanine (^{18}F -DOPA) gave promising results in diagnosing early stages of PD and its differential diagnosis with ET. The unique sites of physiological uptake of ^{18}F -DOPA in the brain are the basal ganglia, caudatum and putamen, due to the specific metabolism of the substantia nigra [10]. Positron emission tomography (PET) with ^{18}F -DOPA is also useful in the management of patients with other movement disorders.

We also reviewed in the literature ^{18}F -DOPA PET imaging using cocaine analogues or other

radiopharmaceuticals, with SPET or PET and also PET/MRI in diagnosing PD and other ND.

We used the 1990-2015 Medline data bases through the following keywords: ^{18}F -DOPA AND "PET" OR "PET/CT" AND "Parkinson's disease" AND/OR "essential tremor" AND/OR "movement disorders" AND/OR "progressive supranuclear palsy" AND/OR "multiple system atrophy" AND/OR "cortico-basal ganglia degeneration". Furthermore, other research data were obtained using the following keywords: ^{18}F -DOPA AND "PET" OR "PET/CT" AND ^{18}F -FDG AND/OR ^{18}F -fluoroethyltyrosine AND/OR "Datscan" AND/OR "SPET" AND/OR "MRI" AND/OR "PET/MRI".

From 1986 till mid 2015, our Medline research generated 86 papers out of which we analyzed 40 papers. The inclusion criteria were: a) The English language, b) Human studies, c) Original articles, d) Reviews, clinical trials or case reports. Twelve of these selected articles compared SPET with cocaine analogues or PET with ^{18}F -DOPA or with other radiopharmaceuticals.

The references of eight of the enrolled articles were also read for additional information concerning the synthesis of ^{18}F -DOPA. Other eleven references gave information about the physiological distribution of the tracers in the brain and the whole human body. Finally, seven references gave additional information about the future perspectives of MRI and PET/MRI for PD and ND.

Synthesis, biokinetics, physiological distribution and variants of ^{18}F -DOPA

Fluorine-18-DOPA can be synthesized by an electrophilic or nucleo-philic process. The electrophilic process uses the destannylation of ^{18}F -DOPA precursor and has become the best technique in synthesizing ^{18}F -DOPA, with fluorination of L-3-(3-hydroxy-4-pivaloyloxyphenyl)-alanine and ^{18}F -acetyl hypofluorite in acetic acid, followed by HCl hydrolysis and high-performance liquid chromatography. This has been shown to be the best routine method for the synthesis of ^{18}F -DOPA, allowing a radiochemical purity of 97% [11].

Being the precursor of L-DOPA, the ^{18}F -DOPA follows in central nervous system and in whole human body the same metabolic pathway as L-DOPA. In fact, both penetrate the cells carried by the L-type amino acid transporter 1 and 2 (LAT1 and LAT2). These transporters are enrolled in the permeability of the blood brain barrier (BBB) of ^{18}F -DOPA. Subsequently, ^{18}F -DOPA is converted to 6- ^{18}F fluorodopamine- ^{18}F -FDOPA) by the amino acid decarboxylase (AAAD) [11,12]. The tracer can be also metabolized in several perip-heral tissues by catechol-o-methyl transferase (COMT) before crossing BBB, thus reducing brain uptake. The premedi-cation of patients before tracer administration with carbi-dopa per os can reduce the COMT peripheral activity, conse-quentially enhancing availability of the ^{18}F -DOPA in the brain and its conversion to ^{18}F -FDA [13] (Figure 1).

Most centers ask patients to fast for 4-6 hours and abstain from drugs for 24 hours before tracer administration, so that

drugs shall not interfere with the uptake of the tracer. Such a drug is levodopa, which follows the same molecular pathway in crossing BBB and can thus increase the distribution volume of ^{18}F -DOPA in the brain [16]. Other such drugs are halo-peridol, reserpine [17] and entacapone [18]. Drugs that influence the function of LAT and can interfere with ^{18}F -DOPA as above are melphalan, thyroxine and baclofen [19]. On a theoretical basis, it is necessary, 24 hours before the test to abstain from taking proteins. It has been documented that some aromatic amino acids compete with ^{18}F -DOPA at the level of LAT transporters [20].

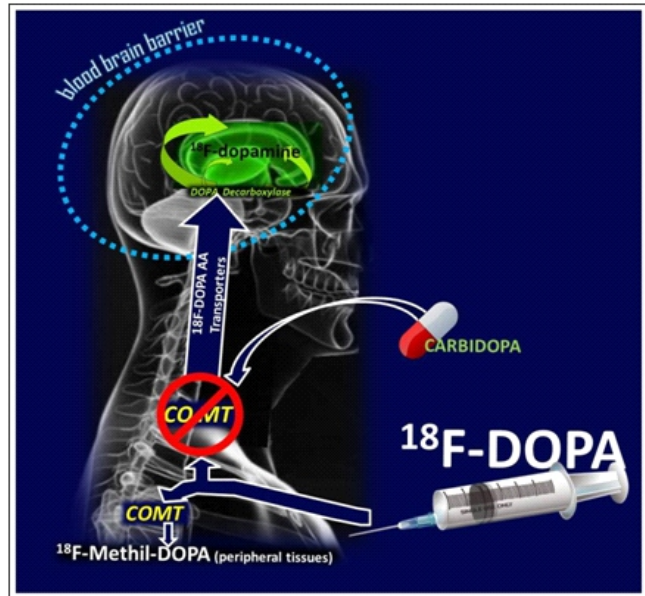


Figure 1. A diagram of premedication with carbidopa reducing the catechol-O-methyltransferase peripheral activity and enhancing availability of ^{18}F -DOPA in the brain and its conversion to ^{18}F -DOPA.

No adverse reactions have been reported, except a short, transient mild pain and/or irritation at the site of the intravenous (i.v.) administration of the radiopharmaceutical. Therefore, it appears necessary to slowly administer the tracer through a venous catheter [21].

Regarding the imaging acquisition protocol of ^{18}F -DOPA PET for semi quantitative or visual analysis, many authors suggest after tracer administration, to perform a dynamic scan at 90 min, which is considered the time of the highest uptake of the tracer in the basal ganglia [22]. Other acquisition protocols linked to brain tumor processes suggest to perform the examination 20 minutes after the administration of the tracer [23]. Considering the above, Dhawan et al. (1996) [24] suggested to exclusively use only one single point late acquisition protocol.

Whole body normal distribution of ^{18}F -DOPA mainly refers to liver, pancreas, adrenal glands, gallbladder, kidneys and urine bladder. The basal ganglia are normally visualized, while amygdala and thalamus show a minimal or negligible uptake of the tracer [25]. Concerning the excretion of the tracer, 50% of the administered radiopharmaceutical is excreted during the first hour in the urine while the rest is excreted during the next 12 hours [17,26].

Parkinson's Disease

Since 1996, several authors have shown that in PD the uptake of ^{18}F -DOPA in the basal ganglia is reduced, compared to controls [27] and that in PD patients the rate of loss of dopaminergic neurons was faster compared with controls [28]. The mean annual rate of decreased ^{18}F -DOPA up-take in PD patients was reported to be 8%-12% in the putamen and 4%-6% in the caudate while in healthy volunteers was less than 1% in both structures [27,29,30].

The uptake of ^{18}F -DOPA PET in PD was more decreased in the posterior than in the anterior putamen and the caudate indicating that during the natural history of the disease (Figure 2) putamen nuclei showed earlier involvement in respect to caudate nuclei while in healthy controls a minimal uptake difference was shown between putamen and caudate (Figure 3).

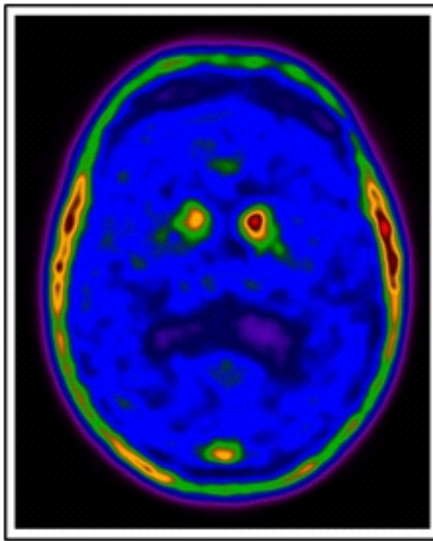


Figure 2. In a 57 years old patient with PD and predominant left side tremor, axial ^{18}F -DOPA PET view of the brain showed diffuse reduction of the uptake in both putamen and the right caudate.

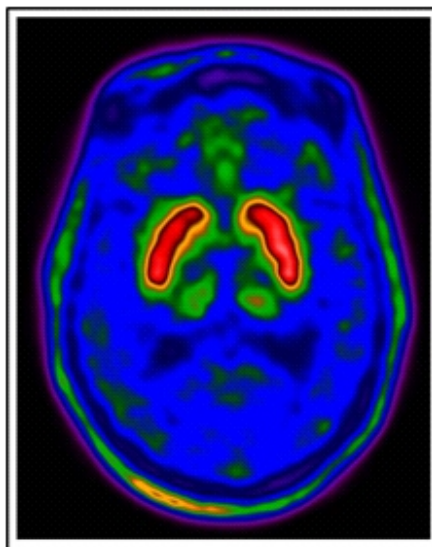


Figure 3. Axial ^{18}F -DOPA PET view of the brain showed homogeneous uptake of the tracer in the basal ganglia of a healthy 58 years old volunteer, with difference in the uptake between caudate and putamen.

Various authors in PD have demonstrated that on the contralateral to symptoms side the striatal uptake was decreased more than versus the other side [31-33]. Hilker et al. (2005) [32], using serial ^{18}F -DOPA PET in 31 PD patients, showed that ^{18}F -DOPA was extensively metabolized in the striatum and its metabolic products were retained in the striatum during imaging. This finding described in terms of a single influx constant, could be considered as irreversible, and could explain the distribution of the tracer. The ratio of the net radioactivity of the striatum, corrected for the intravascular ^{18}F -DOPA concentration from time 0 to the end of acquisition, plotted against the ratio of integrated plasma time activity and corrected for its metabolic activity [25] showed a linear correlation and reached a pseudo-equilibrium, assuming of course that there was no tracer backflux. Others reported that in PD patients the ^{18}F -DOPA PET image can be an index of the structural integrity of the nigro-striatal dopaminergic system because the decline rate of putaminal ^{18}F -DOPA inversely correlated with disease duration indicating a negatively exponential loss of dopamine nigrostriatal neurons [34]. Since ^{18}F -DOPA uptake depends on the number of functioning striatal cells, it is strictly proportional to these cell densities.

Other authors [32] studied in PD patients the decline rate of the uptake of ^{18}F -DOPA in putamen which was also found to be inversely related with disease duration suggesting a negative exponential loss of dopamine neurons in putamen. The annual disease progression rates ranged from 4.4% in the caudate to 6.3% in the putamen [32]. An average of 12% annual decline of ^{18}F -DOPA uptake in baseline putamen was reported for a group of 17 PD patients [35]. Therefore, the required sample size to show the neuro-protection by the use of ^{18}F -DOPA PET was increased according to the duration of symptoms of the patients. The above studies suggested that the neurodegenerative process in PD followed a negative exponential course and slowed down with increased duration of symptoms, contradicting the long-latency hypothesis of PD [36]. Other related papers also supported the above [33,34].

Symptoms onset and evolution of PD were also linked to disease progress, by the fact that the uptake of the tracer in the striatal body tended to decrease [27,30]. Nurmi E et al. (2001) [27] in 21 PD patients and in 8 volunteers showed that the disease process first affects the posterior and then the anterior putamen and the caudate nucleus. After the onset of PD, the absolute rate of decline of uptake of ^{18}F -DOPA was the same in all patients.

The preclinical period estimated from the decreased uptake in the posterior putamen was longer than if calculated from the anterior putamen and the caudate [30]. By ^{18}F -DOPA PET analysis, other researchers [28] showed that the preclinical period was unlikely to last more than 7 years.

On the other hand, Pal et al. (2002) [37] presented a 14 years old patient with juvenile PD, showing a severe reduction of caudate and putamen uptake, and a rostro-caudal gradient, due to rapid loss of striatal neurons. This report seemed to suggest that juvenile parkinsonism is an aggressive type of PD with a very short preclinical period while is commonly accepted

that symptoms of PD do not appear until nigral cells are lost in about 50% .

Recently, Picco et al. (2015) [39], in 15 patients with de novo PD drug-naïve and 10 patients with ET as controls, showed significantly lower uptake of ^{18}F -DOPA in striatum in PD patients than in controls, thus differentiating PD from ET patients. The main findings provided by this work were the positive correlations of statistical parametric mapping (SPM) analysis, to match the "Tallarach coordinates", that were found only in PD patients. These correlations between the executive factor studied and ^{18}F -DOPA uptake were found: a) in the bilateral anterior cingulate cortex and the middle frontal gyrus, b) between the verbal fluency factor and the uptake in bilateral striata and c) between the visuo-spatial factor and the uptake in bilateral anterior cingulate cortexes and bilateral striata. No correlations were found between the ^{18}F -DOPA uptake and either the verbal memory factor or the abstraction-working memory factor [39]. The above data explained in early PD the role of the mesocortical dopaminergic pathways in cognition and emphasized the role of the medial frontal lobe and the anterior cingulate as the main sites of cortical correlation having executive and language functions. More recently, Marinelli et al. (2015), confirmed the involvement of the orbito-frontal cortex in the development of cognitive abnormalities related to PD [40]. Since the neurodegenerative loss of striatal neurons in PD also concerns the frontal cortex through the mesocortical pathway, the above authors evaluated 16 drug naïve, newly diagnosed PD patients and 10 patients with ET, all right handed. They performed multiple-choice reaction time task, with the upper limb and underwent a ^{18}F -DOPA PET brain scan. The reaction time was shorter in PD patients and also tracer uptake was less in both striata, especially in the more affected hemisphere.

Moreover, an inverse correlation was documented between the average reaction time and the PET-assessed dopaminergic activity in the left, middle and inferior frontal gyri. Since all examined patients were right handed, this paper underlined the role of dopamine pathway in the lateral orbitofrontal cortex in early staging of PD, and suggested in the goal-directed behavior that the compensatory cortical dopamine region was related to movements preparation [40].

The last two approaches in the diagnosis of PD by using ^{18}F -DOPA uptake were strictly correlated with disease progress and with monitoring response to therapy [29].

Levodopa therapy may be neurotoxic for the remaining dopaminergic neurons. In a study on 186 patients randomized to ropinirole or levodopa therapy, ^{18}F -DOPA PET scans were performed as baseline and after 2 years of pharmacological treatment [41]. It was concluded that the administration of ropinirole compared with levodopa was associated with a relative by 30% slowing of the progression of PD as evidenced by serial ^{18}F -DOPA uptake measurements. Similar data were recorded after monitoring 21 patients who received implants of human fetal mesencephalic cells. Sixteen of these patients by using a ^{18}F -DOPA PET scan showed evidence of graft function over 6 months to 6 years of follow-up [42].

Differential diagnosis between PD and Parkinsonian Syndromes

One of the most important goals in early diagnosis and in identification of PD patients is the differential diagnosis with other PS, such as PSP, MSA and CBD, since only PD patients well respond to anti-Parkinson drugs therapy. On the other hand, in all other ND, the number of intact dopaminergic neurons is considerably decreased and on this ground ^{18}F -DOPA PET could not be useful in the differential diagnosis between all these diseases and PD. In one of the first studies on this topic, Otsuka et al. (1991) [43] investigated the ^{18}F -DOPA uptake in 10 patients with MSA and 8 patients with PD. The uptake of ^{18}F -DOPA was reduced by a similar amount in the putamen of both groups while there was a greater reduction of uptake in the caudate in MSA patients. These findings were similar to another study conducted on 28 PD and 10 PSP patients. The uptake of the tracer was reduced in both PSP and PD patients but there was a greater reduction of uptake in the caudate of PSP patients in comparison with PD patients. However, the overlapping between the two populations was too much for a meaningful differentiation [44]. Similar results were reported for CBD by several other studies which showed a similar reduction of uptake in the caudate and putamen of patients with CBD [45-47]. In a more recent study, Darcourt et al. (2014) showed that some patterns such as the asymmetrical faint homogeneous striatal uptake reduction pattern of CBD can correctly identify patients with this disease [10]. Beyond the few availability of papers on this field, an important suggestion was provided by Scherfler et al (2013) who compared healthy controls with PD patients, examining the uptake of the tracer in the striatum and in the olfactory tract. Regarding the clinical implications of Braak's hypothesis [36], which considers that the earliest signs of PD, such as hyposmia, sleep disorders and constipation may precede the motor features of the disease by several years, some researchers are increasingly focus on the "non-motor" symptoms in order to detect early PD and to slow or stop its progression. In particular, Scherfler et al (2013) found a meaningful association in PD patients between the reduction of uptake in the striatum and in the olfactory tract suggesting another criterion to distinguish between PD and other movement disorders [48].

Comparison with SPET and other imaging modalities

The SPET scan with cocaine analogues is widely used in follow-up of the management of PD, for its easy production of availability. It is also the main reference standard for evaluation of the diagnostic performance of ^{18}F -DOPA PET in the management of movement disorders. Several studies have shown the usefulness of SPET scan with dopamine receptors in the diagnosis of PD and on the comparison between the diagnostic performance of SPET and PET with ^{18}F -DOPA in the management

of patients with movement disorders [6, 42-52].

Eshuis et al. (2009) [53] studied the potential mismatches between SPET with ^{123}I -ioflupane and ^{18}F -DOPA PET in the management of patients with PD in comparison to a group of healthy volunteers: Eleven patients with early stage PD and 17 patients with advanced PD were recruited. Results were compared with those of 10 healthy volunteers submitted to SPET and other 10 volunteers submitted to PET study. Both techniques were able to discriminate PD patients from healthy controls. In particular, sensitivity and specificity in the early stage of the disease were 100% for both SPET and PET. When considering patients with advanced PD, sensitivity was 91% for both tools while specificity was 100% for SPET and 90% for PET. Following the conclusion of the above authors, both techniques could be feasible in the management of PD patients, especially in distinguishing patients with early undiagnosed PD. This important finding had been previously reported; by Ishikawa et al. (1996) [54] who evaluated 12 mildly affected PD patients studied with ^{123}I -ioflupane SPET and ^{18}F -DOPA PET. Fifteen normal volunteers served as controls for both tracers. Both tracers discriminated PD patients from controls with comparable accuracy.

In a previous study on 13 patients with de novo PD and 17 patients with advanced PD [55], performed by SPET with ^{123}I -ioflupane and PET with ^{18}F -DOPA, using a template with regions of interest to sample values of the caudate, putamen and of an occipital reference region. A good correlation between striatal ^{18}F -DOPA uptake and striatal ^{123}I -ioflupane uptake and also between putaminal ^{18}F -DOPA uptake and putaminal ^{123}I -ioflupane uptake (was found, for both correlations $P < 0.0001$). Striatal uptake of ^{123}I -ioflupane and of ^{18}F -DOPA, moderately correlated with the stage of the disease and with motor scores but were equally able to distinguish patients with advanced PD from patients with de novo PD [54]. These authors emphasized that, after the necessary premedication with carbidopa per os, they noticed a better reproducibility of ^{18}F -DOPA PET. This could be due to the shorter half-life of the tracer, the shorter time of the investigation and better resolution power of the ^{18}F -DOPA PET examination.

As a glucose analogue, the ^{18}F -FDG is widely used as a PET tracer in oncology [56], cardiology [57] and neurology [58]. Fluorine-18-FDG PET and PET/CT is well known to be used in the management of cases disease with cognitive deterioration, but it cannot easily detect the reduction of metabolism in the striatum, due to its high rate of normal distribution in normal brain structures opposite to ^{18}F -DOPA. Thus, ^{18}F -FDG can only support the diagnosis of PS, by characterizing same specific ^{18}F -FDG uptake patterns when the clinical diagnosis of PSP, MSA and CBD is uncertain [59]. Therefore, the attention of the researchers was focused on: the potential usefulness of ^{18}F -FDG PET in the differential diagnosis of PS [60], in diagnosing dementia complex associated with PD [61] or in depicting different subgroups of PD patients, rather than diagnosing PD in the early stages.

Eggers et al. (2014) [62]: investigated 64 PD patients, 32 of which had a symptomatology prevalently akinetic-rigid and 32 prevalently tremor-dominant, with ^{18}F -DOPA and ^{18}F -FDG PET. They showed a clear difference between the two

subgroups of PD patients in the ventral striatum, revealing a significantly lower cerebral rate of glucose metabolism within the ventral striatum for those patients with a symptomatology mostly akinetic-rigid in comparison with those with tremor-dominant symptomatology.

Others [61] investigated 30 patients with PD and 17 with MSA, with susceptibility-weighted imaging (SWI) and ^{18}F -FDG PET and measured the signal intensity by SWI and the standardized uptake value (SUV) of putamen nuclei. Both signal intensities and SUV significantly distinguished PD and MSA. On the ^{18}F -FDG PET study low signal intensity in the putamen correlated with hypometabolism. Comparison with ^{18}F -DOPA PET was not studied. In general, the role of ^{18}F -FDG PET in this field is limited.

Other radiopharmaceuticals being beta-emitters have been recently used to investigate patients with movement disorders. The attention of researchers has also been focused on labeling the receptors of the serotonergic effect and evaluating the serotonergic terminal function, by ^{11}C -labeled 3-amino-4-(2-dimethylaminomethylphenylsulfanyl)-benzonitrile (^{11}C -DASB) or by the dopamine releasing (^{11}C -raclopride) in levodopa-induced dyskinesias, a frequent adverse motor effect of therapy with levodopa in PD patients [63]. Another study [64] indicated that striatal serotonergic terminals contributed to the genesis of levodopa-induced dyskinesia, via aberrant processing of exogenous levodopa and via the release of dopamine as false neurotransmitter in the denervated striatum of PD patients with this adverse motor effect. Beyond this paper, to the best of our knowledge, no other data have been reported in comparison with ^{18}F -DOPA PET or in early diagnosis of PD.

Another radiopharmaceutical in the diagnosis of PD ^{18}F -fluoro-m-tyrosine (^{18}F -FMT) has been recently studied in comparison with ^{18}F -DOPA [65, 66]. Standing to the fact that ^{18}F -FMET is not a substrate for COMT, this tracer should have a better uptake-to-background ratio than ^{18}F -DOPA. Others [65] investigated the possible role of ^{18}F -FMT in diagnosing PD. Twelve patients at the early stage of PD were submitted to both ^{18}F -DOPA and ^{18}F -FMT PET brain scans. By using volumes of interest analysis, the researchers generated areas encompassing caudate, putamen and subregion of the putamen for both radiopharmaceuticals. The uptake of ^{18}F -FMT better depicted the clinical status of PD than did ^{18}F -DOPA uptake. The authors attributed this effect to the higher affinity of ^{18}F -FMT to the target, the AAAD.

The same group [66] deepened this preliminary experience by examining further 15 patients with PD by means of both ^{18}F -FET and ^{18}F -DOPA PET as well as with high resolution MRI. Using a Patlak graphical approach, (explain acronym RDI) RDI specific uptake rate constants were generated. The uptake of ^{18}F -FET was higher in extra striatal regions such as amygdala, pallidum, brainstem, hippocampus and thalamus, while the cortical uptake was similar for both tracers. They concluded that the ^{18}F -FET PET study may provide more advantages in depicting pathologic changes within allo-cortical loop structures, which may contribute to deepen the knowledge about cognitive and emotional symptoms of PD [66].

Concerning the MRI, the actual field of interest of MRI in the management of patients with movement disorders is actually limited to ensuring possible anatomical alterations

that may occur in some parkinsonian syndromes and distinguish between PD patients from other ND. Similarly, MRI may help diagnose other diseases with a prevalent clinical subset of tremor, such as vascular parkinsonism or Fahr's syndrome [67,68] or other disorders where typical anatomical alterations reflect the anatomo-pathological substrate of the disease, like PSP, MSA and CBD [44, 69]. In PD, the casual depletion of transmitters cannot be detected by this imaging modality with the accuracy of molecular imaging provided by SPET and PET radiopharmaceuticals. Nevertheless, researchers recently focused on the possible role of an integrated evaluation of PD by means of both MRI and PET [70]. The main suggestion in this field was the potential usefulness of MRI to exclude symptomatic parkinsonism due to structural basal ganglia cells loss, not by image analysis, since the loss of cells is reflected only in the advanced stage of the disease, but by diffusion-weighted and inversion recovery MRI [71] and by MR spectroscopy (MRS) [72].

Recent studies supported the usefulness of an integrated PET/MRI evaluation to ensure the diagnosis of PD by perfusion and anatomy provided by glucose metabolism of ^{18}F -FDG PET [73] or the metabolism of the striatum provided by ^{18}F -DOPA PET [74] and MRI. A better resolution a higher partial volume effect correction and an advanced head movement correction are applied in this field [75].

Discussion

It has been shown the potential usefulness of PET with ^{18}F -DOPA in diagnosing PD. As an extremely useful diagnostic tool for the non-invasive evaluation of basal ganglia pathophysiology in both patients with PD and PS, like PSP, CBD and MSA, since the semi-quantitative analysis of the uptake in the caudatum could help their differential diagnosis with PD. The limit of some cited studies was the small number of examined patients but results were very encouraging in absolute terms of sensitivity and specificity, especially when compared with SPET. The knowledge of molecular alterations in PD provided by ^{18}F -DOPA PET offered to a better identification of the disease in the pre-clinical stage and a better monitoring of disease progress and/or response to therapy. The pharmacological effects of concomitant symptomatic treatments and of neuro-protective agents on the tracer uptake still needs to be addressed and specifically the study of drugs, such as levodopa-inducing dyskinesia [63, 64, 76].

It is necessary to consider some important features related to the traditional SPET imaging: beyond the substantial similarity in terms of sensitivity and specificity between SPET scan with cocaine analogues and PET with ^{18}F -DOPA, some factors support of the last technique in the management of PD patients with predominant resting tremor, because having a better resolution limit in a shorter time acquisition protocol, it could minimize the artifacts due to the movements of the patients. Moreover, for the same reasons, although the uptake of both cocaine analogues and ^{18}F -DOPA

in the basal ganglia inversely correlates with the severity of motor signs and with the duration of PD, ^{18}F -DOPA theoretically should be associated to a lower dosimetry for the patients, although this point needs to be further studied. Finally, because the decline of DAT binding examined by SPET is also related to age and not only to disease duration, the uptake of ^{18}F -DOPA can be a better marker in the diagnosis and monitoring of PD patients.

Considering the heterogeneity of ^{18}F -DOPA PET acquisition protocols, it is necessary to consider that all main advantages could be effectively achieved only by standardizing acquisition protocols, using premedication with carbidopa and acquiring the image of the whole brain at 90 minutes after the tracer administration. Furthermore, it is necessary to standardize a unique model of quantitation of PET data [62]. Positron emission tomography radiopharmaceuticals other than ^{18}F -DOPA used for imaging in movement disorders seem to actually play a limited role in this field, with the exception of ^{18}F -FMT, showing interesting preliminary findings [65, 66] which need to be further studied.

Regarding the availability of ^{18}F -DOPA PET technology, the recent development of automated synthesis module [77] for the production of this tracer directly in the provided PET centers, helps the availability of ^{18}F -DOPA for researchers and clinicians.

Magnetic Resonance imaging is the method of choice in the management of several ND is providing high quality images with excellent anatomical information and is increasingly the preferred technique for studying both functional and structural data. Position emission tomography is still the best technique to study the "in vivo" behavior of neurotransmitters and neuroreceptors. The rapid development of hybrid PET/MRI could help to potentiate and improve the diagnostic performance of both techniques. In particular, MRI improves the placement of regions of interest in PET images, for a better quantitation of the uptake of the tracer in substantia nigra and also offers new quantitation approaches like the support vector machines (SVM), a recently developed operator-independent MR technique of quantitation that can distinguishing ET from PD patients [78], as already reported for SPET with ^{123}I -nortropane [79].

Since ET is a clinical condition involving the upper limbs, usually known as a postural tremor with or without kinetic tremor, it could be a diagnostic dilemma in the differential diagnosis with PD. The ^{18}F -DOPA PET shows a normal uptake on the striatum in patients with ET compatible with the intact nigro-striatal dopaminergic neurons while recent studies on MRI suggested a possible involvement of the cerebellum in the pathophysiology of this disease [80, 81].

Future studies are needed to verify if the combination of functional and metabolic data provided by MRI and PET using ^{18}F -DOPA can reciprocally implement their diagnostic impact in a single-step, functional and anatomical whole brain evaluation [82, 83], especially referring to ET and other PS. It is noteworthy to mention that the ^{18}F -DOPA PET is currently also employed in other diseases involving the basal ganglia or the dopaminergic system, such as epilepsy [84], detoxified alcoholism patients [85] and psychiatric disorders [86]. Since atypi-

cal Parkinsonism and other neurodegenerative diseases such as PSP, MSA and CBD do not respond to therapy with levodopa, the development of the PET/MRI scanner and new radiopharmaceuticals will considerably expand our knowledge in this field.

Acknowledgment

The Authors wish to thank their collaborators Technicians Radiologists Domenico Gullà and Federico Rocca for the special care and attention in assisting the patients.

The authors declare that they did not receive funding for this work.

The authors declare that they have no conflicts of interest

Bibliography

- Larsen TA, Calne DB. Essential tremor. *Clin Neuropharmacol*. 1983; 6: 185-206.
- Quinn N. Parkinsonism-recognition and differential diagnosis. *BMJ* 1995;310: 447-52.
- Meara J, Bhowmick BK and Hobson P. Accuracy of diagnosis in patients with presumed Parkinson's disease. *Age and Ageing* 1999;28:99-102.
- Stoessel AJ Developments in neuroimaging: positron emission tomography. *Parkinsonism Relat Disord* 2014; 20:180-3.
- Piperkova E, Georgiev R, Daskalov M et al. The brain scintiscan with iodine-123-ioflupane to diagnose early Parkinson's disease; seven months follow up. First results in Bulgaria. *Hell J Nucl Med* 2006;9:31-5.
- Filippi L, Manni C, Pierantozzi M et al. ¹²³I-FP-CIT semi-quantitative SPECT detects preclinical bilateral dopaminergic deficit in early Parkinson's disease with unilateral symptoms. *Nucl Med Commun* 2005;26:421-6.
- Schillaci O, Chiaravalloti A, Pietro BD et al. Thalamic ¹²³I FP-CIT uptake in a patient with clinical diagnosis of Parkinson's disease and depression. *Hell J Nucl Med* 2012; 15: 74-5.
- Pavese N, Kiferle L, Piccini P. Neuroprotection and imaging studies in Parkinson's disease. *Parkinsonism Relat Disord* 2009; 15:33-7.
- Brajkovic LD, Svetel MV, Kostic VS et al. Dopamine transporter imaging ¹²³I-FP-CIT (DaTSCAN) SPET in differential diagnosis of dopa-responsive dystonia and young-onset Parkinson's disease. *Hell J Nucl Med* 2012;15: 134-8.
- Darcourt J, Schiavza A, Sapin N et al. ¹⁸F-FDOPA PET for the diagnosis of parkinsonian syndromes. *Q J Nucl Med Mol Imaging* 2014;58: 355-65.
- Ishiwata K, Shinoda M, Ishii S et al. Synthesis and evaluation of an ¹⁸F-labeled dopa prodrug as a PET tracer for studying brain dopamine metabolism. *Nucl Med Biol* 1996;23: 295-301.
- Calabria F, Chiaravalloti A, Di Pietro B et al. Molecular imaging of brain tumors with ¹⁸F-DOPA PET and PET/CT. *Nucl Med Commun* 2012;33:563-70.
- Melega WP, Hoffman JM, Luxen A et al. The effects of carbidopa on the metabolism of 6-[¹⁸F]fluoro-L-dopa in rats, monkeys and humans. *Life Sci* 1990;47: 149-57.
- Chondrogiannis S, Marzola MC, Al-Nahhas A et al. Normal bio-distribution pattern and physiologic variants of ¹⁸F-DOPA PET imaging. *Nucl Med Commun* 2013;34: 1141-9.
- Calabria F, Cascini GL. Current status of ¹⁸F-DOPA PET imaging in the detection of brain tumor recurrence. *Hell J Nucl Med* 2015; 18:152-6.
- Kumakura Y, Danielsen EH, Reilhac A et al. Levodopa effect on [¹⁸F]fluorodopa influx to brain: normal volunteers and patients with Parkinson's disease. *Acta Neurol Scand* 2004; 110: 188-95.
- Taieb D, Timmers HJ, Hindie E et al. EANM 2012 guidelines for radionuclide imaging of pheochromocytoma and paraganglioma. *EJ Nucl Med Mol Imaging* 2012;39: 1977-95.
- Sawle GV, Burn DJ, Morrish PK et al. The effect of entacapone (OR-611) on brain [¹⁸F]-6-L-fluorodopa metabolism: implications for levodopa therapy of Parkinson's disease. *Neurology* 1994; 44: 1292-7.
- del Amo EM, Urtti A, Yliperttula M. Pharmacokinetic role of L-type amino acid transporters LAT1 and LAT2. *Eur J Pharm Sci* 2008;35:161-74.
- Leenders KL, Poewe WH, Palmer AJ et al. Inhibition of L-[¹⁸F]fluorodopa uptake into human brain by amino acids demonstrated by positron emission tomography. *Ann Neurol* 1986;20:258-62.
- Doudet DJ, Chan GL, Jivan S et al. Evaluation of dopaminergic presynaptic integrity: 6-[¹⁸F]fluoro-L-DOPA versus 6-[¹⁸F]fluoro-L-m-tyrosine. *J Cereb Blood Flow Metab* 1999; 19: 278-87.
- Ghaemi M, Raethjen J, Hilker R et al. Monosymptomatic resting tremor and Parkinson's disease: a multitracer positron emission tomographic study. *Mov Disord* 2002; 17: 182-8.
- Calabria F, Schillaci O. Recurrent glioma and crossed cerebellar diaschisis in a patient examined with ¹⁸F-DOPA and ¹⁸F-FDG PET/CT. *Clin Nucl Me* 2012;37:878-979.
- Dhawan V, Ishikawa T, Patlak C et al. Combined FDOPA and 3OMFD PET studies in Parkinson's disease. *J Nucl Med* 1996;37:209-16.
- Fischman AJ. Role of [¹⁸F]-dopa-PET imaging in assessing movement disorders. *Radiol Clin North Am* 2005;43:93-106.
- Bandopadhyaya G. Role of ¹⁸F-DOPA PET/CT and ¹³¹I-MIBG planar scintigraphy in evaluating patients with Pheochromocytoma. *Hell J Nucl Med Suppl* 2015; September-2 December 2015.
- Morrish PK, Sawle GV, Brooks DJ. An [¹⁸F]dopa-PET and clinical study of the rate of progression in Parkinson's disease. *Brain* 1996;119: 585-91.
- Morrish PK, Rakshi JS, Bailey DL et al. Measuring the rate of progression and estimating the preclinical period of Parkinson's disease with [¹⁸F]dopa PET. *J Neurol Neurosurg Psychiatry* 1998;64: 314-9.
- Vingerhoets FJ, Snow BJ, Lee CS et al. Longitudinal fluorodopa positron emission tomographic studies of the evolution of idiopathic parkinsonism. *Ann Neurol* 1994;36:759-64.
- Nurmi E, Ruottinen HM, Bergman J et al. Rate of progression in Parkinson's disease: a 6-[¹⁸F]fluoro-L-dopa PET study. *Mov Disord* 2001;16:608-15.
- Cropley VL, Fujita M, Bara-Jimenez W et al. Pre- and post-synaptic dopamine imaging and its relation with frontostriatal cognitive function in Parkinson disease: PET studies with [¹¹C]NNC 112 and [¹⁸F]FDOPA. *Psychiatry Res* 2008;163:171-82.
- Hilker R, Schweitzer K, Coburger S et al. Nonlinear progression of Parkinson disease as determined by serial positron emission tomographic imaging of striatal fluorodopa F 18 activity. *Arch Neurol* 2005;62:378-82.
- Sawle GV, Playford ED, Burn DJ et al. Separating Parkinson's disease from normality. Discriminant function analysis of fluorodopa F 18 positron emission tomography data. *Arch Neurol* 1994;51:237-43.
- Snow BJ, Tooyama I, McGeer EG et al. Human positron emission tomographic [¹⁸F]fluorodopa studies correlate with dopamine cell counts and levels. *Ann Neurol* 1993;34:324-30.
- Morrish PK, Sawle GV, Brooks DJ. The rate of progression of Parkinson's disease. A longitudinal [¹⁸F]DOPA PET study. *Adv Neurol* 1996;69:427-31.
- Braak H, Del Tredici K, Rüb U et al. Staging of brain pathology related to sporadic Parkinson's disease. *Neurobiol Aging* 2003; 24: 197-211.
- Pal PK, Leung J, Hedrich K et al. [¹⁸F]-Dopa positron emission tomography imaging in early-stage, non-parkin juvenile parkinson-

- ism. *Mov Disord* 2002; 17: 789-94.
38. Fearnley JM, Lees AJ. Ageing and Parkinson's disease: substantia nigra regional selectivity. *Brain* 1991; 114: 2283-301.
 39. Picco A, Morbelli S, Piccardo A, Arnaldi D et al. Brain ¹⁸F-DOPA PET and cognition in de novo Parkinson's disease. *Eur J Nucl Med Mol Imaging* 2015; 42: 1062-70.
 40. Marinelli L, Piccardo A, Mori L et al. Orbitofrontal ¹⁸F-DOPA Uptake and Movement Preparation in Parkinson's Disease. *Parkinsons Dis* 2015: 180940.
 41. Whone AL, Watts RL, Stoessl AJ et al. Slower progression of Parkinson's disease with ropinirole versus levodopa: The REAL-PET study. *Ann Neurol* 2003; 54: 93-101.
 42. Brooks DJ. The early diagnosis of Parkinson's disease. *Ann Neurol* 1998; 44: 10-8.
 43. Otsuka M, Ichiya Y, Hosokawa S et al. Striatal blood flow, glucose metabolism and ¹⁸F-dopa uptake: difference in Parkinson's disease and atypical parkinsonism. *J Neurol Neurosurg Psychiatry* 1991; 54: 898-904.
 44. Burn DJ, Sawle GV, Brooks DJ. Differential diagnosis of Parkinson's disease, multiple system atrophy, and Steele-Richardson-Olszewski syndrome: discriminant analysis of striatal ¹⁸F-dopa PET data. *J Neurol Neurosurg Psychiatry* 1994; 57: 278-584.
 45. Nagasawa H, Tanji H, Nomura H et al. PET study of cerebral glucose metabolism and fluorodopa uptake in patients with corticobasal degeneration. *J Neurol Sci* 1996; 139: 210-7.
 46. Eidelberg D, Dhawan V, Moeller JR et al. The metabolic landscape of cortico-basal ganglionic degeneration: regional asymmetries studied with positron emission tomography. *J Neurol Neurosurg Psychiatry* 1991; 54: 856-62.
 47. Sawle GV, Brooks DJ, Marsden CD et al. Corticobasal degeneration. A unique pattern of regional cortical oxygen hypometabolism and striatal fluorodopa uptake demonstrated by positron emission tomography. *Brain* 1991; 114: 541-6.
 48. Scherfler C, Esterhammer R, Nocker M et al. Correlation of dopaminergic terminal dysfunction and microstructural abnormalities of the basal ganglia and the olfactory tract in Parkinson's disease. *Brain* 2013; 136: 3028-37.
 49. Passamonti L, Salsone M, Toschi N et al. Dopamine-transporter levels drive striatal responses to apomorphine in Parkinson's disease. *Brain Behav* 2013; 3: 249-62.
 50. Gayed I, Joseph U, Fanous M et al. The impact of DaTscan in the diagnosis of Parkinson disease. *Clin Nucl Med* 2015; 40: 390-3.
 51. Labate A, Salsone M, Novellino F et al. Combined use of cardiac m-123-iodobenzylguanidine scintigraphy and ¹²³I-fp-cit single photon emission computed tomography in older adults with rapid eye movement sleep behavior disorder. *J Am Geriatr Soc* 2011; 59: 928-9.
 52. Nissen T, Malek N, Grosset KA et al. Baseline [¹²³I]FP-CIT SPECT (DaTSCAN) severity correlates with medication use at 3 years in Parkinson's disease. *Acta Neurol Scand* 2014; 129: 204-8.
 53. Eshuis SA, Jager PL, Maguire RP et al. Direct comparison of FP-CIT SPECT and F-DOPA PET in patients with Parkinson's disease and healthy controls. *Eur J Nucl Med Mol Imaging* 2009; 36: 454-62.
 54. Ishikawa T, Dhawan V, Kazumata K et al. Comparative nigrostriatal dopaminergic imaging with iodine-123-beta CIT-FP/SPECT and fluorine-18-FDOPA/PET. *J Nucl Med* 1996; 37: 1760-5.
 55. Eshuis SA, Maguire RP, Leenders KL et al. Comparison of FP-CIT SPECT with F-DOPA PET in patients with de novo and advanced Parkinson's disease. *Eur J Nucl Med Mol Imaging* 2006; 33: 200-9.
 56. Masala S, Schillaci O, Bartolucci AD et al. Metabolic and clinical assessment of efficacy of cryoablation therapy on skeletal masses by ¹⁸F-FDG positron emission tomography/computed tomography (PET/CT) and visual analogue scale (VAS): initial experience. *Skeletal Radiol* 2011; 40: 159-65.
 57. Schröter G, Schwaiger M. Assessment of myocardial vitality with FDG-PET: still research or ready for general practice? *Herz* 1995; 20: 350-3.
 58. Cerami C, Della Rosa PA, Magnani G et al. Brain metabolic maps in Mild Cognitive Impairment predict heterogeneity of progression to dementia. *Neuroimage Clin* 2014; 5: 187-94.
 59. Garraux G, Phillips C, Schrouff J et al. Multiclass classification of FDG PET scans for the distinction between Parkinson's disease and atypical parkinsonian syndromes. *Neuroimage Clin* 2013; 14: 883-93.
 60. Akdemir ÜÖ, Tokçaer AB, Karakuş A et al. Brain ¹⁸F-FDG PET imaging in the differential diagnosis of parkinsonism. *Clin Nucl Med* 39: 220-226.
 61. Yoon RG, Kim SJ, Kim HS et al. The utility of susceptibility-weighted imaging for differentiating Parkinsonism-predominant multiple system atrophy from Parkinson's disease: correlation with ¹⁸F-fluorodeoxyglucose positron-emission tomography. *Neurosci Lett* 2015; 1: 296-301.
 62. Eggers C, Schwartz F, Pedrosa DJ et al. Parkinson's disease subtypes show a specific link between dopaminergic and glucose metabolism in the striatum. *PLoS One* 2014; 21: e96629.
 63. Cerasa A, Koch G, Fasano A et al. Future scenarios for levodopa-induced dyskinesias in Parkinson's disease. *Front Neurol* 2015; 1: 76.
 64. Politis M, Wu K, Loane C et al. Serotonergic mechanisms responsible for levodopa-induced dyskinesias in Parkinson's disease patients. *J Clin Invest* 2014; 124: 1340-9.
 65. Gallagher CL, Christian BT, Holden JE et al. A within-subject comparison of 6-[¹⁸F]fluoro-m-tyrosine and 6-[¹⁸F]fluoro-L-dopa in Parkinson's disease. *Mov Disord* 2011; 26: 2032-8.
 66. Li CT, Palotti M, Holden JE et al. A dual-tracer study of extrastriatal 6-[¹⁸F]fluoro-m-tyrosine and 6-[¹⁸F]fluoro-L-dopa uptake in Parkinson's disease. *Synapse* 2014; 68: 325-31.
 67. Chevalier D, Marie I, Tillon J et al. [A cause of cerebral calcifications not to be ignored: Fahr syndrome]. *Rev Med Interne* 2005; 26: 668-70.
 68. Calabria F, Cicciariello G, Falcone C et al. A case of Fahr's disease examined by multi-modal imaging. *Eur J Nucl Med Mol Imaging* 2015; 42: 2098-9.
 69. Yoo HB, Lee JY, Lee JS et al. *J Clin Neurol* 2015; 11: 42-7.
 70. Heiss WD, Hilker R. The sensitivity of 18-fluorodopa positron emission tomography and magnetic resonance imaging in Parkinson's disease. *Eur J Neurol* 2004; 11: 5-12.
 71. Oikawa H, Sasaki M, Tamakawa Y et al. The substantia nigra in Parkinson disease: proton density-weighted spin-echo and fast short inversion time inversion-recovery MR findings. *Am J Neuro-radiol* 2002; 23: 1747-56.
 72. Ciurleo R, Di Lorenzo G, Bramanti P et al. Magnetic resonance spectroscopy: an in vivo molecular imaging biomarker for Parkinson's disease? *Biomed Res Int* 2014; 519816.
 73. Teune LK, Renken RJ, de Jong BM et al. Parkinson's disease-related perfusion and glucose metabolic brain patterns identified with PCASL-MRI and FDG-PET imaging. *Neuroimage Clin* 3: 240-4.
 74. Struck AF, Hall LT, Kusmirek JE et al. ¹⁸F-DOPA PET with and without MRI fusion, a receiver operator characteristics comparison. *Am J Nucl Med Mol Imaging* 2012; 2: 475-82.
 75. Barthel H, Schroeter ML, Hoffmann KT et al. PET/MR in dementia and other neurodegenerative diseases. *Semin Nucl Med* 2015; 45: 224-33.
 76. Niccolini F, Loane C, Politis M. Dyskinesias in Parkinson's disease: views from positron emission tomography studies. *Eur J Neurol* 2014; 21: 694-9.
 77. Lemaire C, Libert L, Franci X et al. Automated production at the curie level of no-carrier-added 6-[¹⁸F]fluoro- l-dopa and 2-[¹⁸F]fluoro- l-tyrosine on a FASTlab synthesizer. *J Labelled Comp Radiopharm* 2015; 58: 281-90.
 78. Cherubini A, Nisticó R, Novellino F et al. Magnetic resonance support vector machine discriminates essential tremor with rest tremor from tremor-dominant Parkinson disease. *Mov Disord* 2014; 29: 1216-9.
 79. Buresta T, Pompili F, Fravolini ML et al. Iodine-123-N-omega-fluoropropyl-2beta-carbomethoxy-3beta-(4-iodophenyl)-nortropane brain SPET with semiquantitative analysis in Parkinson's disease as evaluated by support vector machine classi-

- classifier: diagnostic performance and influence of age. *Hell J Nucl Med* 2014; 17:87.
80. Quattrone A, Cerasa A, Messina D et al. Essential head tremor is associated with cerebellar vermis atrophy: A volumetric and voxel-based morphometry MR imaging study. *Am J Neuroradiol* 2008; 29: 1692-7
81. Passamonti L, Cerasa A and Quattrone A. Neuroimaging of Essential Tremor: What is the Evidence for Cerebellar Involvement? *Tremor Other Hyperkinet Mov* 2012; 2.
82. Calabria F, Calabria E, Chiaravalloti A et al. A case of intracranial meningioma detected by ¹⁸F-choline PET/CT and examined by PET/MRI fusion imaging. *Rev Esp Med Nucl Imagen Mol* 2014; 33: 306-7.
83. Ledezma CJ, Chen W, Sai V et al. ¹⁸F-FDOPA PET/MRI fusion in patients with primary/recurrent gliomas: initial experience. *Eur J Radiol* 2009; 71: 242-8.
84. Bouilleret V, Semah F, Chassoux F et al. Basal ganglia involvement in temporal lobe epilepsy: a functional and morphologic study. *Neurology* 2008; 70: 177-84.
85. Kumakura Y, Gjedde A, Caprioli D et al. Increased turnover of dopamine in caudate nucleus of detoxified alcoholic patients. *PLoS One* 2013; 8: e73903.
86. Brunelin J, Fecteau S, MF. S-C. Abnormal striatal dopamine transmission in schizophrenia. *Curr Med Chem* 2013; 20: 397-404.



Salvator Dali, Mimicking the painting of Velasqueth, the Dwarf Sebastian de Moro and adding fried eggs himself. Mixed technique in canvas.