

Challenges and strategies on radioiodine treatment for differentiated thyroid carcinoma

Lingxiao Cheng, MD,
Min Liu, MD*,
Maomei Ruan, MD,
Libo Chen, MD, PhD

Department of Nuclear Medicine,
Shanghai Jiao Tong University
Affiliated
Sixth People's Hospital, 600 Yishan
Rd, Shanghai 200233, China

Keywords: Differentiated
thyroid carcinoma - Treatment
- Radioiodine - Indications
- Dosage

Corresponding author:

Prof. Libo Chen, MD, PhD,
Department of Nuclear Medicine
Shanghai Jiao Tong University
Affiliated Sixth People's
Hospital, 600 Yishan Rd,
Shanghai 200233, China
Tel: +86-21-24058871,
Fax: +86-21-64941720
libochen888@hotmail.com

Received:

10 January 2016

Accepted revised:

1 March 2016

Abstract

Objective: Radioiodine (^{131}I) is considered an effective and low-risk therapeutic radionuclide for differentiated thyroid carcinoma (DTC); however, dilemmas exist in the optimization of indications, pre-treatment thyroid stimulating hormone (TSH) stimulation, dose decision, as well as in the treatment of ^{131}I -refractory disease. Refined strategies on ^{131}I treatment for DTC based on late evidence and novel insights are greatly needed. **Conclusion:** The indications of ^{131}I ablation continue to be refined with a better understanding of the risks and benefits. For pre-treatment TSH stimulation, recombinant human thyrotropin presents a better choice as it improves the quality of life, but is indicated only for ablation of the thyroid remnant and follow-up. Decreased doses of ^{131}I seem to be more appropriate in patients without gross residual disease or metastases, but maximal doses are suggested in patients with advanced disease. Imaging procedures contributing to decision-making for patients with advanced DTC also continue to be modified. As for the ^{131}I -refractory disease, there is a trend to increase ^{131}I uptake and retention by using additional therapeutic agents like kinase inhibitors with encouraging results.

Hell J Nucl Med 2016; 19(1):23-32

Epub ahead of print: 1 March 2016

Published online: 1 April 2016

Introduction

For about 65 years, radioiodine (^{131}I) treatment is the standard treatment for differentiated thyroid carcinoma (DTC) combined with surgery and thyroid hormone replacement/inhibition [1]. However, challenges still exist in patient selection, pre-treatment thyroid stimulating hormone (TSH) stimulation, dose decision, as well as in the treatment for ^{131}I -refractory DTC (RR-DTC) [2]. In this review, these dilemmas are presented and corresponding strategies are provided taking into account the best available medical evidence and novel insights into the management of DTC. Significant studies necessary to further address these issues are recommended accordingly.

Initial patient selection for radioiodine remnant ablation (RRA)

The aim of ^{131}I administration post-surgery in DTC patients falls into three categories depending on risk stratification: remnant ablation, adjuvant therapy, and ^{131}I therapy [3]. Figure 1 displays risk stratifications according to the American Thyroid Association (ATA) and the European Thyroid Association (ETA) guidelines.

The goal of remnant ablation is to eliminate any normal thyroid tissue left after surgery, thereby simplifying disease surveillance by examinations, such as thyroglobulin (Tg) measurements and whole body ^{131}I scans (^{131}I WBS) [3]. Adjuvant therapy theoretically destroys suspected microscopic neoplastic cells in the hope of improving disease-free survival [3]. ^{131}I therapy is the administration of ^{131}I in an attempt to destroy gross extrathyroidal extension and recurrent or metastatic disease. In this setting, patient selection is fairly simple [4].

Most DTC patients in whom ^{131}I treatment is considered are in the remnant ablation setting, deserving optimization of indications. It is worth mentioning that in clinical practice remnant ablation, adjuvant therapy and ^{131}I therapy can be simultaneously achieved.

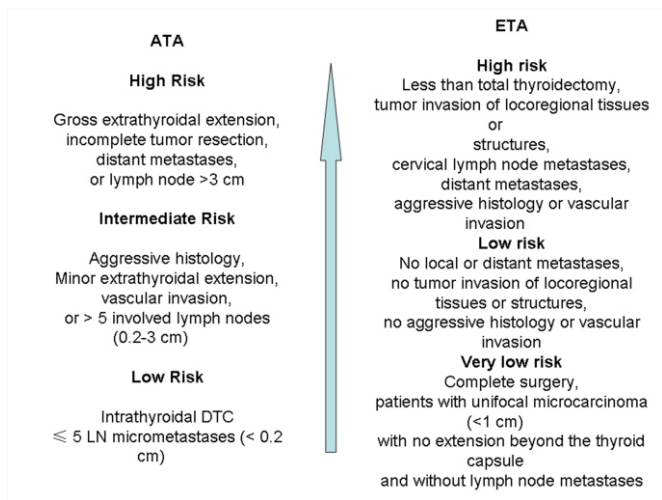


Figure 1. Risk stratifications of differentiated thyroid cancer (DTC) patients by the American Thyroid Association (ATA) (2015) and the European Thyroid Association (ETA) guidelines (2006).

ved when relatively high doses of ¹³¹I are administered. Radioiodine remnant ablation (RRA) is definitely recommended after total thyroidectomy for patients with large (>4cm) primary tumors or with gross extrathyroidal extension in order to improve disease-specific and disease-free survival [3]. Guidelines of ATA, ETA, and the National Comprehensive Cancer Network define the population of patients who do not require RRA, mainly those with small, (<1cm for papillary and <2cm for follicular or cell thyroid cancer), intrathyroidal tumors without other adverse features such as nodal or vascular invasion, high post-surgical thyroglobulin (Tg) levels or aggressive histology [3, 5, 6] (Table 1). However, there is still considerable controversy about the appropriate role of RRA in patients with primary tumors between 1 and 4cm in maximum diameter.

Rationales for RRA are as follows: ¹³¹I can destroy any possible occult residual microscopic thyroid carcinoma and thus reduce future disease recurrence. RRA facilitates long-term disease surveillance and detection of possible persistent or recurrent disease by the measurement of Tg concentrations as stimulated by thyroid-stimulating hormone (TSH) or by ¹³¹I WBS after RRA, or during the follow-up period [7].

Rationales against routinely administering RRA include: a) low risk of thyroid cancer associated mortality or disease recurrence [8], b) absence of consistent clear high quality evidence showing that such treatment reduces disease associated mortality or risk of recurrence [9], c) potential for short term and long term treatment associated side effects, d) availability of disease surveillance testing procedures that can be used irrespective of RRA status (such as diagnostic neck ultrasound with or without fine needle aspiration cytology, and unstimulated Tg measurements) [10]. Several following factors may contribute to decision making but their roles are not quite clear.

Table 1. Comparison of indications on radioiodine remnant ablation for differentiated thyroid carcinoma among different guidelines

Organization	Year	Indication
American Thyroid Association Reference [3]	2015	Not recommended when diameter <1cm (unifocal or multifocal, in absence of other high-risk features) Not routinely recommended when diameter is 1-4cm in the absence of other high-risk features Should be considered when diameter is >4cm and there is microscopic invasion Should be considered when diameter is >4cm with central compartment metastases
National Comprehensive Cancer Network Reference [5]	2014	Not recommended for small, <1cm for papillary and <2cm for follicular or Hórtle cell intrathyroidal tumors without evidence of nodal involvement or vascular invasion and with a low postsurgical thyroglobulin level
European Thyroid Association Reference [6]	2006	Not indicated when diameter is ≤1cm and there was complete surgery, favourable histology, and no nodal or distant metastases or extrathyroidal tumor extension Probably indicated when thyroidectomy was less than total, lymph-node dissection was not included, age <18 years, or T1>1cm and T2, N0M0, or if histology was unfavourable

Serum Tg

An area of controversy is about patients with elevated Tg without findings of macroscopic disease on the diagnostic ¹³¹I WBS. The discordance of Tg testing and imaging findings may be due to either false positive Tg or false negative ¹³¹I WBS. The former is usually caused by persistence of the thyroid remnant or by anti-Tg antibodies (TgAb) as tested by immunoradiometric assay. The later may be due to small volume of the lesion or to non iodine avid disease when ¹³¹I WBS is used [11].

According to ATA guidelines, for patients with relatively low (<5ng/mL) and stable serum Tg, conservative follow-up is generally recommended, but in the setting of higher or rapidly rising Tg, empiric treatment may be indicated [3]. On the other hand, even some patients with high risk clinicopathologic features have undetectable Tg after thyroidectomy, so the role of pretreatment Tg on deciding whether to proceed with treatment is insufficient and more studies are needed to guide decision making in this area.

Neck nodal involvement

Another area of controversy relates to the importance of neck nodal involvement. In a single center retrospective study, investigators examined data from a subgroup of 421 patients, and reported an improvement of lymph node failure-free survival in patients with node-positive papillary thyroid cancer (PTC) treated with ¹³¹I. It is noteworthy that the greatest treatment benefits are observed in patients with lateral neck node metastases (N1b disease), as well as with lymph nodes >1cm in diameter [12]. Evidence from multivariable and propensity analyses from the National Thyroid Cancer Treatment Cooperative Study Group (NTCTCSG) showed no benefit of the adjuvant ¹³¹I treatment in Stage I subjects, including patients younger than 45 years with central neck node disease (N1a disease), but showed a beneficial effect in stage III patients, including patients younger than 45 years with N1b disease and patients with nodal metastases aged ≥45 years [13]. Thus, younger patients with N1a disease, especially when the size of node metastases is small, may not benefit from adjuvant therapy, though more convincing evidence is expected to withhold ¹³¹I treatment in such patients. Moreover, the 2015 ATA guidelines have classified patients with few small central neck nodal diseases as a low-risk group and do not recommend routine use of ¹³¹I in these patients [3]. However there are studies that demonstrate the effectiveness of RRA, even in low/intermediate risk patients with minimal node involvement [14].

Molecular character of DTC

Strong association has been found between the recurrence of PTC and genetic alterations [15-17]. Interestingly, coexisting BRAF V600E and TERT promoter C228T mutations were more often associated with high-risk clinicopathologic characteristics of PTC [16]. In view of the high negative predictive value of coexisting mutations, patients who harbor neither mutation and are conventionally low risk would be spared from RRA. The prognostic ability of BRAF and of other genetic biomarkers needs further investigation in order to make specific therapeutic suggestions.

Pre-treatment TSH stimulation

Thyroid hormone withdrawal (THW) is common practice for pre-treatment TSH stimulation in many countries. However, hypothyroidism may occur as an undesirable situation [18].

Liothyronine (L-T3) substitution is one of the alternatives intended to avoid hypothyroidism due to THW, but a randomized controlled study showed that L-T3 substitution did not prevent hypothyroidism, and delayed TSH elevation [19,20]. Recombinant human thyrotropin (rhTSH), approved by Food and Drug Administration in 2007 for use in pre-ablation settings, induced high TSH levels without clinical hypothyroidism. Whole-body radiation exposure was thus decreased due to more rapid clearance of ¹³¹I [21]. Multiple randomized controlled trials (RCTs) showed that exogenous rhTSH offered a much better short term quality of life in low risk DTC patients while the efficacy of RRA treatment remained sufficient [22]. Therefore, rhTSH is an acceptable alternative to THW in these patients for remnant ablation.

Studies comparing the use of rhTSH to THW are not sufficient to decide which of these procedures is better in higher-risk DTC patients. Exogenous stimulation was suggested by some investigators [23, 24] while Hugo et al. (2012) [23] showed in 586 patients that the 9 years clinical outcome of both procedures was almost the same with similar recurrence rates 1.5% for rhTSH vs. 1.2% for THW. Studies on metastatic DTC showed that the radiation absorbed dose by the tumors was 4-10 times lower under rhTSH as compared to THW, which is a determinant factor for treatment response [25, 26].

Since rhTSH administered by the standard method of two rhTSH injections is beyond the reach of many patients, some researchers suggested a combined protocol i.e. a shorter withdrawal period and a single dose of rhTSH [27]. Vrachimis et al. (2012) reported that the overall efficacy of the combined endogenous and exogenous TSH stimulation was not significantly different between the above two procedures [27], and thus the combined protocol may be an attractive alternative for RRA in DTC.

Dosage of ¹³¹I and complication management

The dose of ¹³¹I given to DTC patients ranges depending on the aim of ¹³¹I administration: remnant ablation, adjuvant therapy, or ¹³¹I therapy.

Remnant ablation

RRA is the only purpose for administering ¹³¹I in DTC patients without macroscopic or microscopic tumor focus post surgery. The main consideration is minimizing radiation toxicity while maintaining a reasonable uptake in the thyroid remnant. In order to reduce the dose of ¹³¹I in low risk patients in whom RRA is indicated, it is suggested to give much less ¹³¹I than previously thought (i.e. 1.1GBq rather than 3.7GBq) [28]. Equivalent ablation success rates using 1.1GBq or 3.7GBq was also confirmed by two separate, large, randomized studies. However, it should be noted that persistent disease was found in 3.7% of the patients studied and a second dose was needed in 9.5% of the patients, indicating that a more concise evaluation of the disease was needed before deciding about the amount of the administered dose [29, 30].

Adjuvant therapy

In high risk for recurrence patients, ^{131}I is administered with the actual aim of both remnant ablation and adjuvant therapy although the optimum ^{131}I dose is not exactly known. There is little evidence to suggest that increased dose activity of ^{131}I is necessarily associated with improvement of clinical outcomes. A recent multivariable analysis using data from 1,171 DTC patients without distant metastases suggested that there was no significant difference in the risk of disease recurrence when using more or less than 2.78GBq of ^{131}I post operatively (higher dose activity hazard ratio 1.57, 95% CI 0.61 to 3.98, $P=0.341$, with a mean follow-up period of 60 months) [31]. Thus, a lower dose with a potential of fewer adverse effects seems more appropriate.

In a recent study, among 319 subjects with an intrathyroid tumor and no metastases (T1-T2, N0, M0), BRAF V600E-mutated PTC was found to require a higher number of ^{131}I courses to obtain disease-free status [32]. A possible explanation was that in the mutated cases, tumoral foci may be more frequently present in the postsurgical remnant because the BRAF V600E mutation correlates with multifocality. Similarly, DTC patients with TERT promoter mutated tumors were submitted to more ^{131}I treatments with higher cumulative activities [33]. Therefore, it is conceivable to include a search of the BRAF mutation and TERT promoter mutations in the workup of DTC patients without other risk features, in order to distinguish those requiring more aggressive treatments from those that can be treated with a more conservative approach. RCT are also needed to explore the impact of other genetic factors on the efficacy of ^{131}I in order to establish their role in guiding dose selection of post operative adjuvant therapy.

However, there is a biologic conundrum about the role of adjuvant therapy. Beta particles emitted by ^{131}I have a range in tissues of the order of millimeters, and thousands of beta particles must traverse a cell to provide a high likelihood of lethal DNA damage. In microscopic foci of the disease, the radiation dose may be insufficient to kill tumor cells because a significant fraction will be deposited outside the cells. Therefore, a relatively low but effective remnant ablation dose may be less successful in achieving the adjuvant goal of killing residual microscopic cells of the disease [34]. On the other hand, there are studies suggesting reduced local recurrence with postoperative RRA, a benefit beyond remnant ablation as an adjuvant effect. To explain this effect, research in patients with a higher risk for local recurrence is needed, randomizing patients to low-dose ^{131}I for RRA only versus higher doses for treating potentially small residual cancer deposits [34].

^{131}I therapy in locoregional or metastatic disease

There are usually three ways to choose the therapeutic dose of ^{131}I in locoregional or metastatic thyroid cancer disease: a) To administer an empirically fixed dose, b) To administer a dose determined by the upper permissible limit of radiation to be absorbed in blood and the whole body and c) To administer a dose calculated according to tumor and/or lesions dosimetry. Published data suggest that although comparison of the outcome after administering the above doses of ^{131}I is difficult, dosimetric approaches obviously

have some advantages over empirical approaches [35].

Empirical doses are generally safe for the typical patient but are not based on ^{131}I kinetics of a particular patient. Factors related to tumor burden, cardiac and renal function, and age can dramatically affect the maximal safe dose [36].

The dosimetric approach determines the maximum dose that can be safely given to prevent severe radiation toxicity. A ^{131}I dose of 7.4MBq would exceed the maximum tolerated radiation absorbed dose, defined as 200cGy to the blood, in 8%-15% of patients younger than 70 years and in 22%-38% of patients aged 70 years and older [37]. Since whole-body and blood dosimetry determines the maximum ^{131}I dose that can be safely given, they can maximize the probability of controlling the tumor and additionally prevent severe radiation toxicity.

In the treatment of DTC by ^{131}I , several parameters vary for every patient and may be more important than the administered ^{131}I activity. These parameters are: a) The tissue's avidity to ^{131}I , b) The residence time of ^{131}I per volume of blood or plasma and c) The effective half-life of ^{131}I in the target volume. Lesional dosimetric approaches can overcome the uncertainty of individual biokinetics, and thus are theoretically superior to empiric activity approaches. Lesional dosimetry, based on the absorbed dose of the target tissue, can prevent both suboptimal administration, which entails further ^{131}I treatment, and an excessive administration of radioactivity, which may increase radiation toxicity. One retrospective study concluded that patients with loco-regional disease were more likely to respond to dosimetric treatment than to empiric treatment [35].

Numerous investigators have used ^{124}I in PET or in PET/CT imaging to facilitate lesional dosimetry [38-40]. However, absorbed doses in a tumor may be inhomogeneous, which may lead to undertreatment of lesions not included in the dosimetric evaluation [40]. Future prospective studies are needed to determine formalisms, to weigh the biologically effective dose or the equivalent of a uniform ^{131}I dose, study the three-dimensional radiobiological dosimetry and provide more reliable recommendations for lesional dosimetry in DTC.

Complications management

A minority of patients may have early-and late-onset complications from ^{131}I treatment, such as taste dysfunction, salivary dysfunction, xerophthalmia, obstruction to the nasolacrimal duct and pulmonary fibrosis [41-43]. For acute transient loss of taste or change in taste and sialadenitis, current measures to prevent damage to the salivary glands include hydration, sour candies, amifostine, and cholinergic agents [44]. However, observed effects of sialagogues on radiation exposed salivary glands differ in various studies, so the exact role, so details of use of sialagogues to prevent salivary gland damage remains uncertain [45, 46]. For chronic salivary gland complications, such as dry mouth, cholinergic agents may increase salivary flow [44]. As for nasolacrimal duct obstruction, definite preventive measures have not been reported. Perhaps, the application of artificial tears may serve to prevent ophthalmic sequelae in the same way that sour candies have been used to potentially alleviate sialoadenitis; endoscopic dacryocystorhi-

nostomy is an effective cure for this complication [42]. Finally, in patients with diffuse pulmonary metastases, pneumonitis or pulmonary fibrosis are associated with extremely high individual doses and repeated administration of ^{131}I . Reduction in dose and courses of ^{131}I administration may minimize these complications [43].

Iodine-131 treatment for thyroid malignancy is also associated with a small risk of secondary malignancies in bones, breast, colorectal, kidneys, salivary glands, and leukemia; which seems to be associated with cumulative ^{131}I dose activity [47-49]. Methods of reducing abdominal pelvic viscera radiation dose, such as laxatives which decrease radiation exposure of the bowel and vigorous oral hydration which reduces exposure of the bladder and gonads, may help reduce the risk of secondary malignancies [47].

Imaging procedures contributing to decision-making in patients with advanced DTC

Tg testing and neck ultrasonography are routinely used for follow-up after initial treatment of DTC. However, once persistent/recurrent disease is detected by these tests, functional imaging or hybrid imaging should be proceeded in order to decide on subsequent treatment including ^{131}I therapy. For instance, for ^{131}I therapy, both the size of the lesions and their avidity for ^{131}I are important factors during decision-making. For example: persistent/recurrent disease with positive or negative ^{131}I WBS findings may need completely different treatment schedules (Figures 2 and 3). Large lesions, even if they are ^{131}I -avid, are not suitable for ^{131}I therapy due to poor treatment efficacy. We should mention that ^{131}I WBS provides whole body information, which also contributes to the plan of ^{131}I therapy or other treatments. Radioiodine-whole body scan (^{131}I WBS) used for follow-up after initial treatment detects ^{131}I -avid diseases which may require subsequent ^{131}I therapy. However, several problems exist in the use of ^{131}I WBS: equivocal findings are frequent in the absence of anatomical imaging, for example, it is difficult to differentiate between uptake due to lesions in the lung and the ribs. Furthermore, even a routine dose of ^{131}I in diagnostic ^{131}I WBS may cause stunning [50].

Incremental diagnostic value of ^{131}I SPET/CT over ^{131}I WBS was examined in a retrospective study, in which ^{131}I SPET/CT was reported to improve detection and localization of ^{131}I accumulation in lymph node metastases and distant metastases, and help change therapeutic planning in 3 (2.0%) of 147 patients [51]. An even greater additional value of ^{131}I SPET/CT was reported by a study of ours, in which therapeutic strategy was changed in 8 of 17 patients whose planar images showed doubtful lesions. With additional information of the lesions derived from ^{131}I SPET/CT, six of the 8 patients were transferred to surgery, one patient was transferred to interventional treatment, and the other referred to external-beam radiotherapy [52]. It is worth mentioning that for patients with bone and brain metastases that cannot be adequately controlled with additional surgery

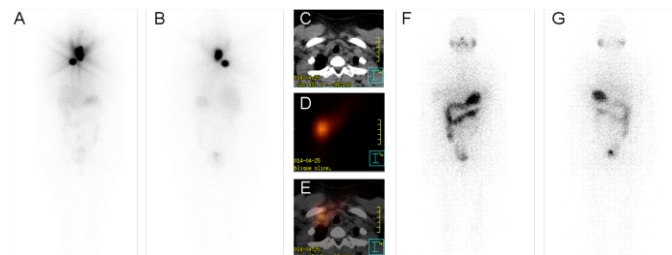


Figure 2. A 35 years old female in our department with papillary thyroid cancer and ^{131}I -avid lymph nodes metastases after surgery who had complete response after ^{131}I treatment. Anterior: A) and posterior: B) therapeutic WBS 5 days after the administration of 555MBq ^{131}I showed two "hot spots" in the neck with a stimulated serum thyroglobulin level of 8.65ng/mL and normal TgAb. SPET/CT revealed thyroid remnant (not shown) and lymph nodes metastases. C) CT image; D) SPET image; E) SPET/CT fusion image. Six months later, a diagnostic ^{131}I scan showed no visible remaining disease accompanied by an undetectable stimulated serum Tg level of <0.04ng/mL and a normal TgAb.

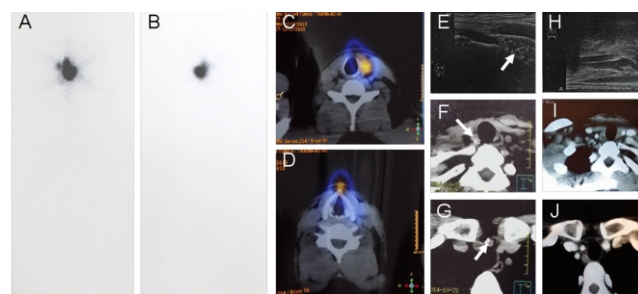


Figure 3. A 32 years old male in our department with papillary thyroid cancer and non ^{131}I -avid lymph nodes metastases after initial surgery who had a complete response after reoperation. Anterior: A) and posterior: B) therapeutic WBS 5 days after the administration of 555MBq ^{131}I showed a "hot spot" in the neck with a stimulated serum Tg of 15.93ng/mL and normal TgAb level. SPET/CT fusion image revealed only remnants in the left thyroid lobe: C) and the pyramidal lobe: D). However, calcified lymph nodes (arrow) were detected by ultrasonography: E) and plane CT: F) and G) indicating possible metastases. Pathologic examination of resected lymph nodes verified lymph node metastases from papillary thyroid cancer. Two months later, another ultrasonography: H) and enhanced CT: I) and J) were negative with an undetectable stimulated serum Tg level <0.04ng/mL and a normal TgAb.

for patients with ^{131}I refractory disease, the external beam radiotherapy should be considered [53]. This treatment helps to control pain, preserve or improve neurologic function, optimize local tumor control, and improve the quality of life [54]. In other studies carried out by colleagues of ours, hybrid imaging modalities were found to be more suitable for detecting more mediastinal lymph node metastases and for supporting treatment planning in DTC patients [55]. The ^{131}I SPET/CT imaging is also of incremental value in detecting rare metastases from DTC [56].

The ^{124}I PET image allows foci of highly specific ^{124}I uptake to be localized with a low radiation dose, which is specifically important in pretherapeutic diagnostics. The sensitivity of ^{124}I -PET for the detection of residual thyroid tissue and/or metastatic DTC was reported to be higher than that of a usual diagnostic ^{131}I WBS [57]. However, ^{124}I has not yet been widely available for routine clinical use and ^{124}I PET/CT has not yet been compared with ^{131}I SPET/CT in large

series of patients with DTC. Moreover, problems or pitfalls exist such as the “shine-through” effect, which hamper the interpretation of ^{124}I PET/CT imaging.

The ability of molecular imaging modalities mentioned above to detect persistent or recurrent DTC disease relies on the avidity of different radiotracers to lesions. As for non ^{131}I avid DTC lesions, the fluorine-18-fluorodeoxyglucose (^{18}F -FDG) PET imaging is a better diagnostic modality (than ^{131}I WBS) [58]. The incremental value of ^{18}F -FDG PET/CT over ^{131}I WBS in patients with extensive or metastatic high-risk DTC has been confirmed in a study by Rosenbaum-Krumme et al. (2012) [59]. Furthermore, high ^{18}F -FDG uptake on PET imaging in metastatic DTC is a reliable predictive factor for RR-DTC, which we will discuss in detail in the following part of this review [60].

As to ^{18}F -FDG PET/MRI, its diagnostic potential was evaluated very recently in comparison to PET/CT in patients with DTC suspected or known to have dedifferentiation, and it was found that PET/MRI was equal to contrast-enhanced neck PET/CT for the assessment of cervical lesions but was inferior to low-dose PET/CT for the assessment of pulmonary lesions [61].

Means of increasing ^{131}I uptake and retention in ^{131}I -refractory differentiated thyroid carcinoma

In patients with advanced disease RR-DTC is defined by the following outcomes: a) The presence of at least one tumor focus without any uptake of ^{131}I , b) Structural progression of the disease shortly after a ^{131}I treatment course (12 or 16 month later), c) No signs of remission after the administration of a cumulative activity of 22GBq or more. Although RR-DTC is rare, with an estimated incidence of four cases per million population or 5% of patients with clinical cancer, it is usually aggressive, with a median survival after distant metastases, ranging from 3 to 6 years [62]. The poor survival and the absence of effective treatment make the clinical management of RR-DTC extremely difficult [63].

Given the positive outcome from ^{131}I treatment in patients with ^{131}I -avid disease, enthusiastic physicians suggested to adopt additional therapeutic agents such as retinoids, epigenetic drugs and, kinase inhibitors and lithium in order to increase ^{131}I uptake and retention in DTC tumor cells in ^{131}I -refractory disease. It is also important to notice that RR-DTC can be asymptomatic and stable for a period of time and in such cases the benefits of novel therapies (kinase inhibitors therapy etc.) might be largely outweighed by drug toxicities [64, 65].

The main selection criterion in clinical trials in patients with RR-DTC is documented progression of target lesions within less than 1.5 years after ^{131}I therapeutic dose according to Response Evaluation Criteria In Solid Tumors. Patients with a large tumor burden might require systemic treatment, including cytotoxic chemotherapy or targeted therapy,

before assessment of progression. The decision to initiate treatment may be based on high ^{18}F -FDG uptake of the lesions on PET scan, on histological characteristics of the tumor and on Tg doubling time less than one year. These are signs predicting RR-DTC during the follow-up period [66].

In progression-free patients with few or asymptomatic metastatic foci, local treatment techniques, such as radiofrequency, external radiation treatment and surgery can be used and serum TSH should be maintained at a low or undetectable concentration [39, 67]. Figure 4 is a flowchart which outlines the current clinical management strategies for advanced DTC in cases of local recurrence/persistence and metastases.

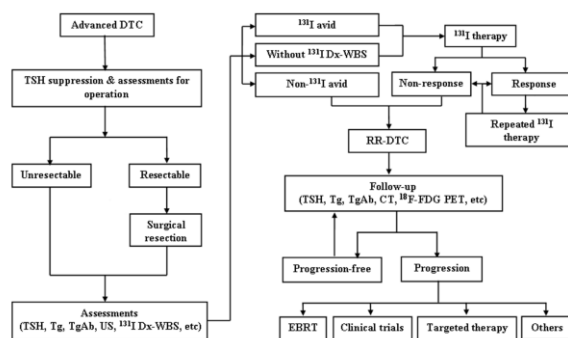


Figure 4. Flowchart of the management of advanced differentiated thyroid carcinoma including local recurrence/persistence and metastases.

Targeting signaling pathways

In early studies of DTC, multiple kinase signaling pathways (PI3K/Akt pathway, cAMP pathway, MAPK pathway etc.) were found activated due to genetic alterations, like RET/PTC rearrangement, mutations in RAS, BRAF genes etc. or due to other factors; which lead to low sodium iodine symporter (NIS) expression and/or to impaired targeting of NIS to plasma membrane, and ultimately lack of ^{131}I uptake of the lesions [68, 69]. The above findings suggest that inhibiting the over-activated pathways may be an effective way to reconstitute NIS function.

Preclinical investigations and clinical trials exhibit target agents ability to induce ^{131}I uptake. In-vitro studies [70, 71] showed that targeting of BRAF, MEK, or AKT in the MAPK and PI3K-AKT pathways could restore thyroid gene expression and ^{131}I uptake, which was enhanced by TSH in thyroid cancer (TC) cells. These findings are supported by a later in vivo study in which murine TC cells with inducible BRAF V600E mutations were re-sensitized to ^{131}I treatment by using MEK inhibitor PD0325901 and the selective BRAF V600E /Raf inhibitor PLX4720 [72]. Similarly, in our in vitro study [73], enhancement of ^{131}I uptake and decrease of glucose metabolism were simultaneously observed in the BHP-2-7 cells after treatment with either sorafenib or carbozantinib, and so the iodide-handling gene expression was restored and glucose transporter 1 and 3 expression was inhibited. Corresponding in vivo study is now ongoing. In a recent clinical

cal study, by combining selumetinib with ^{131}I treatment in advanced DTC, an increase in ^{131}I uptake was obtained in 12 of 20 evaluated patients [74]. Only 8/12 patients whose ^{124}I PET/CT scans showed that DTC lesions were exposed to at least 20Gy were selected to continue ^{131}I treatment and all had imaging evidence of response. More details will be revealed in an ongoing phase III study (NCT01843062) using selumetinib in combination with adjuvant radioiodine in high risk DTC patients after thyroidectomy. High induction of ^{131}I uptake (60%) was also obtained in patients with metastatic BRAF-mutant, and ^{131}I -refractory PTC treated with dabrafenib, an inhibitor of mutated BRAF. Two of these 10 enrolled patients had partial response and 4 patients had stable disease on standard radiographic restaging at 3 months [75]. Another two clinical trials (NCT01534897, NCT02145143) aiming to increase ^{131}I uptake and retention in RR-DTC patients using BRAF inhibitors are ongoing [76].

Although there is limited evidence of targeting overactive signaling pathways to induce ^{131}I uptake and contribute to increased efficacy of ^{131}I treatment in RR-DTC, combination treatment of target agents and ^{131}I is of great promise. Larger studies are necessary for confirming the magnitude and reproducibility of re-inducing ^{131}I uptake and longer observation time is needed to monitor the indolent DTC and to see if prolonged survival time can be obtained. In such studies, it should be clarified whether improved efficacy is mainly due to the antitumor effect of target agents or to improved ^{131}I uptake induced by the action of target agents. Optimization of therapeutic strategies based on genetic alterations remains to be further explored.

Acting on nuclear receptors

Retinoids (retinol and its derivatives) were reported to increase both expression of thyroid specific proteins and ^{131}I uptake in TC cells through acting on the nuclear receptors retinoic acid receptor (RAR) and retinoid X receptor (RXR) (mainly by activating RAR- α), whereas they decrease ^{131}I uptake in normal thyrocytes [77]. However, their clinical efficacy is limited. Isotretinoin (13-cis-RA) re-induced ^{131}I uptake in few patients with advanced DTC [78, 79]. Other studies reported inconsistent increase in ^{131}I uptake [80, 81] using tretinoin (all-trans RA). In a recent publication, Damle et al. (2015) showed that retinoic acid increased ^{131}I uptake in 55% of subjects but the magnitude of increase was very small [81]. Another less well-studied first generation retinoid, retinol, showed enhanced ^{131}I uptake in DTC cell lines but had a low anti-proliferative effect [82].

Peroxisome proliferator-activated receptor (PPAR) agonists, such as rosiglitazone, bind to PPAR- γ which is a transcription factor of the superfamily of nuclear receptors showed a decreased expression in DTC. These agonists form a heterodimer with the RXR receptor at the response elements, activating the transcription of target gene PTEN, which in turn inhibits PI3K pathway [83]. Evidence of rosiglitazone's ability to induce ^{131}I uptake has been accumulated in the previous decade. There are case reports describing successful induction of ^{131}I uptake after treatment with rosiglitazone in patients with non ^{131}I avid metastases of DTC [84, 85]. Furthermore, in trials including more patients,

an increase in ^{131}I uptake was observed in 40% and 26% of the patients after >6 weeks of pretreatment with up to 8mg of rosiglitazone [86, 87].

Directing against epigenetic alterations

Both methylation and deacetylation have been reported as mechanisms of dedifferentiation of cancer cells. Therefore, compounds that can reverse methylation or inhibit histone deacetylation may lead to the re-expression of silenced thyroid-specific genes.

In a study on mRNA expression of thyroid-specific genes (NIS, Tg, TPO and TSHR) and on ^{131}I uptake in the PTC cell line B-CPAP, various gene modulators were examined, however, the DNA methyltransferase inhibitor (DMI) 5-azacytidine was the only compound which increased ^{131}I uptake [88]. Another DMI, 5-aza-20-deoxycytidine, which was showed to increase expression of thyroid transcription factor 1 in follicular TC, PTC and anaplastic TC cell lines [89], is under evaluation in an ongoing phase II study (NCT00085293).

A new hydroxamic acid-derived histone deacetylase inhibitor panobinostat was reported to cause re-expression of NIS and to increase the cytotoxic effect of ^{131}I treatment [90]. Romidepsin, another novel compound, was tested in a phase II trial, and was reported to restore ^{131}I avidity in 2 of the 20 treated patients, but no objective response was showed after ^{131}I treatment [91].

Lithium and other agents

Lithium causes an increased cell retention of iodide due to inhibition of its efflux [92], and short-term treatment with LiCO_3 as adjunct to ^{131}I improves the efficacy of ^{131}I in hyperthyroidic patients [93]. Recent presentation by Ilhan Lim on the 84th annual meeting of ATA showed that a response rate of 45% was obtained in metastatic RR-DTC after combined treatment of ^{131}I and lithium for 6 months, and a slightly higher 10 years survival rate was achieved compared to patients with only ^{131}I treatment (67.9% vs. 66.8%, $P>0.05$). Other compounds, such as genistein, alpha-lipoic acid, arsenic trioxide and metformin have also been reported to increase ^{131}I uptake to different extents in vitro and in vivo [94-98].

In conclusion, although ^{131}I has become a prototypical theranostic agent for DTC, challenges still exist in the ^{131}I treatment of DTC. Based on recent clinical experience, ^{131}I can be more appropriately administered via better patient selection, further modified pre-treatment TSH stimulation and more precise dose decision. During long-term management, although serum Tg measurements and neck ultrasonography are routinely used with excellent diagnostic efficacy, functional/hybrid imaging modalities including WBS, SPET/CT or PET/CT using various radiotracers provide incremental information for decision-making of therapeutic strategies. As to management of RR-DTC, clinical data on various redifferentiation compounds failed to meet the initial high expectations, while novel target agents have displayed their ability to control the disease as well as to increase ^{131}I uptake and retention in cases of RR-DTC, indicating that combined treatment with target agents and ^{131}I has become one of the most important issues and deserves further investigation.

Acknowledgment

This study was sponsored by the National Natural Science Foundation of China (81271609) and the Shanghai Rising-Star Programme (12QH1401600). We thank Prof. Yansong Lin of the Department of Nuclear Medicine, Peiking Union Medical College Hospital and Prof. Haixia Guan of the Department of Endocrinology and Metabolism, The First Hospital of China Medical University, for their helpful discussions.

The authors declare that they have no conflicts of interest

Bibliography

- Maheshwari YK, Hill CS Jr, Haynie TP 3rd et al. ¹³¹I therapy in differentiated thyroid carcinoma: M. D. Anderson Hospital experience. *Cancer* 1981;47(4):664-71.
- Mayson SE, Yoo DC, Gopalakrishnan G. The evolving use of radioiodine therapy in differentiated thyroid cancer. *Oncology* 2015;88(4):247-56.
- Haugen BR, Alexander EK, Bible KC et al. 2015 American Thyroid Association Management Guidelines for Adult Patients with Thyroid Nodules and Differentiated Thyroid Cancer: The American Thyroid Association Guidelines Task Force on Thyroid Nodules and Differentiated Thyroid Cancer. *Thyroid* 2016;26(1):1-133.
- Schlumberger M, Challeton C, de VF et al. Radioactive iodine treatment and external radiotherapy for lung and bone metastases from thyroid carcinoma. *J Nucl Med* 1996;37:598-605.
- Pacini F, Castagna MG, Brillì L et al. Thyroid cancer: ESMO Clinical Practice Guidelines for diagnosis, treatment and follow-up. *Ann Oncol* 2012;23 Suppl 7:vii 110-19.
- Tuttle RM, Haddad RI, Ball DW et al. Thyroid carcinoma, version 2.2014. *J Natl Compr Canc Netw* 2014;12(12):1671-80; quiz 1680.
- Sawka AM, Brierley JD, Tsang RW et al. An updated systematic review and commentary examining the effectiveness of radioactive iodine remnant ablation in well-differentiated thyroid cancer. *Endocrinol Metab Clin North Am* 2008;37(2):457-80.
- Schwartz C, Bonnetain F, Dabakuyo S et al. Impact on overall survival of radioactive iodine in low-risk differentiated thyroid cancer patients. *J Clin Endocrinol Metab* 2012;97(5):1526-35.
- Lamartina L, Durante C, Filetti S et al. Low-risk differentiated thyroid cancer and radioiodine remnant ablation: a systematic review of the literature. *J Clin Endocrinol Metab* 2015;100(5):1748-61.
- Durante C, Montesano T, Attard M et al. Long-term surveillance of papillary thyroid cancer patients who do not undergo post-operative radioiodine remnant ablation: is there a role for serum thyroglobulin measurement? *J Clin Endocrinol Metab* 2012;97(8):2748-53.
- Adedapo KS, Vangu MD. Data on repeated ¹³¹I-WB scans and the incidence of positive Tg and negative ¹³¹I-WBS in DTC patients from a 24 months study. *Hell J Nucl Med* 2011;14(2):131-4.
- Chow SM, Yau S, Kwan CK et al. Local and regional control in patients with papillary thyroid carcinoma: specific indications of external radiotherapy and radioactive iodine according to T and N categories in AJCC 6th edn. *Endocr Relat Cancer* 2006;13(4):1159-72.
- Jonklaas J, Sarlis NJ, Litofsky D et al. Outcomes of patients with differentiated thyroid carcinoma following initial therapy. *Thyroid* 2006;16(12):1229-42.
- Frangos S, Iakovou IP, Marlowe RJ et al. Difficulties in deciding whether to ablate patients with putatively "low-intermediate-risk" differentiated thyroid carcinoma: do guidelines mainly apply in the centres that produce them? Results of a retrospective, two-centre quality assurance study. *Eur J Nucl Med Mol Imaging* 2015;42(13):2045-55.
- Duntas L, Grab-Duntas BM. Risk and prognostic factors for differentiated thyroid cancer. *Hell J Nucl Med* 2006;9(3):156-62.
- Xing M, Liu R, Liu X et al. BRAF V600E and TERT promoter mutations cooperatively identify the most aggressive papillary thyroid cancer with highest recurrence. *J Clin Oncol* 2014;32(25):2718-26.
- Kim TH, Park YJ, Lim JA et al. The association of the BRAF(V600E) mutation with prognostic factors and poor clinical outcome in papillary thyroid cancer: a meta-analysis. *Cancer* 2012;118(7):1764-73.
- Reiners C, Hanscheid H, Luster M et al. Radioiodine for remnant ablation and therapy of metastatic disease. *Nat Rev Endocrinol* 2011;7(10):589-95.
- Leboeuf R, Perron P, Carpentier AC et al. L-T3 preparation for whole-body scintigraphy: a randomized-controlled trial. *Clin Endocrinol (Oxf)* 2007;67(6):839-44.
- Lee J, Yun MJ, Nam KH et al. Quality of life and effectiveness comparisons of thyroxine withdrawal, triiodothyronine withdrawal, and recombinant thyroid-stimulating hormone administration for low-dose radioiodine remnant ablation of differentiated thyroid carcinoma. *Thyroid* 2010;20(2):173-9.
- Rosario PW, Xavier AC, Calsolari MR. Recombinant human thyrotropin in thyroid remnant ablation with ¹³¹I in high-risk patients. *Thyroid* 2010;20(11):1247-52.
- Tu J, Wang S, Huo Z et al. Recombinant human thyrotropin-aided versus thyroid hormone withdrawal-aided radioiodine treatment for differentiated thyroid cancer after total thyroidectomy: a meta-analysis. *Radiother Oncol* 2014;110(1):25-30.
- Hugo J, Robenshtok E, Grewal R et al. Recombinant human thyroid stimulating hormone-assisted radioactive iodine remnant ablation in thyroid cancer patients at intermediate to high risk of recurrence. *Thyroid* 2012;22(10):1007-15.
- Rosario PW, Mineiro Filho AF, Lacerda RX et al. Long-term follow-up of at least five years after recombinant human thyrotropin compared to levothyroxine withdrawal for thyroid remnant ablation with radioactive iodine. *Thyroid* 2012;22(3):332-3.
- Freudenberg LS, Jentzen W, Petrich T et al. Lesion dose in differentiated thyroid carcinoma metastases after rhTSH or thyroid hormone withdrawal: ¹²⁴I PET/CT dosimetric comparisons. *Eur J Nucl Med Mol Imaging* 2010;37(12):2267-76.
- Potzi C, Moameni A, Karanikas G et al. Comparison of iodine uptake in tumour and nontumour tissue under thyroid hormone deprivation and with recombinant human thyrotropin in thyroid cancer patients. *Clin Endocrinol (Oxf)* 2006;65(4):519-23.
- Vrachimis A, Schober O, Riemann B. Radioiodine remnant ablation in differentiated thyroid cancer after combined endogenous and exogenous TSH stimulation. *Nuklearmedizin* 2012;51(3):67-72.
- Cheng W, Ma C, Fu H et al. Low- or high-dose radioiodine remnant ablation for differentiated thyroid carcinoma: a meta-analysis. *J Clin Endocrinol Metab* 2013;98(4):1353-60.
- Mallick U, Harmer C, Yap B et al. Ablation with low-dose radioiodine and thyrotropin alfa in thyroid cancer. *N Engl J Med* 2012;366(18):1674-85.
- Schlumberger M, Catargi B, Borget I et al. Strategies of radioiodine ablation in patients with low-risk thyroid cancer. *N Engl J Med* 2012;366(18):1663-73.
- Kruijff S, Aniss AM, Chen P et al. Decreasing the dose of radioiodine for remnant ablation does not increase structural recurrence rates in papillary thyroid carcinoma. *Surgery* 2013;154(6):1337-44; discussion 1344-35.
- Elisei R, Viola D, Torregrossa L et al. The BRAF(V600E) mutation is an independent, poor prognostic factor for the outcome of patients with low-risk intrathyroid papillary thyroid carcinoma: single-institution results from a large cohort study. *J Clin Endocrinol Metab* 2012;97(12):4390-8.
- Melo M, da Rocha AG, Vinagre J et al. TERT promoter mutations are a major indicator of poor outcome in differentiated thyroid carcinoma.

- mas. *J Clin Endocrinol Metab* 2014; 99(5): E754-65.
34. Pryma DA, Mandel SJ. Radioiodine therapy for thyroid cancer in the era of risk stratification and alternative targeted therapies. *J Nucl Med* 2014; 55(9): 1485-91.
 35. Tuttle RM, Leboeuf R, Robbins RJ et al. Empiric radioactive iodine dosing regimens frequently exceed maximum tolerated activity levels in elderly patients with thyroid cancer. *J Nucl Med* 2006; 47(10): 1587-91.
 36. Kulkarni K, Van ND, Atkins F et al. The relative frequency in which empiric dosages of radioiodine would potentially overtreat or undertreat patients who have metastatic well-differentiated thyroid cancer. *Thyroid* 2006; 16: 1019-23.
 37. Klubo-Gwiezdzinska J, Van Nostrand D, Atkins F et al. Efficacy of dosimetric versus empiric prescribed activity of ¹³¹I for therapy of differentiated thyroid cancer. *J Clin Endocrinol Metab* 2011; 96(10): 3217-25.
 38. Pettinato C, Monari F, Nanni C et al. Usefulness of ¹²⁴I PET/CT imaging to predict absorbed doses in patients affected by metastatic thyroid cancer and treated with ¹³¹I. *Q J Nucl Med Mol Imaging* 2012; 56(6): 509-14.
 39. Sgouros G, Hobbs RF, Atkins FB et al. Three-dimensional radiobiological dosimetry (3D-RD) with ¹²⁴I PET for ¹³¹I therapy of thyroid cancer. *Eur J Nucl Med Mol Imaging* 2011; 38 Suppl 1: S41-47.
 40. Westphal JG, Winkens T, Kuhnel C et al. Low-activity ¹²⁴I-PET/low-dose CT versus ¹³¹I probe measurements in pretherapy assessment of radioiodine uptake in benign thyroid diseases. *J Clin Endocrinol Metab* 2014; 99(6): 2138-45.
 41. Van Nostrand D. Sialoadenitis secondary to ¹³¹I therapy for well-differentiated thyroid cancer. *Oral Dis* 2011; 17: 154-61.
 42. Sun GE, Hatipoglu B. Epiphora after radioactive iodine ablation for thyroid cancer. *Thyroid* 2013; 23(2): 243-5.
 43. Chen L, Shen Y, Luo Q et al. Pulmonary fibrosis following radioiodine therapy of pulmonary metastases from differentiated thyroid carcinoma. *Thyroid* 2010; 20(3): 337-40.
 44. Mandel SJ, Mandel L. Radioactive iodine and the salivary glands. *Thyroid* 2003; 13: 265-71.
 45. Jentzen W, Balschuwweit D, Schmitz J et al. The influence of saliva flow stimulation on the absorbed radiation dose to the salivary glands during radioiodine therapy of thyroid cancer using ¹²⁴I PET/CT imaging. *Eur J Nucl Med Mol Imaging* 2010; 37: 2298-306. 989.
 46. Van Nostrand D, Bandaru V, Chennupati S et al. Radiopharmacokinetics of radioiodine in the parotid glands after the administration of lemon juice. *Thyroid* 2010; 20: 1113-9.
 47. Rubino C, de Vathaire F, Dottorini ME et al. Second primary malignancies in thyroid cancer patients. *Br J Cancer* 2003; 89: 1638-44.
 48. Brown AP, Chen J, Hitchcock YJ et al. The risk of second malignancies up to three decades after the treatment of differentiated thyroid cancer. *J Clin Endocrinol Metab* 2008; 93: 504-15.
 49. Hakala TT, Sand JA, Jukkola A, et al. Increased risk of certain second primary malignancies in patients treated for well-differentiated thyroid cancer. *Int J Clin Oncol* 2015 Sep 26. [Epub ahead of print].
 50. Leitha T, Staudenherz A. Frequency of diagnostic dilemmas in ¹³¹I whole body scanning. *Nuklearmedizin* 2003; 42(2): 55-62.
 51. Jeong SY, Lee SW, Kim HW et al. Clinical applications of SPECT/CT after first ¹³¹I ablation in patients with differentiated thyroid cancer. *Clin Endocrinol (Oxf)* 2014; 81(3): 445-51.
 52. Chen L, Luo Q, Shen Y et al. Incremental value of ¹³¹I SPECT/CT in the management of patients with differentiated thyroid carcinoma. *J Nucl Med* 2008; 49(12): 1952-7.
 53. Lee N, Tuttle M. The role of external beam radiotherapy in the treatment of papillary thyroid cancer. *Endocr Relat Cancer* 2006; 13(4): 971-7.
 54. Kushchayeva YS, Kushchayev SV, Wexler JA et al. Current treatment modalities for spinal metastases secondary to thyroid carcinoma. *Thyroid* 2014; 24(10): 1443-55.
 55. Xu YH, Shen CT, Xue YL et al. Iodine-131 SPET/CT and ¹⁸F-FDG PET/CT for the identification and localization of mediastinal lymph node metastases from differentiated thyroid carcinoma. *Hell J Nucl Med* 2013; 16(3): 199-203.
 56. Song HJ, Xue YL, Qiu ZL et al. Uncommon metastases from differentiated thyroid carcinoma. *Hell J Nucl Med* 2012; 15(3): 233-40.
 57. Van Nostrand D, Moreau S, Bandaru VV et al. ¹²⁴I positron emission tomography versus ¹³¹I planar imaging in the identification of residual thyroid tissue and/or metastasis in patients who have well-differentiated thyroid cancer. *Thyroid* 2010; 20(8): 879-83.
 58. He X, Wang X, Yu J et al. Is it practical and cost effective to detect differentiated thyroid carcinoma metastases by ¹⁸F-FDG PET/CT, by ¹⁸F-FDG SPET/CT or by ¹³¹I SPET/CT? *Hell J Nucl Med* 2015; 18(1): 2-4.
 59. Rosenbaum-Krumme SJ, Gorges R, Bockisch A et al. ¹⁸F-FDG PET/CT changes therapy management in high-risk DTC after first radioiodine therapy. *Eur J Nucl Med Mol Imaging* 2012; 39(9): 1373-80.
 60. Lee JW, Min HS, Lee SM et al. Relations Between Pathological Markers and Radioiodine Scan and ¹⁸F-FDG PET/CT Findings in Papillary Thyroid Cancer Patients With Recurrent Cervical Nodal Metastases. *Nucl Med Mol Imaging* 2015; 49(2): 127-34.
 61. Vrachimis A, Burg MC, Wenning C et al. ¹⁸F-FDG PET/CT outperforms ¹⁸F-FDGPET/MRI in differentiated thyroid cancer. *Eur J Nucl Med Mol Imaging* 2015.
 62. Durante C, Haddy N, Baudin E et al. Long-term outcome of 444 patients with distant metastases from papillary and follicular thyroid carcinoma: benefits and limits of radioiodine therapy. *J Clin Endocrinol Metab* 2006; 91(8): 2892-9.
 63. Sherman SI. Cytotoxic chemotherapy for differentiated thyroid carcinoma. *Clin Oncol (R Coll Radiol)* 2010; 22(6): 464-8.
 64. Schutz FA, Je Y, Richards CJ, Choueiri TK. Meta-analysis of randomized controlled trials for the incidence and risk of treatment-related mortality in patients with cancer treated with vascular endothelial growth factor tyrosine kinase inhibitors. *J Clin Oncol* 2012; 30: 871-7.
 65. Brose MS, Nutting CM, Jarzab B, et al. Sorafenib in radioactive iodine-refractory, locally advanced or metastatic differentiated thyroid cancer: a randomised, double-blind, phase 3 trial. *Lancet* 2014; 384: 319-28.
 66. Vaisman F, Carvalho DP, Vaisman M. A new appraisal of iodine refractory thyroid cancer. *Endocr Relat Cancer* 2015; 22(6): R301-10.
 67. Wertenbroek MW, Links TP, Prins TR et al. Radiofrequency ablation of hepatic metastases from thyroid carcinoma. *Thyroid* 2008; 18: 1105-10.
 68. Durante C, Puxeddu E, Ferretti E et al. BRAF mutations in papillary thyroid carcinomas inhibit genes involved in iodine metabolism. *J Clin Endocrinol Metab* 2007; 92(7): 2840-3.
 69. Dohan O, Baloch Z, Banrevi Z et al. Rapid communication: predominant intracellular overexpression of the Na(+)/I(-) symporter (NIS) in a large sampling of thyroid cancer cases. *J Clin Endocrinol Metab* 2001; 86(6): 2697-700.
 70. Liu D, Hu S, Hou P et al. Suppression of BRAF/MEK/MAP kinase pathway restores expression of iodide-metabolizing genes in thyroid cells expressing the V600E BRAF mutant. *Clin Cancer Res* 2007; 13(4): 1341-9.
 71. Hou P, Bojdani E, Xing M. Induction of thyroid gene expression and radioiodine uptake in thyroid cancer cells by targeting major signaling pathways. *J Clin Endocrinol Metab* 2010; 95(2): 820-8.
 72. Chakravarty D, Santos E, Ryder M et al. Small-molecule MAPK inhibitors restore radioiodine incorporation in mouse thyroid cancers with conditional BRAF activation. *J Clin Invest* 2011; 121(12): 4700-11.
 73. Ruan M, Liu M, Dong Q et al. Iodide- and glucose-handling gene expression regulated by sorafenib or cabozantinib in papillary thyroid cancer. *J Clin Endocrinol Metab* 2015; 100(5): 1771-9.
 74. Ho AL, Grewal RK, Leboeuf R et al. Selumetinib-enhanced radioio-

- dine uptake in advanced thyroid cancer. *N Engl J Med* 2013; 368(7): 623-32.
75. Rothenberg SM, McFadden DG, Palmer EL et al. Redifferentiation of iodine-refractory BRAF V600E-mutant metastatic papillary thyroid cancer with dabrafenib. *Clin Cancer Res* 2015; 21(5): 1028-35.
76. Cabanillas ME, Patel A, Danysh BP et al. BRAF inhibitors: experience in thyroid cancer and general review of toxicity. *Horm Cancer* 2015; 6(1): 21-36.
77. Jeong H, Kim YR, Kim KN et al. Effect of all-trans retinoic acid on sodium/iodide symporter expression, radioiodine uptake and gene expression profiles in a human anaplastic thyroid carcinoma cell line. *Nucl Med Biol* 2006; 33(7): 875-82.
78. Kim WG, Kim EY, Kim TY et al. Redifferentiation therapy with 13-cis retinoic acids in radioiodine-resistant thyroid cancer. *Endocr J* 2009; 56(1): 105-12.
79. Handkiewicz-Junak D, Roskosz J, Hasse-Lazar K et al. 13-cis-retinoic acid re-differentiation therapy and recombinant human thyrotropin-aided radioiodine treatment of non-Functional metastatic thyroid cancer: a single-center, 53-patient phase 2 study. *Thyroid Res* 2009; 2(1): 8.
80. Zhang Y, Jia S, Liu Y et al. A clinical study of all-trans-retinoid-induced differentiation therapy of advanced thyroid cancer. *Nucl Med Commun* 2007; 28(4): 251-5.
81. Damle N, Patnecha M, Kumar P et al. Retinoic acid therapy in patients with radioiodine negative differentiated thyroid cancer and clinical or biochemical evidence of disease: An initial experience. *Indian J Nucl Med* 2011; 26(3): 144-8.
82. Frohlich E, Brossart P, Wahl R. Induction of iodide uptake in transformed thyrocytes: a compound screening in cell lines. *Eur J Nucl Med Mol Imaging* 2009; 36(5): 780-90.
83. Kapiteijn E, Schneider TC, Morreau H et al. New treatment modalities in advanced thyroid cancer. *Ann Oncol* 2012; 23(1): 10-8.
84. Elola M, Yoldi A, Emparanza JI et al. [Redifferentiation therapy with rosiglitazone in a case of differentiated thyroid cancer with pulmonary metastases and absence of radioiodine uptake]. *Rev Esp Med Nucl* 2011; 30(4): 241-3.
85. Elias AN, Lizotte P. Enhanced radioiodine uptake in a patient with poorly differentiated papillary thyroid cancer after treatment with rosiglitazone. *Clin Nucl Med* 2006; 31(9): 517-9.
86. Kebebew E, Peng M, Reiff E et al. A phase II trial of rosiglitazone in patients with thyroglobulin-positive and radioiodine-negative differentiated thyroid cancer. *Surgery* 2006; 140(6): 960-6; discussion 966-7.
87. Tepmongkol S, Keelawat S, Honsawek S et al. Rosiglitazone effect on radioiodine uptake in thyroid carcinoma patients with high thyroglobulin but negative total body scan: a correlation with the expression of peroxisome proliferator-activated receptor-gamma. *Thyroid* 2008; 18(7): 697-704.
88. Tuncel M, Aydin D, Yaman E et al. The comparative effects of gene modulators on thyroid-specific genes and radioiodine uptake. *Cancer Biother Radiopharm* 2007; 22(2): 281-8.
89. Kondo T, Nakazawa T, Ma D et al. Epigenetic silencing of TTF-1/NKX2-1 through DNA hypermethylation and histone H3 modulation in thyroid carcinomas. *Lab Invest* 2009; 89(7): 791-9.
90. Pugliese M, Fortunati N, Germano A et al. Histone deacetylase inhibition affects sodium iodide symporter expression and induces ¹³¹I cytotoxicity in anaplastic thyroid cancer cells. *Thyroid* 2013; 23(7): 838-46.
91. Sherman EJ, Su YB, Lyall A et al. Evaluation of romidepsin for clinical activity and radioactive iodine reuptake in radioactive iodine-refractory thyroid carcinoma. *Thyroid* 2013; 23(5): 593-9.
92. Liu YY, van der Pluijm G, Karperien M et al. Lithium as adjuvant to radioiodine therapy in differentiated thyroid carcinoma: clinical and in vitro studies. *Clin Endocrinol (Oxf)* 2006; 64(6): 617-24.
93. Sekulic V, Rajic MP, Vljakovic MZ et al. Short term treatment with lithium carbonate as adjunct to radioiodine treatment for long-lasting Graves' hyperthyroidism. *Hell J Nucl Med* 2015; 18(3): 186-8.
94. Kang HJ, Youn YK, Hong MK et al. Antiproliferation and redifferentiation in thyroid cancer cell lines by polyphenol phytochemicals. *J Korean Med Sci* 2011; 26(7): 893-9.
95. Choi HJ, Kim TY, Ruiz-Llorente S et al. Alpha-lipoic acid induces sodium iodide symporter expression in TPC-1 thyroid cancer cell line. *Nucl Med Biol* 2012; 39(8): 1275-80.
96. Frohlich E, Czarnocka B, Brossart P et al. Antitumor effects of arsenic trioxide in transformed human thyroid cells. *Thyroid* 2008; 18(11): 1183-93.
97. Gonçalves CF, Santos MC, Ginabreda MG et al. Flavonoid rutin increases thyroid iodide uptake in rats. *PLoS One* 2013; 8(9): e73908.
98. Abdulrahman RM, Boon MR, Sips HC et al. Impact of Metformin and compound C on NIS expression and iodine uptake in vitro and in vivo: a role for CRE in AMPK modulation of thyroid function. *Thyroid* 2014; 24(1): 78-87.