

Echocardiography versus ^{201}Tl semi-quantitative gated single photon emission tomography for the evaluation of cardiac disease associated with late stage Duchenne muscular dystrophy

Atsushi Fujita^{1,2} MD,
Hajime Arahata¹ MD, PhD,
Miwa Sugawara¹ MD,
Akihiro Watanabe¹ MD,
Yuji Kawano¹ MD, PhD,
Naokazu Sasagasako¹ MD, PhD,
Naoki Fujii¹ MD, PhD

1. Department of Neurology,
Neuro-Muscular Center,
National Omuta Hospital, Japan

2. Department of Neurology,
Neurological Institute,
Graduate School of Medical
Sciences, Kyushu University, Japan

Keywords: Duchenne muscular
dystrophy (DMD) -DMD late stage
-Cardiac diseases
- ^{201}Tl semi quantitative gated SPET
(SQGS) -Echocardiography
-DMD older than 20 years

Corresponding author:

Atsushi Fujita MD,
Department of Neurology,
Neurological Institute,
Graduate School of Medical
Sciences, Kyushu University, Japan
a-fujita@neuro.med.kyushu-u.ac.jp

Received:

29 February 2016

Accepted:

22 March 2016

Abstract

Objective: In Duchenne muscular dystrophy (DMD) patients cardiac abnormalities are often detected. In adult DMD patients cardiac disease (CD) is a cause of death which increases by age and is related to respiratory dysfunction. Studies have demonstrated that CD in early DMD can be detected by echocardiography (EC) or semi-quantitative gated single photon emission tomography (^{201}Tl SQGS), and the accuracy of these two tests is similar. As the disease advances, evaluation of CD by EC becomes difficult due to thoracic deformity and scoliosis. We compared ^{201}Tl SQGS and EC in the evaluation of cardiac function in late stage DMD, based on the ejection fraction (EF) value calculated by both tests. Twenty-three males with late stage DMD, 12 to 35 years of age (22.2 ± 7.5), were studied by ^{201}Tl SQGS and EC. The mean EF value by ^{201}Tl SQGS was $60.8\pm 14.1\%$, which differed from that obtained by EC ($52.7\pm 9.8\%$, $P=0.003$). Eleven patients less than 20 years old did not demonstrate a significant difference between the two tests ($P=0.06$), however, 12 patients over 20 years of age had significantly different results between tests ($P=0.002$). **Conclusion:** Although our patients were few we indicated that in DMD patients, aged older than 20 years, at an advanced stage of the disease, the EF values calculated by EC were lower than those by ^{201}Tl SQGS possibly due to thoracic deformity.

Hell J Nucl Med 2016; 19(1): 19-22

Published online: 1 April 2016

Introduction

Duchenne muscular dystrophy (DMD) is an X-linked recessive skeletal and cardiac myopathy, caused by dystrophin abnormalities, a protein in the sarcolemma [1]. Severe skeletal muscle weakness, starting at early childhood, is the most disabling symptom for these patients; however, dilated cardiomyopathy and heart failure tend to be fatal symptoms even under well-controlled respiratory system management. Previous studies have demonstrated that imaging techniques like echocardiography (EC), nuclear medicine or magnetic resonance imaging (MRI) can successfully detect pre-symptomatic cardiac dysfunction [2]. In the clinical setting, ECC is frequently used because it is an easily applied and readily available technique. However, in late stage of DMD, poor acoustic imaging windows due to thoracic changes and scoliosis make EC difficult to apply. Alternative methods, such as cardiac MRI and nuclear medicine, have been used in these patients [3, 4].

Nuclear medicine can be applied in cases of CD, testing both cardiac function and perfusion [5-8]. Previous studies have shown that thallium-201 semi-quantitative gated single photon emission tomography (^{201}Tl SQGS) was useful for cardiac function evaluation in early-stage DMD patients in which no significant difference between ^{201}Tl SQGS and EC was detected [9]. Studies comparing ^{201}Tl SQGS and EC at the late stage of DMD patients, however, to the best of our knowledge have not been reported.

In this paper, we aim to determine whether ^{201}Tl SQGS can be used to evaluate cardiac dysfunction at the late stage of DMD patients and whether there is a difference between ^{201}Tl SQGS and EC in these patients.

Subjects and Methods

Patients and study design

We enrolled 23 wheelchair-bound DMD patients, aged 12 to 35 years (22.2 ± 7.5), from

the Department of Neurology, Neuro-Muscular Center, National Omuta Hospital (Fukuoka prefecture, Japan) between January 2013 and August 2013. All patients underwent a full clinical examination and biochemical checks, including skeletal muscle biopsy and genetic testing. In each patient, the diagnosis of DMD was confirmed by clinical findings, the presence of elevated serum creatine kinase levels, and muscular biopsy demonstrating dystrophin deficiency by immunohistochemical stains. The patient's height, weight and cobb angle on a radiograph were measured and ejection fraction (EF) was calculated from the data taken by ^{201}Tl SQGS and EC.

Data collection

Ten minutes after $74\text{MBq } ^{201}\text{Tl Cl}_2$ (Nihon Medi-Physics Co., Ltd., Japan) was injected intravenously, data were acquired over 180° arc by a 2-head single photon emission tomography (SPET) camera (E.CAM, Siemens Medical Solutions, USA) with cardiac collimators (64X64 matrix, 36 projections, 8 frames per cardiac cycle, 30s per projection). A zoom factor of 1.45 was used. The pixel size was 3.3mm. Reconstruction was performed with a Butterworth filter (cutoff frequency, 0.6). For calculation we used commercially available software package: Cedars QGS.

EC data were calculated by modified Simpson's method using Xario XG (Toshiba Medical Systems Co., Ltd., Japan) or UF-8900 (Fukuda Denshi Co., Ltd., Japan).

To estimate left ventricular function, end-diastolic volume (LVEDV), end-systolic volume (LVESV) and EF were used. Normal EF values are more than 45% in ^{201}Tl SQGS [10] and 55%-83% in EC.

Statistical analysis

Clinical data, including age, were expressed as mean (\pm SD). Student's t-test was used for comparison between the left ventricular parameter values of ^{201}Tl SQGS and echocardiography. Spearman rank method was used for assessment of correlation between degree of scoliosis and EF deference among the two modalities. A P value of <0.05 was considered statistically significant. Software JMP pro 11 was used for statistical analysis.

Results

Clinical data

Table 1 presents the patients' data and EF values calculated by ^{201}Tl SQGS and EC. The mean age, height and weight were 22.2 ± 7.5 years, $153\pm 9.0\text{cm}$ and $34\pm 8.0\text{kg}$, respectively. The mean EF value was $60.8\%\pm 14.1\%$ by ^{201}Tl SQGS and $52.7\%\pm 9.8\%$ by EC.

Left ventricular function

Three of 23 patients had abnormal EF values in ^{201}Tl SQGS and 10 of 23 patients in EC respectively. All 3 patients in ^{201}Tl SQGS had decreased EF value in EC also. Four patients with apparent dilated cardiomyopathy (DCM) had EF decreased to $42.3\%\pm 5.9\%$ in ^{201}Tl SQGS and $33.5\%\pm 10.0\%$ in EC.

A comparison of mean EF values by ^{201}Tl SQGS and EC is shown in Figure 1. Thallium-201 SQGS yielded a higher mean EF value than EC ($P=0.003$).

Table 1. Comparison of indications

Number	23
Age (year)	22.2 ± 7.5
Height (cm)	153 ± 9.0
Weight (kg)	34 ± 8
Cobb angle ($^\circ$)	35.2 ± 23.0
^{201}Tl SQGS EF (%)	60.8 ± 14.1
EC EF (%)	52.7 ± 9.8

EF: Ejection fraction; EC: Echocardiography; ^{201}Tl SQGS: Thallium-201 quantitative gated SPET

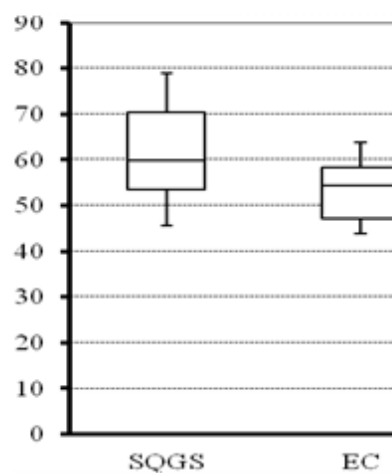


Figure 1. The calculated EF of ^{201}Tl SQGS and the corresponding EC EF among all patients. * $P<0.05$ by Student's t-test.

The patients were divided into two groups, according to their ages. The difference between ^{201}Tl SQGS and EC was not significant in eleven patients aged less than 20 years old ($P=0.06$), however this difference was significant in twelve patients over 20 years old ($P=0.002$) (Figure 2). Details of the data for the two groups are given in Table 2.

In terms of left ventricular volume, LVEDV was similar in ^{201}Tl SQGS and EC but LVESV was significantly lower in ^{201}Tl SQGS than in EC. The data are shown in Table 3.

Correlation between the degree of scoliosis and EF deference among the two modalities

In our study, all patients had scoliosis (cobb angle $>10^\circ$). There was moderate correlation between the degree of scoliosis and EF deference ($r=0.57$, $P=0.004$).

Discussion

Table 2. Comparison of the two groups divided by age

	Group A	Group B
Number	11	12
Age (year)	15.2±2.4	28.3±5.6
Height (cm)	153.2±8.1	152.4±10.3
Weight (kg)	38.8±9.7	29.5±2.7
²⁰¹ Tl SQGS EF (%)	61.9±9.4	59.8±18.3
EC EF (%)	58.4±6.2	47.5±10.2

EF: Ejection fraction; EC: Echocardiography; ²⁰¹Tl SQGS: Thallium-201 quantitative gated SPET. Group A: patients less than 20 years old; Group B: patients over 20 years old

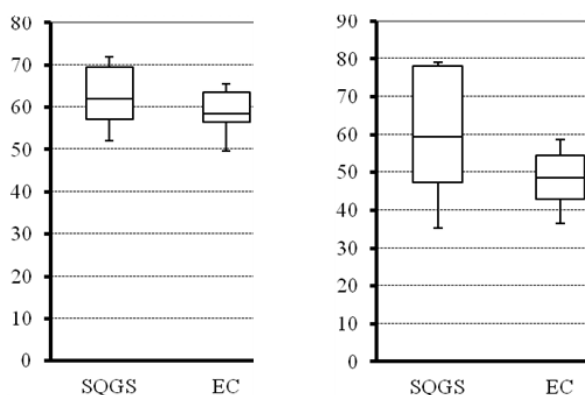


Figure 2. (A) The calculated EF of ²⁰¹Tl SQGS and corresponding EC EF among patients less than 20 years old. (B) The calculated EF of ²⁰¹Tl SQGS and corresponding EC EF among patients over 20 years old. *P<0.05 by Student's t-test.

Table 3. Comparison of left ventricular volume parameters

	SQGS	EC	P value
diastolic volume (EDV or LVDd) (ml)	45.7±18.3	41.4±5.0	0.17
systolic volume (ESV or LVDs) (ml)	19.9±14.7	30.3±4.7	0.003*

EC: Echocardiography; ²⁰¹Tl SQGS: Thallium 201 quantitative gated SPET, EDV: end-diastolic volume; ESV: end-systolic volume; LVDd: left ventricular diameter diastolic LVDs: left ventricular diameter systolic (LVDs)

Patients with DMD often start demonstrating cardiac abnormalities at 10-20 years of age [11]. Dystrophin, which is mutated in DMD patients, plays an important role in myocyte integrity as a component of membranous scaffolding, ion channels, and neurotransmitter receptors, and therefore chronic progressive myocyte death and fibrous tissue replacement have been detected in both skeletal and cardiac muscle of DMD patients. Early detection and management of cardiomyopathy may be beneficial in delaying

progression, and therefore biochemical and imaging approaches have been designed. While EC is still the standard diagnostic modality for cardiomyopathy in DMD patients, its evaluation is hindered by narrow EC acoustic windows due to scoliosis [12-14]. In general, ambulatory DMD patients do not develop scoliosis but most of them, (85%-90%) develop scoliosis only during the late wheelchair-dependent phase [15].

Ejection fraction estimation with ²⁰¹Tl-chloride, despite low administered activity, has been reported to produce results equally reliable with ^{99m}Tc-tracers for EF calculation [16].

Earlier research demonstrated that in younger DMD patients (3 to 14 years old), the efficacy of EC and ²⁰¹Tl QGS was similar for the evaluation of EF [9]. Our results, although in a small number of patients, also indicated that patients younger than 20 years old did not show significant differences of EF between EC and ²⁰¹Tl SQGS. The EF values obtained by ²⁰¹Tl SQGS were higher than EF values obtained by EC in late stage of DMD patients, aged older than 20 years. Seven group B patients who had left ventricular dysfunction with EC had normal function with ²⁰¹Tl SQGS. The EF deference was supposed to arise from the gap of end systolic volume among the two modalities.

All patients in this study had an electrocardiogram (ECG) at enrollment. Although 7 younger patients (aged 12 to 18) had normal ECG findings, the others had some ECG abnormalities commonly seen in DMD patients, for example right axis deviation, incomplete right bundle branch block, prominent Q wave and so on. But having in mind that a previous study showed no difference between ECG findings in patients with DMD, with DCM and without DCM, we thought that the ECG abnormalities were not related to left ventricular function evaluation [17].

In this preliminary work we did not study whether EC or ²⁰¹Tl SQGS estimated better the patient's true cardiac function. We suspect that thoracic changes make EC hard to perform, and therefore EC underestimates cardiac function. The moderate correlation between the degree of scoliosis and differences in EF supports this hypothesis.

Our results must be confirmed by further studies involving a larger number of DMD patients in which MRI and left ventriculography may also be used.

In conclusion, our preliminary results although in a small number of ambulatory DMD patients in an advanced stage of the disease indicated that such patients aged more than 20 years had lower EF values measured by EC than by ²⁰¹Tl SQGS which is perhaps due to the thoracic deformities of these patients.

Bibliography

1. Hamosh A, Scott AF, Amberger JS et al. A knowledgebase of human genes and genetic disorders. *Online Mendelian Inheritance in Man (OMIM)*. *Nucleic Acids Res* 2005;33:D514-7.
2. Cox GF, Kunkel LM. Dystrophies and heart disease. *Curr Opin Cardiol* 1997; 12(3): 329-43.
3. Fazio G, Novo G, D'Angelo L et al. Magnetic resonance in isolated noncompaction of the ventricular myocardium. *Int J Cardiol* 2010; 140: 367-9.
4. Tsuburaya RS, Uchizumi H, Ueda M et al. Utility of real time three dimensional echocardiography for Duchenne muscular dystrophy

- with echocardiographic limitations. *Neuromuscular Disorder* 2014; 24(5):402-8.
5. Dagna P, Sobic-Saranovic, Smiljana V et al. Evaluation of myocardial perfusion and function by gated single-photo emission computed tomography technetium-99m methoxyisobutylsonitrite in children and adolescents with severe congenital heart disease. *Neucl Med Comm* 2010; 31: 12-21.
 6. Guido G, Hosen K, Paul B et al. Automatic Quantification of ejection fraction from gated myocardial perfusion SPECT. *J Nucl Med* 1995; 36: 2138-47.
 7. Christophe M, Charles C, Kian B et al. Quantification of left ventricular function with thallium-201 and technetium-99m-sestamibi myocardial gated SPECT. *J Nucl Med* 1997; 38: 958-61.
 8. Guido G, Paul B, Hsiao-Te S et al. Automatic reorientation of three-dimensional, transaxial myocardial perfusion SPECT images. *J Nucl Med* 1995; 36: 1107-14.
 9. Peng F, Lingge W, Jing H et al. Assessment of cardiac abnormalities in Duchenne's muscular dystrophy by ^{99m}Tc-MIBI gated myocardial perfusion imaging. *Hell J Nucl Med* 2012; 15(2): 114-9.
 10. Tail S, Guido G, Paul B et al. Incremental prognostic value of post-stress left ventricular ejection fraction and volume by gated myocardial perfusion single photon emission computed tomography. *Circulation* 1999; 100(10): 1035-42.
 11. Bushby K, Muntoni F, Bourke J et al. 107th ENMC international workshop: the management of cardiac involvement in muscular dystrophy and myotonic dystrophy. 7th-9th June 2002, Naarden, the Netherlands. *Neuromuscular Disord* 2003; 13(2): 166-72.
 12. Viollet L, Thrush PT, Flanigan K et al. Effects of angiotensin-converting enzyme inhibitors and/or beta blockers on the cardiomyopathy in Duchenne muscular dystrophy. *Am J Cardiol* 2012; 110(1): 98-102.
 13. Yamamoto T, Kawano S, Sugiyama D et al. Predicting scores for left ventricular dysfunction in Duchenne muscular dystrophy. *Pediatr Int* 2012; 54(3): 388-92.
 14. van Bockel E, Lind J, Zijlstra J et al. Cardiac assessment of patients with late stage Duchenne muscular dystrophy. *Neth Heart J* 2009; 17(6): 232-7.
 15. Berven, S, Bradford, D.S. et al. Neuromuscular scoliosis: causes of deformity and principles for evaluation and management. *Semin Neurol* 2002; 22(2): 167-78.
 16. Kurisu S, Iwasaki T, Ikenaga H et al. Influence of left ventricular geometry on thallium-201 gated single-photon emission tomographic findings in patients with known or suspected coronary artery disease. *Ann Nucl Med* 2014; 28(2): 120-7.
 17. Thrush P.T, Allen H.D, Viollet L et al. Re-examination of the electrocardiogram in boys with Duchenne muscular dystrophy and correlation with its dilated cardiomyopathy. *Am J Cardiol* 2009; 103(2): 262-5



Interior design of Qavam House or Naranjestan, a 19th century residence which is called: Place of Oranges, Iran.