

Incidental possible diagnosis by ^{18}F -fluorocholine PET/CT of Meckel's diverticulum and potential pitfalls

Lih Kin Khor¹ MBBS, FRCR, MMED, FAMS,
Hoi Yin Loi¹ MD, MRCP, FRCR,
Arvind Kumar Sinha¹ MD,
Suat-Jin Lu² MBBS, M.Med,
FRCR, FAMS

1. Department of Diagnostic Imaging, National University Health System, Singapore
2. Nuclear Medicine and PET Centre, Mount Elizabeth Hospital, Singapore

Keywords: Meckel's diverticulum
- ^{18}F -fluorocholine positron emission tomography/computed tomography (F- ^{18}F -FCH PET/CT)
- Prostate cancer
- Prostate specific antigen
- Heterotopic pancreatic tissue

Correspondence address:

Lih Kin Khor MBBS, FRCR, MMED, FAMS,
Department of Diagnostic Imaging National University Health System 5 Lower Kent Ridge Road, Singapore 119074
Work: +65 67722181,
Personal phone:
+65 81027618,
Fax: +65 68723002
superkhor@hotmail.com

Received:

18 March 2015

Accepted revised:

21 May 2015

Abstract

A 61 years old man with a history of prostate cancer Gleason 3+4, treated with radical prostatectomy, underwent fluorine-18-fluorocholine positron emission tomography/computed tomography (^{18}F -FCH PET/CT) imaging to investigate rising serum prostate specific antigen (PSA) levels. ^{18}F -FCH PET/CT showed a focus of linear increased uptake by a possible Meckel's diverticulum in the right hemi-pelvis, which was an incidental finding in this asymptomatic patient. Uptake of ^{18}F -FCH by Meckel's diverticulum has not been reported before and thus the mechanism of uptake has not been established. Two postulations may explain this uptake. First, since Meckel's diverticulum is a true diverticulum containing all layers of the intestinal wall, the uptake may be related to physiological bowel-related uptake. Second, the uptake may be due to heterotopic pancreatic tissue in Meckel's diverticulum, especially since the intensity of uptake we have noticed was similar to that of physiological pancreatic uptake. As ^{18}F -FCH PET/CT scan is often used for evaluating prostate cancer, ^{18}F -FCH uptake by Meckel's diverticulum in the pelvis or lower abdomen may be mistaken for tumor involvement/recurrence. The identification by imaging of Meckel's diverticulum relies on the identification of a blind ending tubular structure, arising from the distal ileum. The identification of this structure may be best appreciated on the axial, coronal or sagittal plane. **Conclusion:** In this particular case, we managed to clearly demonstrate the presence of a tubular blind ending structure arising from the distal ileum on the sagittal images. The careful identification of this structure indicated that tracer uptake was in a Meckel's diverticulum and not within a pelvic lymph node or pelvic organ hence excluding recurrent disease.

Hell J Nud Med 2015; 18(2): 157-159

Epub ahead of print: 19 July 2015

Published online: 5 August 2015

Introduction

Meckel's diverticulum is the most common congenital anomaly of the gastrointestinal tract and is seen in 2% of the population. Meckel's diverticulum is typically asymptomatic and is usually found incidentally, with a reported lifetime risk of complications of 4%-40% [1-3]. Heterotopic gastric mucosa and pancreatic tissue are frequently found histologically in Meckel's diverticulum of symptomatic patients [1-3]. Complications of Meckel's diverticulum such as hemorrhage and diverticulitis are often caused by enzymatic secretion from heterotopic gastric mucosa or pancreatic tissue, resulting in mucosal ulceration.

Fluorine-18-fluorocholine (^{18}F -FCH) positron emission tomography/computed tomography (PET/CT) is used in oncologic imaging, most commonly to evaluate prostate cancer. Indications of ^{18}F -FCH PET/CT in prostate cancer include staging of high-risk prostate cancer, and re-staging of biochemical recurrence and castrate-resistant disease [4-6]. Physiological uptake of ^{18}F -FCH is commonly seen in the liver, pancreas, spleen, salivary and lacrimal glands, kidneys and urinary tract, and to a lesser extent in bowel and bone marrow [7].

Case report

A 61 years old man with a history of prostate cancer Gleason 3+4, treated with radical prostatectomy, presented with rising serum prostate specific antigen (PSA) levels that increased from 0.56 $\mu\text{g}/\text{L}$ to 3.02 $\mu\text{g}/\text{L}$ over a period of 1 year. ^{18}F -FCH PET/CT imaging was performed to investigate the rising PSA levels. We used Biograph mCT 64-slice,

Siemens AG, Erlangen, Germany; injected dose 266.4MBq, initial static acquisition of the pelvis; one bed position-5min, followed by delayed 60min whole body PET/CT; 7 bed positions-3min per bed position. This technique revealed a linear focus of increased uptake in the right hemi-pelvis, close to the spine (Figure 1, arrows), which was localized in a blind-ending tubular structure arising from the distal ileum, consistent with a Meckel's diverticulum (Figure 2, SUVmax 13.4, arrows). The intensity of uptake by this lesion was fairly similar to the intensity of physiological uptake of the pancreas (Figure 1, SUVmax 14.2). Low-grade patchy physiological uptake of the bowel was, mainly seen in the left abdomen and pelvis (Figure 1). Physiological uptake of the salivary glands, stomach, kidneys and bone marrow was also noted. No suspicious uptake was detected elsewhere to suggest local recurrence, regional lymphadenopathy or distant metastasis related to prostate cancer. In our center, we routinely perform ^{18}F -FCH PET/CT for cases of prostate cancer. From our experience, we have confidently diagnosed metastatic disease to lymph nodes, bones and lungs. We carefully scrutinize the CT component routinely to differentiate bowel activity from tracer uptake by metastatic pelvic or mesenteric lymph nodes as well as tracer uptake within local recurrence in the seminal vesicles, prostate or prostatic bed.

The patient was asymptomatic with no symptoms related to the abdomen or bowel, such as pain or bleeding. On follow-up for one year, he did not develop any abdominal or bowel symptoms related to Meckel's diverticulum. The absence of clinical manifestations confirmed that the uptake of ^{18}F -FCH by what we considered to be Meckel's diverticulum was an incidental finding. Hence no further imaging was performed.

Discussion

Technetium-99m-pertechnetate scan is used to detect heterotopic gastric mucosa in Meckel's diverticulum, especially in patients with unexplained gastrointestinal bleeding. Uptake of iodine-131 by the Meckel's diverticulum had also been observed, which may be related to sodium-iodide symporters in its heterotopic gastric mucosa. [8, 9].

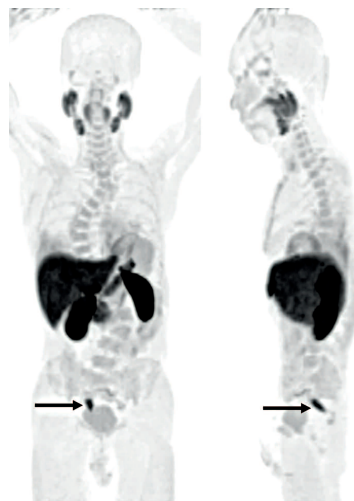


Figure 1. Maximum intensity projection (MIP) of ^{18}F -FCH PET/CT imaging showed a linear focus of increased uptake in the right hemi-pelvis (arrows, SUVmax 13.4), which was fairly similar in intensity with the physiological uptake of the pancreas (SUVmax 14.2). Low-grade patchy physiological uptake of the bowel was seen, mainly in the left abdomen and pelvis.

Uptake of ^{18}F -FCH by Meckel's diverticulum has not been reported before and thus the mechanism of such uptake has not been established. There are two postulations that may help explain the uptake of ^{18}F -FCH by Meckel's diverticulum. First, Meckel's diverticulum is a true diverticulum that contains all layers of the intestinal wall. Hence, uptake of ^{18}F -FCH by Meckel's diverticulum may be related to physiological bowel-related uptake, since bowel is one of the known sites of ^{18}F -FCH biodistribution. Second, uptake of ^{18}F -FCH by Meckel's diverticulum may be due to uptake by heterotopic pancreatic tissue in it. The intensity of uptake by the lesion we considered to be Meckel's diverticulum was fairly similar to the physiological uptake of pancreas. This was an incidental finding without clinical manifestations or complications and so there was no indication for further investigation in order to confirm histologically Meckel's diverticulum. The authors are confident that the characteristic location of the tubular blind ending structure at the distal ileum is likely consistent with a Meckel's diverticulum. Other less likely differentials would include a pseudo-diverticulum in Crohn's disease (no evidence of inflammatory bowel disease on the correlative CT) or a diverticulum of the small intestine.

The incidental creased uptake of ^{18}F -FCH in Meckel's diverticulum has potential clinical implications, may lead to potential pitfalls during image interpretation and may possibly be mistaken for a nodal metastasis or for tumor involvement of the seminal vesicle, urinary bladder or distal ureter, or a focus of tumor recurrence in a patient with rising PSA levels. Therefore, careful anatomical correlation with the aid of the CT scan is essential. Furthermore, since Meckel's diverticulum can vary widely in position and orientation, reviewing ^{18}F -FCH PET/CT images in axial, coronal and sagittal planes is vital to avoid these pitfalls. For instance in this patient, the blind-ending tubular Meckel's diverticulum was best appreciated in the sagittal CT plane (Figure 2).

In conclusion, we present a rare case of ^{18}F -FCH uptake in a possible Meckel's diverticulum detected incidentally on ^{18}F -FCH whole body PET/CT performed in a prostate cancer patient. This case highlights the importance of carefully scrutinizing the CT component which can help differentiate physiological tracer uptake, in this case within a possible Meckel's diverticulum from pathological uptake within lymph nodes or pelvic organs. This intense focal tubular

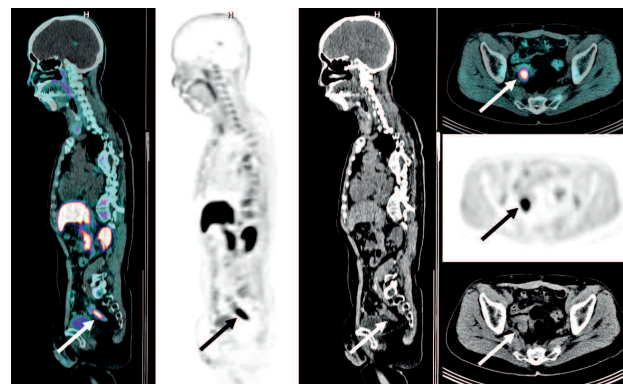


Figure 2. The linear focus of ^{18}F -FCH uptake in the right hemi-pelvis was localized in a blind-ending tubular structure arising from the distal ileum, consistent with Meckel's diverticulum (arrows). This was best appreciated in the sagittal plane.

tracer uptake led us to hypothesize that it was related to the presence of ectopic pancreatic or gastric tissue which also shows intense physiological uptake of ^{18}F -FCH. There was no evidence of bowel thickening or stranding of the adjacent mesenteric fat to suggest an inflammatory process. This case demonstrates another possible means for nuclear physicians to diagnose Meckel's diverticulum.

The authors declare that they have no conflicts of interest.

Bibliography

1. Elsayes KM, Menias CO, Harvin HJ, Francis IR. Imaging manifestations of Meckel's diverticulum. *Am J Roentgenol* 2007; 189: 81-8.
2. Fink AM, Alexopoulou E, Carty H. Bleeding Meckel's diverticulum in infancy: unusual scintigraphic and ultrasound appearances. *Pediatr Radiol* 1995; 25: 155-6.
3. Levy AD, Hobbs CM. From the archives of the AFIP. Meckel diverticulum: radiologic features with pathologic correlation. *Radiographics* 2004; 24: 565-87.
4. Umbehrr MH, Müntener M, Hany T et al. The role of ^{11}C -choline and ^{18}F -fluorocholine positron emission tomography (PET) and PET/CT in prostate cancer: a systematic review and meta-analysis. *Eur Urol* 2013; 64: 106-17.
5. Bauman G, Belhocine T, Kovacs M et al. ^{18}F -fluorocholine for prostate cancer imaging: a systematic review of the literature. *Prostate Cancer Prostatic Dis* 2012; 15: 45-55.
6. Jadvar H. Prostate cancer: PET with ^{18}F -FDG, ^{18}F - or ^{11}C -acetate, and ^{18}F - or ^{11}C -choline. *J Nucl Med* 2011; 52: 81-9.
7. Schillaci O, Calabria F, Tavolozza M et al. ^{18}F -choline PET/CT physiological distribution and pitfalls in image interpretation: experience in 80 patients with prostate cancer. *Nucl Med Commun* 2010; 31: 39-45.
8. Caplan RH, Gundersen GA, Abellera RM, Kisten WA. Uptake of iodine-131 by a Meckel's diverticulum mimicking metastatic thyroid cancer. *Clin Nucl Med* 1987; 12: 760-2.
9. Oh JR, Ahn BC. False-positive uptake on radioiodine whole-body scintigraphy: physiologic and pathologic variants unrelated to thyroid cancer. *Am J Nucl Med Mol Imaging* 2012; 2: 362-85.
10. Mittal Br, Kashyap R, Bhattacharya A et al. Meckel's diverticulum in infants and children; technetium-99m pertechnetate scintigraphy and clinical findings. *Hell J Nucl Med* 2008; 11(1): 26-9.
11. Vourlioti P. Scintiscan with sodium hypertechetate in the diagnosis of Meckel's diverticulum. *Hell J Nucl Med* 2001; 4(2): 66-70.
12. Papatolios T, Giannoulis E, Theocharidis A. The scintiscan of Meckel's diverticulum and its complications. *Hell J Nucl Med* 2000; 3(3): 156-9.
13. Lohsiriwat V, Sirivech T, Laohapansang M, Pongpaibul A. Comparative study on the characteristics of Meckel's diverticulum removal from asymptomatic and symptomatic patients: 18-year experience from Thailand's largest university hospital. *J Med Assoc Thai*. 2014; 97(5): 506-12.



Dr Johann Conrad Brunner (1653-1727). He attempted ablating a dog's pancreas to induce diabetes. The ablation was incomplete and he falsely concluded that pancreas was unrelated to diabetes. This was then believed for the next 150 years.