

# High accuracy of myocardial perfusion imaging in patients with left bundle branch block: comparison of four interpretation approaches

**Babak Fallahi<sup>1</sup>,  
Davood Beiki<sup>1</sup>,  
Mohammad Eftekhari<sup>1</sup>,  
Kianoush Ansari Gilani<sup>1</sup>,  
Armaghan Fard-Esfahani<sup>1</sup>,  
Ali Gholamrezanezhad<sup>1</sup>,  
Ahmad Yamini Sharif<sup>2</sup>,  
Mojtaba Ansari<sup>3</sup>,  
Mohsen Saghari<sup>1</sup>**

1. Research Institute for Nuclear Medicine and
2. Tehran Heart Center, Tehran University of Medical Sciences, Tehran, Iran
3. Nuclear Medicine Department, Imam Hossein Hospital, Shahid Beheshti University of Medical Sciences, Tehran, Iran

☆☆☆

## Keywords:

- Myocardial perfusion imaging
- Left bundle branch block
- Interpretation
- Coronary artery disease

## Correspondence address:

Davood Beiki, Research Institute for Nuclear Medicine, Shariati Hospital, North Kargar Ave. 1411713135, Tehran, Iran.  
Tel: +98 21 88026901,  
Fax: +98 21 88026905,  
E-mail: beikidav@sina.tums.ac.ir

## Received:

9 March 2009

## Accepted revised:

2 May 2009

## Abstract

Although myocardial perfusion imaging (MPI) with pharmacologic stress is the standard method for screening coronary artery disease (CAD) in patients with left bundle branch block (LBBB), controversies remain about its correct interpretation. We sought the best interpretation approach in these patients to achieve higher accuracy. *Forty-two patients* with LBBB underwent MPI with dipyridamole stress and the criteria for positive results with four patterns of interpretation were as follows: *Pattern A*: any reversible or irreversible perfusion abnormality in the myocardium irrespective of the location or extension was considered positive. *Pattern B*: any reversible or irreversible perfusion abnormalities except in the septal/anteroseptal region were defined as positive. *Pattern C*: in the absence of fixed LV cavity dilatation, the scan was interpreted the same as pattern A, while in the presence of fixed LV cavity dilatation, only the abnormalities outside the LAD territory was defined as positive. *Pattern D*: as in pattern C, except that in the absence of fixed LV cavity dilatation, the scan was read according to pattern B. For all patients, the angiographic results were considered as gold standard of CAD diagnosis. *Our results* showed that the false positive rate of MPI in patients with fixed LV dilatation was 50%, while in cases with normal LV size or transient dilatation, was 38.5%. This difference was more prominent in the female patients. The accuracy for screening CAD for patterns A, B, C and D were 57%, 62%, 69% and 69%, respectively. Pattern D was the better approach in female cases and patients with fixed septal/anteroseptal defects. *In conclusion*, a) In the male population without fixed defects in the septal/anteroseptal region, the specificity and accuracy are high in all patterns and the pattern of reading does not significantly influence the diagnostic value of MPI for CAD screening. b) In LBBB patients, fixed defects limited to the septal/anteroseptal region should be considered a significant finding only when LV cavity is not dilated.

*Hell J Nucl Med 2009; 12(2): 132-137 • Published on line: 27 July 2009*

## Introduction

Since left bundle branch block (LBBB) may be accompanied with ischemic heart disease (IHD) and hypertension, diagnosis of coronary artery disease (CAD) in LBBB patients is important [1]. In LBBB patients the exercise stress test is inconclusive [2] so an alternative non-invasive method, myocardial perfusion imaging (MPI) is being used for screening purposes [2-4]. Although pharmacologic stress is the preferred method for MPI [5], various false positive test results mainly in the septal wall have been reported with this method [2, 4-6], indicating, false hypoperfusion of the septal wall. On the other hands angiography as a gold standard may not be used routinely in these patients because of its relatively high cost and possible complications. Many MPI studies with pharmacologic stress have reported paradoxical results for the diagnosis of ischemia in patients with LBBB, probably due to different radiotracers, different methods used or to nuclear physicians interpretation [7, 8]. In some of these studies, any decrease in myocardial perfusion regardless its severity or extent has been considered positive [2, 9], while in other studies, decreased perfusion in the territory of left anterior descending (LAD) artery is deemed as positive only in the presence of special conditions such as the reversibility or the extension of the defects to the apex or to other LV walls [6, 7, 10-12]. The aim of this study was to assess the value of different patterns of MPI interpretation in patients with LBBB. Finding the best interpretation pattern may enhance the accuracy of MPI in the diagnosis of CAD in this group of patients.

## Methods

### Patients

Forty-two consecutive patients, 23 female and 19 male of mean age:  $61.3 \pm 11.7$ , range: 38-80

years, with LBBB and clinical suspicion of IHD were enrolled in this prospective study. The inclusion criteria were: LBBB pattern on the electrocardiogram (ECG) along with intermediate pre-test probability for CAD based on gender, risk factors and cardiac complaints, including typical or atypical chest pain, exertional dyspnea, palpitation and easy fatigability [13]. Patients with history of asthma, chronic obstructive pulmonary disease, high degree of the atrio-ventricular block and allergy to dipyridamole were excluded from the study. Following approval from the Medical Ethics Committee of our University, written informed consent was obtained from all patients.

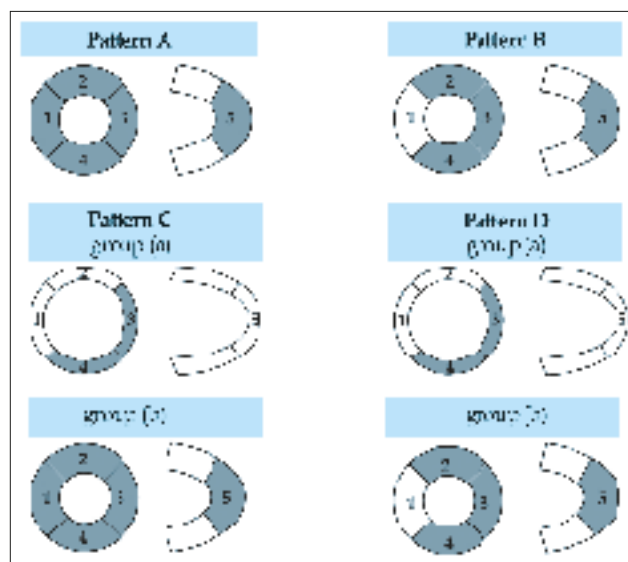
### Image acquisition

For MPI the patients were instructed to fast for at least 4h before the study. All  $\beta$ -blocking medications, diltiazem and verapamil were stopped 48h before the stress phase. Also caffeine containing drugs and foods and long-acting aminophylline were discontinued for at least 24h. A commercial sestamibi kit (AEOI, Tehran, Iran) was used and the labeling and quality control procedures were performed according to the manufacturer's instructions. A dose of 666-814MBq was given 4min following the standard pharmacological stress with intravenous injection of 0.56mg/kg dipyridamole over a 4min period. In the presence of dipyridamole side effects such as vertigo, chest pain, headache and electrocardiography changes, 250mg aminophylline was slowly injected intravenously 5min after radiotracer injection. Single photon emission tomography (SPET) with standard acquisition protocol was performed about 60min after radiotracer injection, using a rotating, dual head gamma camera (Solus, ADAC, Milpitas, CA) equipped with a low-energy high resolution parallel hole collimator. A 15% window around the 140keV energy peak of  $^{99m}\text{Tc}$ -sestamibi was used. Patients were in supine position during the image acquisition. Thirty-two azimuth images, 30s/projection, were obtained in a 180-degree circular orbit, beginning from 45 degrees right anterior oblique to 135 degrees left posterior oblique with step and shoot acquisition on a 64x64x16 matrix and 38.5cm detector mask (1.22 zoom). Rest images were obtained in the following day using the same imaging protocol. No attenuation correction was carried out in the imaging process.

### Image analyses and interpretation

Reconstruction of the images was carried out by *Pegasys* software (ADAC system). An expert nuclear physician used the cine-display of the rotating planar projections to assess sub-diaphragmatic activities, attenuations and patient motion to optimize the technical quality of the images. The raw data were prefiltered by ramp and subsequently by Butterworth filters with frequency cut-off of 0.45 and order of 9. Also the data were quantitatively processed using Auto-QUANT software package (Cedars-Sinai Medical Center) and left ventricular (LV) chamber size was measured. Regarding the LV chamber size, the patients were classified into two groups; group (a): fixed LV cavity dilatation with chamber size more than 90mL in both stress and rest phases with stress to rest ratio

less than 1.2, and Group (b): normal LV cavity size with chamber size equal or less than 90mL in stress or rest phases or transient LV cavity dilatation with stress to rest phase LV chamber size more than 1.2. The perfusion defects and corresponding reversibility were graded on a 5-point scale (0: normal, 1: complete reversible, 2: partial reversible, 3: fixed decreased and 4: fixed absent perfusion). Another classification to Groups I and II was carried out based upon the presence or absence of fixed defect(s) (grade 3 and 4) in the septal/anteroseptal region of the myocardium. Standard coronary artery regions were used to assign each perfusion abnormality to a major coronary artery [14]. MPI was interpreted by three expert nuclear physicians according to the following four patterns of interpretation (Fig. 1); *Pattern A*: any reversible or irreversible perfusion abnormality in the myocardium irrespective of the location or extension was considered positive. *Pattern B*: any reversible or irreversible perfusion abnormalities except in the septal/anteroseptal region were defined as positive. *Pattern C*: without fixed LV cavity dilatation (Fig. 1, pattern C, Group b), the scan was interpreted the same as in pattern A, while in the presence of fixed LV cavity dilatation, only the abnormalities outside the LAD territory was defined as positive (Fig. 1, pattern C, Group a). *Pattern D*: without fixed LV cavity dilatation, the scan was interpreted as in pattern B while in the presence of fixed LV cavity dilatation, the scan was read as in pattern C Group a (Fig. 1).



**Figure 1.** Four different patterns for interpretation of myocardial perfusion findings in left bundle branch block patients. The shaded regions are positive areas of interest for the interpretation of perfusion defects. The perfusion abnormalities in non-shaded areas are not included in the final interpretation with the corresponding pattern of scan reading (Group (a): myocardium with fixed LV dilatation; Group (b): myocardium without fixed LV dilatation).

MPI results were recorded separately according to all four interpretation patterns. To accomplish unbiased interpretation, the sessions for scan reading with different patterns were at least one week apart. Final diagnosis was reached by consensus. The nuclear physicians were unaware of the angi-

ographic findings and of previous diagnoses. All patients underwent coronary angiography by the referring cardiologist within a maximum 6 months interval after MPI and the findings were reported by consensus of two expert cardiologists who were unaware of the MPI results. Significant CAD was defined as at least 50% stenosis in one or more main coronary arteries or their major branches. Patients who did not undergo coronary angiography during this 6 months period were excluded from the study. The MPI results for each pattern of interpretation were compared to coronary angiography being the gold standard.

**Statistical analyses**

SPSS software (11.5) was used for data analysis. The “false positive ratio” (FPR) was defined as a fraction of patients with positive MPI and negative angiography among all or special group of cases. As well, the proportional frequency of patients with negative MPI and positive angiography was described as “false negative ratio” (FNR). The sensitivity, specificity, positive predictive value (PPV), negative predictive value (NPV) and accuracy were calculated based on each pattern of interpretation. Cochran Q test was used for comparison of related proportions (sensitivity and specificity) obtained with different patterns of interpretation. Also Chi square and two-sided Fisher exact tests were applied to compare the results of unpaired subgroups of the patients. A P value of less than 0.05 was considered statistically significant for all analyses.

**Results**

Out of 42 patients, seventeen (40.5%) had abnormal coronary angiography, while 25 (59.5%) patients showed normal coronary arteries. Twelve cases (28.6% of all cases or 70.5% of patients with CAD) showed significant stenosis of the LAD artery or one of its major branches. On myocardial perfusion images, 35/42 patients (83.3%) showed perfusion abnormalities in the myocardium and 7 patients showed normal MPI. Eight of the 35 cases showed reversible abnormalities, 17/35 showed irreversible fixed defects in the septal/antrioseptal regions with or without extension beyond this area and only 10/35 cases showed perfusion abnormalities limited to the areas outside the septal/antrioseptal regions (inferior/lateral/anterior/apical walls).

Considering any perfusion abnormalities in the entire myocardium as a positive result (Pattern A), 18 patients had negative angiography with positive MPI, leading to a total FPR of 42.9% among all patients (18/42) while no case showed positive angiography with negative MPI that means FNR of 0% and sensitivity of 100% for pattern A. The sensitivity, specificity, PPV and NPV of MPI for diagnosis of CAD based on different interpretation patterns in all cases and the difference between subgroups of patients based on gender are summarized in Table 1.

Among patients with no perfusion defects in the septal/antrioseptal region (17 cases), 7 had positive angiography of

**Table 1.** Comparison of different patterns of MPI interpretation in our male and female patients concerning the sensitivity, specificity, PPV and NPV for diagnosis of CAD based on angiographic results as gold standard.

Interpretation pattern of MPI	Diagnostic value parameters	Total (42 cases)	Male patients (19 cases)	Female patients (23 cases)	Significance of difference between male and female subgroups
Pattern A	Sensitivity	100.0% (17/17)	100.0% (13/13)	100.0% (4/4)	P=1.000 NS*
	Specificity	28.0% (7/25)	66.7% (4/6)	15.8% (3/19)	P=0.032
	PPV	48.6% (17/35)	86.7% (13/15)	20.0% (4/20)	P<0.0001
	NPV	100.0% (7/7)	100.0% (4/4)	100.0% (3/3)	P=1.000 NS*
Pattern B	Sensitivity	82.4% (14/17)	76.9% (10/13)	100.0% (4/4)	P=0.541 NS*
	Specificity	48.0% (12/25)	100.0% (6/6)	31.6% (6/19)	P=0.005
	PPV	51.9% (14/27)	100% (10/10)	23.5% (4/17)	P<0.0001
	NPV	80.0% (12/15)	66.7% (6/9)	100.0% (6/6)	P=0.229 NS*
Pattern C	Sensitivity	100.0% (17/17)	100.0% (13/13)	100.0% (4/4)	P=1.000 NS*
	Specificity	48.0% (12/25)	83.3% (5/6)	36.8% (7/19)	P=0.073 NS*
	PPV	56.7% (17/30)	92.9% (13/14)	25.0% (4/16)	P<0.0001
	NPV	100.0% (12/12)	100.0% (5/5)	100.0% (7/7)	P=1.000 NS*
Pattern D	Sensitivity	88.2% (15/17)	84.6% (11/13)	100.0% (4/4)	P=1.000 NS*
	Specificity	56.0% (14/25)	83.3% (5/6)	47.4% (9/19)	P=0.180 NS*
	PPV	57.7% (15/26)	91.7% (11/12)	28.6% (4/14)	P<0.0001
	NPV	87.5% (14/16)	71.4% (5/7)	100.0% (9/9)	P=0.175 NS*
Significance of difference between patterns	Sensitivity	P=0.061 NS*	P=0.061 NS*	P=1.000 NS*	
	Specificity	P=0.011	P=0.261 NS*	P=0.021	

\*NS: Not significant, MPI: myocardial perfusion imaging, PPV: positive predictive value, NPV: negative predictive value

whom all showed perfusion defects outside the septal/anteroseptal region, while 3 patients showed normal angiography in the presence of perfusion defects outside the septal/anteroseptal region. FPR and FNR were 17.6% (3/17) and 0%, respectively. Out of the 25 patients with perfusion defect(s) (17 fixed and 8 reversible defects) in the septal/anteroseptal region with or without extension, only 10 patients had positive angiography: 60% (15/25) FPR. Comparing FPR between the two groups of patients with and without defects in septal/anteroseptal region, significant difference was noted ( $P=0.006$ ).

In Group (a) with fixed LV cavity dilatation (16 cases), all patients showed significant perfusion abnormality on MPI, while only 8 cases revealed positive angiography (FPR: 50%). On the other hand, in the Group (b) with normal LV cavity or transiently dilated LV cavity (26 cases), false positive MPI results were found in 9 patients (34.6%), resulting in no statistically significant difference ( $P=0.163$ ); However, FPR between Groups (a) and (b) in female patients, showed a significant difference; 100% (7/7) for Group (a) vs. 56.3% (9/16) for Group (b),  $P=0.036$ . In males, FPR was 11.1% (1/9) in Group (a) and 0 in Group (b).

The overall accuracy of MPI was 57.1%, 61.9%, 69.0% and 69.0%, for patterns of A, B, C and D, respectively. The accuracy of MPI in males for the same patterns were 89.5%, 84.2%, 94.7% and 84.2%, respectively and in females were 30.4%, 43.5%, 47.8% and 56.5%, respectively.

Based on the presence of fixed defects in the septal/anteroseptal region, patients were classified into Groups (I) (with normal or reversible perfusion defects in the septal/anteroseptal region) and (II) (with fixed defects in the septal/anteroseptal region). The sensitivity, specificity, FPR, FNR and accuracy of MPI was compared using inter- and intra-groups analyses for different patterns of reading (Table 2).

### Discussion

Although MPI with pharmacologic stress is the standard non-invasive method for screening of CAD in LBBB patients, controversies remain about the correct pattern of interpretation of the scintigraphic image. Previous studies have not compared the different patterns of interpretation in the same group of LBBB patients using dipyridamole MPI. We have tried

**Table 2.** Diagnostic value of MPI with 4 patterns of interpretation in different group of patients based on the presence or absence of fixed defect in the septal/anteroseptal myocardial region

Interpretation Pattern of MPI	Group*	Sensitivity	Specificity	FPR	FNR	Accuracy
Pattern A	(a)	100% (12/12)	53.8% (7/13)	24% (6/25)	0%	76% (19/25)
	(b)	100% (5/5)	0%	70.6% (12/17)	0%	29.4% (5/17)
	Inter-group difference	$P=1.000$ NS**	$P<0.0001$	$P=0.003$	-	$P=0.003$
Pattern B	(a)	91.7% (11/12)	61.5% (8/13)	20.0% (5/25)	4.0% (1/25)	76.0% (19/25)
	(b)	60.0% (3/5)	33.3% (4/12)	47.1% (8/17)	11.8% (2/17)	41.2% (7/17)
	Inter-group difference	$P=0.191$ NS	$P=0.158$ NS	$P=0.063$ NS	$P=0.556$ NS	$P=0.023$
Pattern C	(a)	100% (12/12)	61.5% (8/13)	20.0% (5/25)	0%	80.0% (20/25)
	(b)	100% (5/5)	33.3% (4/12)	47.1% (8/17)	0%	52.9% (9/17)
	Inter-group difference	$P=1.0$ NS	$P=0.158$ NS	$P=0.063$ NS	-	$P=0.043$
Pattern D	(a)	100% (12/12)	61.5% (8/13)	20.0% (5/25)	0%	80.0% (20/25)
	(b)	60.0% (3/5)	50.0% (6/12)	35.3% (6/17)	11.8% (2/17)	52.9% (9/17)
	Inter-group difference	$P=0.020$	$P=0.564$ NS	$P=0.268$ NS	$P=0.158$ NS	$P=0.043$
Significance of intra-group difference between patterns	(a)	$P=0.392$ NS	$P=0.733$ NS	$P=0.980$ NS	$P=0.392$ NS	$P=0.753$ NS
	(b)	$P=0.112$ NS	$P=0.016$	$P=0.016$	$P=0.112$ NS	$P=0.221$ NS

\* Group (I) (25 cases): without fixed perfusion defect(s) in the septal/anteroseptal region, Group (II) (17 cases): with fixed perfusion defect(s) in the septal/anteroseptal region

\*\* NS: Not significant, FPR: false positive ratio, FNR: false negative ratio

to find the best pattern for interpretation of MPI in a series of patients with LBBB to achieve the highest accuracy for screening CAD. We started by considering different patterns of reading in LBBB patients, irrespective of the presence of reversibility or non-reversibility of the defects in septal/anteroseptal regions. In all these patterns, the NPV and the sensitivity of MPI were more than 80% and even reached to higher values (up to 100%) in the subgroup of female patients, however, the specificity in this subgroup was very low. In addition, no significant difference in sensitivity for screening CAD was noted between different patterns of interpretation. Despite the difference in interpretation approaches, similar results have been reported in previous studies [4, 5]. In 19 LBBB patients who underwent dipyridamole MPI test, 14 had normal MPI with no evidence of CAD on coronary angiography or over a long-term follow up leading to NPV of 100% [4]. These investigations along with our results confirm the usefulness of MPI regardless of the pattern of interpretation for excluding CAD in patients with LBBB; however even after dipyridamole stress test, interpretation of MPI patterns remain a concern when perfusion defects are noted in the LAD area.

In our study, the PPV for MPI, irrespective of other criteria, such as LV cavity size, location and extension of the perfusion defects was 48.6% and the specificity of the test was 28%. These values significantly differed when LV size and the site of abnormality were considered. In the above mentioned study [4], 5/19 patients with LBBB had abnormal MPI findings in the septum area. Three of them had no evidence of CAD in coronary angiography, 1 had angiographically-detected LAD artery stenosis, and 1 died from CAD [4]. Others compared the scintigraphic results of both pharmacologic and exercise stress tests in 12 patients with LBBB [2]. Six patients had abnormal dipyridamole MPI of whom coronary angiography was normal in 3. In our study by using pattern D that reflected both the extent of the defects and LV cavity size, the specificity significantly rose from 28% to 56%, which was in contrast with the above findings [2]. A reasonable explanation for this discrepancy is the difference between studied population and sample size, which was too small to achieve a significant difference. Also, all patients of the above study had septal or anteroseptal perfusion defects on exercise thallium-201 ( $^{201}\text{Tl}$ ) SPET test, while LBBB patients were included in our study irrespective of the scan findings.

As false perfusion abnormalities are usually seen in the septum and the anterior myocardial walls, some investigators believe that perfusion abnormalities in the inferior wall are stronger predictors of CAD [6, 10]. Some others believe that abnormal perfusion in the apex along with anteroseptal perfusion abnormalities are more specific predictors of LAD artery stenosis [11, 12]. This finding was also encountered by our study but not by some others [2]. Pattern B -coexisting defects outside the septal/anteroseptal region- was more specific than pattern A. This alternative interpretation approach had been previously employed using exercise  $^{201}\text{Tl}$ -SPET study and was showed to be superior to the conventional approach [15].

When considering any perfusion abnormalities as a positive result, we found that the FPR in the subgroup of fixed LV dilatation was much higher than that of normal or transiently dilated LV cavity (50% vs 38.5%). The diagnosis was based on quantitative analysis by the Auto-Quant software. Relatively similar findings have been reported by others [16], who showed that in the subgroup of LBBB with fixed LV dilatation, the FPR of scan for diagnosis of CAD was 65%. However, regardless the LV size, this value for the entire population of patients was 39%, showing lower specificity and accuracy in LBBB patients with dilated LV cavity. These defects may be similar to those noticed in patients with LV hypertrophy and/or dilatation [16-19]. Another report showed that patients with LBBB often had associated CAD or nonischemic cardiomyopathies. In addition, LV cavity enlargement is often seen in LBBB, irrespective of CAD [20]. Other studies have shown evidence of diffuse fibrosis in the septal wall and also correlation between LV dilatation and the severity of perfusion abnormalities, not necessarily due to CAD [21, 22]. Several mechanisms have been suggested to explain these observations: Downregulated perfusion secondary to diminished oxygen demand, increased intra-myocardial pressure during diastole, fibrotic alterations, or pronounced partial-volume effects due to reduced wall thickening, especially in the presence of imperfect spatial resolution of gamma camera [3, 5, 6, 23-25]. Another study supports the theory of PVE being more pronounced in the anterior and septal walls, which are thinner than usual due to cardiomyopathy [26]. In the above study, 293 symptomatic LBBB patients had undergone exercise or pharmacologic MPI. In most of these patients, the underlying cardiac disease (CAD, cardiomyopathy or both) was not specified. The most important predicting factors for cardiac events were the size of myocardial perfusion defect and increased pulmonary uptake of thallium. Left ventricular cavity was more dilated in patients who experienced cardiac events. Scintigraphic findings, between the exercise and pharmacological MPI groups were similar. These investigators recommended that LV cavity size should be included in the interpretation process of MPI [26].

A new finding in our study was the significant difference in FPR between sexes. In case of dilated LV, any perfusion defects in the region of LAD are more likely to be false positive in female than in male patients. This may be due to breast attenuation and/or to the size of LV cavity and/or to increased tachycardia in women [12, 27]. It has been suggested that medication with a beta-blocker in women with LBBB seems to decrease the proportion of FPR [28]. In our study, the best pattern for interpretation of MPI in female patients was pattern D which includes "the absence of LV cavity dilatation" as one of its main features for reporting positive results. In the male group of our study, the overall accuracy of MPI was not significantly influenced by the dilated LV or the pattern of interpretation; however, the size of the LV may be a prognostic factor for the disease [26].

In the subgroup of our patients with fixed defects in the septal/anteroseptal region, the specificity and accuracy were

very low by any pattern and pattern D was the best approach to achieve the higher specificity, accuracy and the lower FPR. On the other hand, in the group with normal perfusion or perfusion reversibility between stress and rest tests in septal/anteroseptal region, the specificity and accuracy were appreciably higher and were not influenced by the pattern of interpretation. A similar result was found by other investigators [7, 12, 29]. Reversible septal defects, especially at the end of diastole accompanied by a concomitant apical defect and systolic dysfunction matching the perfusion defect, have been reported as the key findings that define true positives of MPI in LBBB patients [29].

*In conclusion*, the results of this study indicate that: a) in female LBBB patients without LV dilatation, perfusion defects out of the septal and the anteroseptal wall are more likely suggestive of CAD. b) In the presence of fixed LV dilatation, fixed septal/anteroseptal perfusion defects usually are false positive findings for CAD in this group. c) In the male population without fixed defects in the septal/anteroseptal region, the specificity and accuracy are high in all patterns and the pattern of reading does not significantly influence the diagnostic value of MPI for CAD screening. d) In LBBB patients, fixed defects limited to the septal/anteroseptal region should be considered a significant finding only when LV cavity is not dilated.

#### Acknowledgment

This research has been supported by Tehran University of Medical Sciences, Tehran, Iran, grant no 1788. The authors are indebted to the technologists, especially Mrs. Darvishha and Mr. Ahmadin at our institute for their technical assistance.

#### Bibliography

- Noble LM, Humphrey SB, Monaghan GB. Left ventricular hypertrophy in left bundle branch block. *J Electrocardiol* 1984; 17: 157-160.
- Lebtahi NE, Stauffer JC, Delaloye AB. Left bundle branch block and coronary artery disease: accuracy of dipyridamole thallium-201 single-photon emission computed tomography in patients with exercise anteroseptal perfusion defects. *J Nucl Cardiol* 1997; 4: 266-273.
- Hasegawa S, Sakata Y, Ishikura F et al. Mechanism for abnormal thallium-201 myocardial scintigraphy in patients with left bundle branch block in the absence of angiographic coronary artery disease. *Ann Nucl Med* 1999; 13: 253-259.
- Rockett JF, Wood WC, Moinuddin M et al. Intravenous dipyridamole thallium-201 SPECT imaging in patient with left bundle branch block. *Clin Nucl Med* 1990;15: 401-407.
- Burns RJ, Galligan L, Wright LM et al. Improved specificity of myocardial thallium-201 single photon emission computed tomography in patient with left bundle branch block by dipyridamole. *Am J Cardiol* 1991; 68: 504-508.
- Wackers FJT. Myocardial perfusion defect in left bundle branch block: true or false? Fact or artifact? *J Nucl Cardiol* 1997; 4: 550-552.
- Möller J, Warwick J, Bouma H. Myocardial perfusion scintigraphy with Tc-99m MIBI in patients with left bundle branch block: Visual quantification of the anteroseptal perfusion imaging for the diagnosis of left anterior descending artery stenosis. *Cardiovasc J S Afr* 2005; 16: 95-101.
- Ellmann A, van Heerden PD, van Heerden BB et al. <sup>99m</sup>Tc-MIBI stress-rest myocardial perfusion scintigraphy in patients with complete left bundle branch block. *Cardiovasc J S Afr* 2001; 12: 252-256.
- DePuey EG, Guerler-Krawczynska E, Robbins WL. Thallium SPECT in coronary artery disease patients with left bundle branch block. *J Nucl Med* 1988; 29: 1479-1485.
- Bratt SH, Brugada P, Bar FW et al. Thallium-201 exercise scintigraphy and left bundle branch block. *Am J Cardiol* 1985; 55: 224-226.
- Matzer L, Kiat H, Friedman JD et al. A new approach to the assessment of tomographic thallium-201 scintigraphy in patients with left bundle branch block. *J Am Coll Cardiol* 1991; 17: 1309-1317.
- Alexánder E, Manning F, Gómez-Martín D et al. Technetium-99m-Sestamibi SPECT myocardial perfusion imaging in patients with complete left bundle branch block. *Arch Med Res* 2004; 35: 150-156.
- Gibbons RJ, Balady GJ, Bricker JT et al. ACC/AHA 2002 guideline update for exercise testing summary article: a report of the American College of Cardiology/American Heart Association Task Force on Practice Guidelines (Committee to Update the 1997 Exercise Testing Guidelines). *Circulation* 2002; 106: 1883-1892.
- Germano G, Kavanagh PB, Waechter P et al. A new algorithm for the quantitation of myocardial perfusion SPECT. I: technical principles and reproducibility. *J Nucl Med* 2000; 41: 712-719.
- Tandoğan I, Yetkin E, Ileri M et al. Diagnosis of coronary artery disease with <sup>201</sup>Tl SPECT in patients with left bundle branch block: importance of alternative interpretation approaches for left anterior descending coronary lesions. *Angiology* 2001; 52: 103-108.
- Vigna C, Stanislao M, De Rito V et al. Dipyridamole stress echocardiography vs dipyridamole sestamibi scintigraphy for diagnosing coronary artery disease in left bundle-branch block. *Chest* 2001; 120: 1534-1539.
- Dunn RF, Uren RF, Sadick N et al. Comparison of thallium-201 scanning in idiopathic dilated cardiomyopathy and severe coronary artery disease. *Circulation* 1982; 66: 804-810.
- Legrand V, Hodgson JM, Bates ER et al. Abnormal coronary flow reserve and abnormal radionuclide exercise test results in patients with normal coronary angiograms. *J Am Coll Cardiol* 1985; 6: 1245-1253.
- Sinusas AJ, Shi Q, Vitols PJ et al. Impact of regional ventricular function, geometry, and dobutamine stress on quantitative <sup>99m</sup>Tc-sestamibi defect size. *Circulation* 1993; 88: 2224-2234.
- Sugiura M, Hiraoka K, Ohkawa S et al. A clinicopathological study on 25 cases of complete left bundle branch block. *Jpn Heart J* 1979; 20: 163-176.
- Hodge J, Mattera J, Fetterman R. False positive thallium-201 defects in left bundle branch block: relationship to left ventricular dilation. *J Am Coll Cardiol* 1987; 9: 139A.
- Galt J, Garcia E, Robbins W. Effects of myocardial wall thickness on SPECT quantification. *IEEE Trans Med Imaging* 1990; 9: 144-150.
- Sugihara H, Tamaki N, Nozawa M et al. Septal perfusion and wall thickening in patients with left bundle branch block assessed by technetium-99m-sestamibi gated tomography. *J Nucl Med* 1997; 38: 545-547.
- Ono S, Nohara R, Kambara H et al. Regional myocardial perfusion and glucose metabolism in experimental left bundle branch block. *Circulation* 1992; 85: 1125-1131.
- Carew TE, Covell JW. Effect of intramyocardial pressure on the phasic flow in the interventricular septal artery. *Cardiovasc Res* 1976; 10: 56-64.
- Nallamothu N, Bagheri B, Acio ER et al. Prognostic value of stress myocardial perfusion imaging in patients with left bundle branch block. *J Nucl Cardiol* 1997; 4: 487-493.
- Patel R, Bushnell DL, Wagner R et al. Frequency of false-positive septal defects on adenosine/201Tl images in patients with left bundle branch block. *Nucl Med Commun* 1995; 16: 137-149.
- Georgoulas P, Demakopoulos N, Wozniak G et al. False positive myocardial perfusion imaging in women with left bundle branch block. The effect of beta-blocker medication (abstr.). *J Nucl Cardiol* 2007; 14: S25.
- Higgins JP, Williams G, Nagel JS et al. Left bundle-branch block artifact on single photon emission computed tomography with technetium <sup>99m</sup>Tc-agents: mechanisms and a method to decrease false-positive interpretations. *Am Heart J* 2006; 152: 619-626.