

# Is sentinel node mapping useful in anorectal melanoma?

**Theodoros Mariolis-Sapsakos<sup>1</sup>,**  
**Julia Malamitsi<sup>2,3</sup>,**  
**Emmanuel Yakoumakis<sup>3</sup>,**  
**Filotheos Orfanos<sup>1</sup>**

1. Department of General Surgery and
2. Department of Nuclear Medicine  
Diagnostic and Therapeutic Center of Athens "Hygeia", Athens, Greece
3. Department of Medical Physics,  
Medical School,  
University of Athens,  
Athens Greece

☆☆☆

**Keywords:** Anorectal melanoma  
 – Lymphoscintigraphy  
 – Sentinel lymph node  
 – Wide local excision  
 – Abdominoperineal resection

## Correspondence address:

Assoc. Professor  
 Julia Malamitsi,  
 Department of Medical Physics,  
 Medical School,  
 University of Athens,  
 75 Mikras Asias,  
 P.C. 115 27, Athens, Greece.  
 Tel: +302107462370,  
 Fax: +302107462369  
 e-mail: j.malamitsi@yahoo.gr

## Received:

5 November 2007

## Accepted revised:

14 March 2008

## Abstract

Anorectal melanoma (AM) is a rare disease and few guidelines have been established regarding its therapeutic management. Wide local excision, or less frequently, abdominoperineal resection is the treatment of choice. *We present* a female patient with an excised AM who was submitted to our Nuclear Medicine department for sentinel lymph node (SLN) mapping of the area. Under rigid proctoscopy the anal scar received four submucosal injections of technetium-99m-sulfur nanocolloid of 29.6 MBq each. Lymphoscintigraphy and intraoperative  $\gamma$ -probe guided detection of the SLNs followed. SLNs were localized in the inguinal basins bilaterally and were negative on histology. A wide local excision followed the above test. Thirty months postoperatively the patient developed distant metastases, underwent radiotherapy and died six months later. Without changing prognosis sentinel lymph node detection, excision and histology were important in sparing the patient a futile inguinal lymph node dissection.

*Hell J Nucl Med 2008; 11(1): 39-42*

## Introduction

Anorectal melanoma (AM) is a rare malignant neoplasm, which accounts for less than 1% of all malignant tumors of the anorectal region. Since Moore first described anorectal melanoma in 1857, less than 500 cases of AM have been reported. Following head and neck and the female genitourinary system, anorectum is the third most common site accounting for 0.4% to 1.6% of all mucosal melanomas [1-8].

A higher incidence of AM has been reported in women than in men [9, 10], as well as in patients in the sixth or seventh decade of their lives [1]. The AM appears at the age between 27-85 years, with a median age of approximately 60 years [1]. The majority of patients reported are diagnosed rather late in the course of the disease, resulting in an extremely poor 5 year survival rate (0%-22%) [1, 11]. The depth of metastatic lesions as well as the stage of the disease usually determine prognosis. For the treatment of AM a choice has to be made between abdominoperineal resection (APR) and wide local excision (WLE) of the lesion. Lymph node dissection does not seem to affect the 5 year survival rate of AM when distant metastases are present [1, 12-14]. The lymphatic channels that drain the anorectum differ according to the tumor location and can lead to the superficial inguinal, to the hypogastric and obturator lymph nodes or when there are higher rectal lesions, to the mesenteric drainage pathway of the sigmoid and peri-aortic rectal groups [12, 15]. If there is no nodal disease at the time of operation, lymph node dissection is delayed until clinical disease develops. Since long-term survival rates have been reported for AM patients with minimal metastatic nodal disease who had undergone APR [13], sentinel lymph node (SLN) identification may have a prognostic value, estimate regional spread of the disease and define the need for adjuvant treatment.

We present a patient operated after the excision of the primary site of AM, discuss the importance of lymphoscintigraphy - SLN mapping technique and attempt a short review of the existing literature on treatment strategies.

## Description of the case

We studied a 59 year old woman complaining for the presence of a large polyp (2.5 cm in diameter), which on increased intra-abdominal pressure, was lapsing out of the rectum. The patient did not report rectal bleeding, weight loss or any other symptoms. Colonoscopy revealed a pedunculated polyp situated in the anorectal junction, just in the dentate line (Fig. 1), as well as another polyp in the sigmoid colon, 45 cm proximal to the anus. Endoscopic polypectomy was performed on both lesions. The histological evaluation revealed that the anorectal polyp was in fact a malignant melanoma 2.1 mm thick with unaffected resection margins, while the

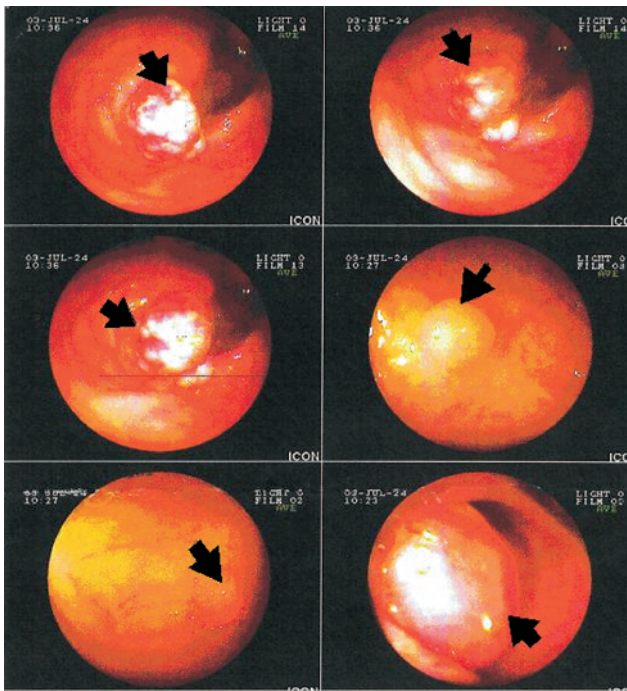


Figure 1. Endoscopic view of the melanoma at the dentate line (black arrows).

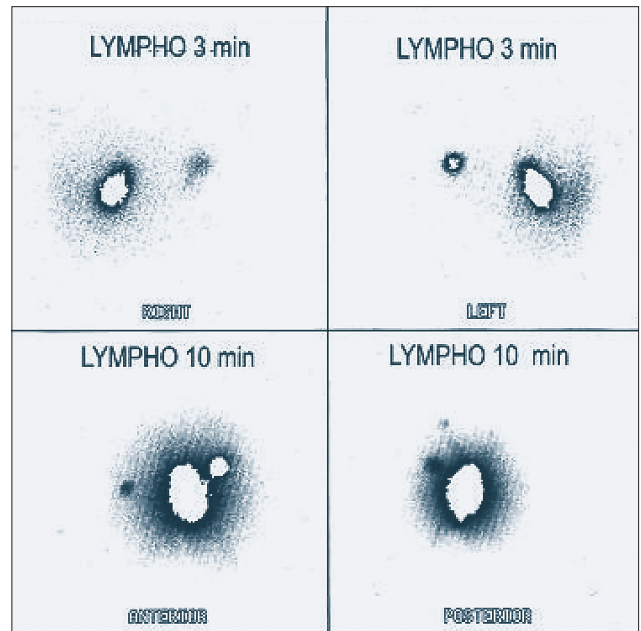


Figure 2. Lymphoscintigraphy with  $^{99m}\text{Tc}$ -sulfur nanocolloid and preoperative detection of the sentinel lymph nodes in the right and left inguinal basins.



Figure 3. A: Histology H-E  $\times 100$ , B: H-E  $\times 200$  and C: Immunohistology  $\times 400$  negative for melanoma infiltration.

sigmoid polyp was adenomatous, without any dysplasia. Extensive clinical examination, laboratory and radiological tests with whole body computerized tomography (CT) scan and transanal ultrasound (U/S) scan, one week after polypectomy, showed no metastases. Subsequently the patient underwent rigid proctoscopy and the anal scar resulting from previous polypectomy, received four submucosal injections of  $^{99m}\text{Tc}$ -sulfur-nanocolloid ( $^{99m}\text{Tc}$ -SNC) of 29.6 MBq each, in order to determine SLNs. Planar lymphoscintigraphy was performed after the injection, in order to visualise the lymphatic drainage and the SLNs. Three minutes post injection the acquisition of lymphoscintigraphy was initiated. Anterior, posterior and lateral views were taken on a dual headed  $\gamma$ -camera (PRISM 2000 Philips-Marconi Odyssey SX780) for thirty minutes. The SLNs were externally detected by a  $\gamma$ -probe (Scintiprobe MR100 POL Hitech) and their location was marked on the skin. After surgical excision of the right and left inguinal SLNs and before taking them to the Pathology Department, an ex vivo scan of the lymph nodes was acquired.

## Results

Three minutes postinjection, two SLNs were detected, initially in the left and then in the right inguinal basin respectively (Fig. 2). After one hour, the patient was admitted to the operating room where she underwent a WLE of the anal scar region and a resection of the marked inguinal SLNs, guided by intraoperative use of the  $\gamma$ -probe. The surgeons also performed bilateral iliac lymph node biopsy. After resection and ex vivo imaging, the SLNs and all resected nodes were submitted to histology (haematoxylin-eosin- H/E stain and immunohistology always performed on malignant melanomas) which showed no evidence of malignancy (Fig.3). PCR on tissue specimen was also negative. Thirty months postoperatively the patient developed distant metastases to the left iliac lymph nodes, the liver, the lungs and a metastatic infiltration of the left iliac bone. The patient was subjected to radiotherapy (RT) for the iliac bone infiltration, however she refused chemotherapy or immunotherapy and died after six months.



## Discussion

Anorectal melanoma is a neuroectodermal neoplasm originating from the melanoblastic cells of the mucosal surface [16, 17] and showing a statistically significant increase in frequency [18]. It shows a bimodal, age-dependent distribution, from 25 up to 44 years and over 65 years of age human immunodeficiency virus infection has been considered as a risk factor [18]. Survival rates seem to be better for younger males [18].

The most common clinical signs of AM are rectal bleeding and a mass, palpated in the rectum which is usually polypoid and several centimeters in diameter at the time of diagnosis, thus presenting clinically as localized advanced disease. The transitional zone of the anal canal consists of many different types of epithelium, including squamous epithelium. Melanin and junctional changes of atypical melanocytic cells are also seen at this area, which is thought to be the primary site of mucosal AM. These tumors tend to invade proximally into the rectal submucosa, leading to the formation of a bulky, polypoid mass that protrudes into the anal canal. Endoscopy usually shows black pigmentation in a nodule with ulceration and friability. However, up to 30% of AM are amelanotic and may not be recognised, at early stages [19, 20]. Diagnosis is usually based on clinical examination, endoscopy and biopsy of the lesion. Endoluminal ultrasound (ELUS) has evolved as a simple yet valuable tool in providing an accurate assessment of the tumor's invasion in depth and the existence or not of perirectal nodes [17, 21]. CT scan and/or MRI are useful in evaluating local extent of the disease, as well as identifying distant metastases.

The use of  $\gamma$ -camera LS and intraoperative  $\gamma$ -probe in AM, offer a significant assistance to SLN detection [22-26]. After the inguinal SLNs are examined histologically, immunohistologically and with the polymerase chain reaction technique and found free of malignancy, lymph node excision of the inguinal area is not performed as it may present a respectable morbidity [23]. When only micrometastases are found, the excision of these nodes possibly increases survival [27]. The presence of SLN at the mesorectum necessitates fine needle aspiration (FNA) biopsy assisted by ELUS and if malignancy is found APR is indicated. If AM is local or the general condition of the patient is poor, then RT and possibly immunotherapy are applied.

There are very few reports of SLN mapping in AM [22-24]. It has been reported that an AM patient with several SLNs detected by lymphoscintigraphy and excised under intraoperative  $\gamma$ -probe guidance (two iliac, two inguinal, one intermediary and one mesorectum lymph nodes) found free of metastases, remained alive and without metastases fifty months thereafter [25]. A patient with AM without evidence of metastases in the inguinal and iliac SLNs remained free of metastases after six months, while in the same study another AM patient with an inguinal SLN positive for micrometastases died, despite therapy, of systemic dissemination thirty six months later [26]. Inguinal lymph node metastases from AM are found only in 14%, while in squamous-cell carcinoma these metastases have been found in 42% [28].

The depth of invasion as determined by Breslow thickness

was found to be an important prognostic factor [29-31]. The size of the AM tumor is also important. Patients with tumors thinner than 2.5 mm on first diagnosis who underwent APR were the only long term survivors [1, 32]. Concerning localized axial melanoma, in a predicting survival and recurrence study, patients with localized axial melanoma of less than 2.5 mm thickness had a predicted 5 year survival rate of 76% and above, and a 10 year survival rate of 67% and above respectively [33].

The patient studied in this case report had a 2.1 mm thick AM. Inguinal SLNs and bilateral iliac lymph node biopsies were negative for malignancy. Despite the negative results of lymph node histology, immunohistology and PCR our patient developed left iliac lymph node metastases and systemic dissemination of the disease and died thirty six months after initial WLE. The above indicate that due to the fast dissemination of AM, negative lymph nodes may soon become positive and that some of the detected SLNs by LS and intraoperative  $\gamma$ -probe, may be positive for micrometastases even after a negative immunohistological and a PCR examination. In our case although the use of SLN mapping was not predictive of patient evolution, the presence of negative SLNs in the inguinal basins at the time of examination spared the patient a futile extensive lymph node dissection in these regions.

For many years APR was the sine qua non in the treatment of AM, regardless of any prognostic parameters [28]. A study from Mayo Clinic has stated that the five year survival and recurrence rates were identical after either APR or WLE, performed with an intention to cure [2, 32].

A study of eighteen patients with an AM of small thickness, showed that aneuploidy is related to worse tumor behavior, whereas when the percentage of the cancer cells in S phase are less than 10%, the prognosis is improved [34].

After surgical treatment of AM, local recurrence is quite frequent. It has also been shown that local recurrence is indicative of the presence of distant metastases and therefore a poor prognostic factor [14]. Since the survival and recurrence rates appear to be similar after either APR or WLE, it seems reasonable to recommend WLE when it is technically feasible to ensure normal resection margins and reserve APR for cases that cannot be resected by local excision or for the control of patients with isolated local recurrence [2]. Removal of lymphatics of the mesorectum does not seem to influence the prognosis [2, 9, 25, 26, 32].

There is a long-standing debate about the role of RT in AM because it does not significantly improve survival, since melanomas are thought to be radio-resistant [2, 33]. On the other hand a small number of patients with bulky AM tumors seem to have benefited after treatment with RT [35]. It has been reported that an AM patient with locally advanced disease, who received 50 Gy of RT followed by WLE, remained free of the disease for thirty months [36]. In another report AM patients with locally advanced disease treated by colostomy in the transverse colon who received 50 Gy of RT, a local excision plus interferon- $\alpha$ -2b, plus WLE, had a median survival of only five months [37]. Taking the above into consideration, and in view of the limited data available, it is not possible to show the efficacy of adjuvant treatment with RT in mini-

mizing the risk of local and/or regional recurrence [38]. However, in locally aggressive melanomas, a higher dose of RT, plus WLE could offer the best therapeutic approach [35, 37]. Postoperative RT can also be helpful in cases of marginal excision, infiltrated lymph nodes, residual disease and local recurrence [14, 17, 37]. As a palliative treatment, RT is also used in extended local disease or metastases in the brain, bones etc [17, 35].

Immuno-stimulators as well as interferon and cytokines or high doses of interferon, vaccines, monoclonal antibodies or cisplatin, have also been tried, without significant survival gain [39, 40].

*In conclusion*, AM is a rare disease with poor prognosis. Most patients have distant metastases at the time of diagnosis. Prognosis seems to be related to the stage of the disease, the thickness and the depth of the tumor. Wide local excision with sufficient healthy margins or APR is the treatment of choice. The determination of SLNs may be useful for the staging and treatment of the disease, in patients with middle thickness melanomas without bulging lymph nodes or distant metastases, however existing literature does not offer concrete data on the usefulness of the SLN method on AM. In our case, SLN detection and histology was not sufficient in evaluating the patient's status and prognosis, but spared the patient a futile bilateral inguinal lymphadenectomy.

#### Acknowledgement

The authors wish to thank Doctors Maria Kyriazi, Nikolaos Orfanos, Dimitrios Vlachodimitropoulos and Nikolaos Goutas for their contribution.

#### Bibliography

- Brady MS, Kavolius JP, Quan SH. Anorectal melanoma: a 64-year experience at Memorial Sloan-Kettering Cancer Center. *Dis Colon Rectum* 1995; 38: 146-151.
- Thibault C, Sagar P, Nivatvongs S et al. Anorectal melanoma-an incurable disease? *Dis Colon Rectum* 1997; 40: 661-668.
- Konstadoulakis MM, Ricaniadis N, Walsh D, Karakousis CP. Malignant melanoma of the anorectal region. *J Surg Oncol* 1995; 58: 118-120.
- Whooley BP, Shaw P, Astrow AB et al. Long term survival after locally aggressive anorectal melanoma. *Am Surg* 1998; 64: 245-251.
- Tsigris C, Pikoulis E, Bramis J et al. Malignant melanoma of the anorectal area. Report of two cases. *Dis Surg* 2000; 17: 194-196.
- Ries LAG, Hankey BF, Miller BA et al. Cancer statistics review 1973-88. Bethesda, Md: *National Cancer Institute, NIH Pub. No. 91-2789*, 1991.
- Young JL, Percy CL, Asire AJ (eds). Surveillance, epidemiology, and end results: incidence and mortality data, 1973-77. *NCI Monogr* 1981; 57: 1-1082.
- Tomicic J, Wanebo HJ. Mucosal melanomas. *J Surg Clin N Am* 2003; 83: 237-252.
- Moore WD. Recurrent melanosis of the rectum after previous removal from the verge of the anus in a man aged 65. *Lancet* 1857; 1: 290-294.
- Weinstock M. Epidemiology and prognosis of anorectal melanoma. *Gastroenterology* 1993; 104: 174-178.
- Roumen RM. Anorectal melanoma in the Netherlands: a report of 63 patients. *Eur J Surg Oncol* 1996; 22: 598-601.
- Pack GT, Oropeza R. A comparative study of melanoma and epidermoid carcinoma of the anal canal: A review of 20 melanomas, and 29 epidermoid carcinomas (1930 to 1965). *Dis Colon Rectum* 1967; 10: 161-176.
- Slingluff CL, Vollmer RT, Seigler HF, Durham NC. Anorectal melanoma: clinical characteristics and results of surgical management in 24 patients. *Surgery* 1990; 107: 1-9.
- Ross M, Pezzi CH, Pezzi TH et al. Patterns of failure in anorectal melanoma. *Arch Surg* 1990; 125: 313-316.
- Quan SH, Deddish MR. Non-cutaneous melanoma: Malignant Melanoma of the anorectum. *Cancer* 1969; 16: 111-114.
- Ross MI, Stern SJ, Wanebo HJ. Mucosal melanoma. In: Balch, CM, Houghton AN eds *Cutaneous Melanoma*. Philadelphia: Lippincott Williams & Wilkins; 2<sup>nd</sup> edn 1992; pp. 325-335.
- Baltazar EJ, Javors B. The radiology corner. Anorectal melanoma. *Am J Gastroenterol* 1975; 63: 79-83.
- Cagir B, Whiteford MH, Topham A et al. Changing epidemiology of anorectal melanoma. *Dis Colon Rectum* 1999; 42: 1203-1208.
- Weinstock MA. Epidemiology and prognosis of anorectal melanoma. *Gastroenterology* 1993; 104: 174-178.
- Gupta R, Rathi PM, Sawant P et al. Endoscopic appearance of primary anorectal melanoma. *Endoscopy* 1997; 29: 230.
- Antoniuk PM, Tjandra JJ, Webb BW et al. Anorectal malignant melanoma has a poor prognosis. *Int J Colorectal Dis* 1993; 8: 81-86.
- Tien HY, Mc Masters KM, Edwards MJ, Chao C. Sentinel lymph node metastasis in anal melanoma: a case report. *Int J Gastrointest Cancer* 2002; 32: 53-56.
- Bobin JY, Gerard JP, Chapet O et al. Lymphatic mapping and inguinal sentinel lymph node biopsy in anal canal cancers to avoid prophylactic inguinal irradiation. *Cancer Radiother* 2003; 7 Suppl 1: 85s-90s.
- Olsha O, Mintz A, Gimon Z et al. Anal melanoma in the era of sentinel lymph node mapping: a diagnostic and therapeutic challenge. *Tech Colo-proctol* 2005; 9: 60-62.
- Duport C, Tiffet O, Perrot JL et al. Sentinel node mapping in anorectal melanoma. *Annales de Chirurgie* 2006; 131: 550-552.
- Sanli Y, Turkmen C, Kurul S et al. Sentinel lymph node biopsy for the staging of anal melanoma: Report of two cases. *Ann Nucl Med* 2006; 20: 629-631.
- Morton DL, Thomson JF, Essner R et al. Validation of the accuracy of intraoperative lymphatic mapping and sentinel lymphadenectomy for early-stage melanoma: a multicenter trial. Multicenter Selective Lymphadenectomy Trial Group. *Ann Surg* 1999; 230: 453-463 (discussion: 463-465).
- Quan SH, Deddish MR. Noncutaneous melanoma of the anorectum. *Cancer* 1966; 16: 111-114.
- Angeras U, Jonsson N, Jonsson P. Primary anorectal malignant melanoma. *J Surg Oncol* 1983; 22: 261-264.
- Kantarovsky A, Kaufman Z, Zager M et al. Anorectal region malignant melanoma. *J Surg Oncol* 1988; 38: 77-79.
- Balch CM, Soong SJ, Milton GW et al. A comparison of prognostic factors and surgical results in 19786 patients with localized (Stage I) melanoma treated in Alabama, USA and New South Wales, Australia. *Ann Surg* 1982; 196: 677-684.
- Wanebo HJ, Woodruff JM, Farr GH, Quan SH. Anorectal melanoma. *Cancer* 1981; 47: 1891-1900.
- Soong SJ, Shaw HM, Balch CM et al. Predicting survival and recurrence in localized melanoma: a multivariate approach. *World J Surg* 1992; 16: 191-195.
- Ben-Izhak O, Levy R, Weil S et al. Anorectal melanoma: A clinicopathologic study, including immunohistochemistry and DNA flow cytometry. *Cancer* 1997; 79:18-25.
- Bujko K, Nowacki MP, Liszka-Dalacki P. Radiation therapy for anorectal melanoma: a report of two cases. *Acta Oncol* 1998; 37: 497-499.
- Uner A, Kilic D, Menten BB et al. Neoadjuvant radiotherapy in anorectal malignant melanoma. *IJCP* 2003; 57: 65-67.
- Luna-Perez P, Rodriguez DF, Macouzet JG, Labastida S. Anorectal malignant melanoma. *Surg Oncol* 1996; 5: 165-168.
- Melhof MM, Amrani NE, Mathieu-Daude H, Dubois JB. Les melanomes malins anorectaux. A propos de 5 cas : revue de la litterature. *Ann Gastroenterol Hepatol* 1995; 31: 209-212.
- Kim B, Sanguino AM, Hodges C et al. Biochemotherapy in patients with metastatic anorectal mucosal melanoma. *Cancer* 2004 ; 100: 1478-1483.
- Terada R, Ito S, Kobayashi M et al. Anorectal melanoma : successful treatment by surgical excision and combination by chemioimmunotherapy. *Hepatogastroenterology* 2002; 49: 1545-1548.

