

In-house preparation of iodine -131 metaiodo benzyl guanidine for scintigraphy of neuroendocrine tumors. Fourteen years experience in South India

**Regi Oommen,
Nylla Shanthly,
Narasimhan Subramani,
Devakumar Devadhas,
Julie Hephzibah,
Bernice Theodore,
Jayashankar Srinivasan**

Department of Nuclear Medicine,
Christian Medical College,
Vellore, India, 632004

☆☆☆

Keywords: Scintigraphy of NET – ¹³¹I - MIBG – In-house preparation – Quality control – Clinical evaluation

Correspondence address:

Dr Regi Oommen MD,
Professor and Head,
Department of Nuclear
Medicine, Christian Medical
College, Vellore, India 632004
Tel: 0091-416-2282176
Fax: 0091-416-2232103
E-mail: regi@cmcvellore.ac.in

Received:

21 March 2007

Accepted revised:

15 September 2007

Abstract

Iodine-131 metaiodobenzyl guanidine (¹³¹I-MIBG) is routinely used for imaging and treatment of neuroendocrine tumors (NET). As the commercially available radiopharmaceutical was very expensive, we developed an in-house method of labeling MIBG with ¹³¹I in 1993. A total of 247 batches of ¹³¹I-MIBG were prepared and used in our hospital between April 1993 and September 2006. We report our experience over these 14 years of preparation of this tracer in our hospital radiopharmacy, for the scintigraphy of NET. The technique of preparation is simple and the labeled product was found to be of acceptable quality. With the routine availability and cost effectiveness, the utilization of this radiopharmaceutical for scintigraphy increased remarkably in our institution.

Hell J Nucl Med 2007; 10(3): 164-166 • Published online: 19 November 2007

Introduction

Iodine-131 metaiodobenzyl guanidine (¹³¹I-MIBG) is routinely used for imaging and treatment of neuroendocrine tumors (NET) [1, 2]. It shares structural features of norepinephrine and hence it is actively taken up by sympathomedullary tissues, where it is stored in catecholamine storing granules. The role of ¹³¹I-MIBG in the evaluation of adrenal medullary diseases and other neuroendocrine tumors, is expanding. Clinical applications include diagnosis and treatment in NET like pheochromocytomas, paragangliomas, neuroblastomas, medullary thyroid carcinomas etc [3, 4].

Since it was first developed in 1982, ¹³¹I-MIBG scintigraphy remains an expensive imaging modality in India. Therefore, in our department, we have developed in 1993 an in-house method of labeling MIBG with carrier free ¹³¹I. Since then we are regularly preparing ¹³¹I-MIBG for scintigraphy, with a gradual increase in the number of preparations. We report our experience of the preparation of this radiopharmaceutical in our hospital radiopharmacy to be used for the scintigraphy of NET.

Materials and methods

A total of 247 batches of ¹³¹I-MIBG preparations were carried out between April 1993 and September 2006. During the first 10 years i.e., between 1993 and 2002, 122 batches were prepared. In the recent years, the preparation was carried out fortnightly. During a four-year period from 2002 to September 2006, 125 batches were prepared.

Labeling technique

The procedure involved the addition of 1-2 mg MIBG (Sigma Chemicals, USA) to 4 mg ammonium sulphate (SD Fine), followed by 370 MBq of carrier free iodine (I₂) (supplied by Bhabha Atomic Research Center, Mumbai) in a vial. All the reagents were pure. After sealing the vial, the mixture was heated at 160⁰ C for 30 min in an oil bath. A locally designed thermostat controlled heater, was used for this purpose. The final product was cooled and dissolved in 1.5-2 ml water for injection.

Checking the quality of the labeled product by thin layer chromatography

Radiochemical purity was checked with Whatman 1 paper using methanol as the solvent. Paper strips were spotted with labeled ¹³¹I-MIBG and a chromatogram was generated. Labeled ¹³¹I-MIBG moved to the solvent front (Rf 0.8-0.9) and free iodine remained at the spotting (Rf 0-0.5). Strips were cut into pieces of 1 cm length and assayed in a well counter (Packard

Instruments, USA). Purity of more than 95% was the acceptable limit.

Preliminary in-vivo studies

During 1993-1994, eleven batches of ¹³¹I-MIBG prepared in-house were intravenously (iv) injected into primates for biodistribution and imaging studies. About 18 MBq of ¹³¹I-MIBG were injected into leg veins of eleven monkeys (4 months old, male), and images were acquired using a gamma camera (Siemens, USA), at 24, 48 and 72 h. Principles of laboratory animal care were followed. Comparison with regard to imaging studies was done with commercially available ¹³¹I-MIBG (Amersham International, UK), in two monkeys. Images were acquired and compared with those obtained as above.

Clinical studies

After confirmation of the outcome of animal studies, in terms of quality control, ¹³¹I-MIBG was used for scintigraphy in patients with NET since September 1994. All patients studied gave their informed consent. The present work had been approved by the authorities of our hospital.

Adult patients were administered iv 18 MBq of ¹³¹I-MIBG. Imaging was done with a gamma camera, equipped with a medium energy collimator, with an energy window at 360 keV±10%. At 24, 48 and 72 h, whole body images in the anterior and posterior projections or spot views, were acquired. The scan speed was 8 cm/min for whole body scintigraphy, whereas 150-200 kcounts were collected for spot images. Potassium perchlorate 1.2 gm was administered orally, 3 h before the ¹³¹I-MIBG administration in order to block the thyroid gland, and daily for 3 days afterwards.

An analysis of the data of clinical studies performed between September 1994 and September 2006, was carried out to compare the number of studies performed prior to the start of the in-house preparation and afterwards. The impact of regular availability of ¹³¹I-MIBG scintigraphy for NET in our institution was looked at.

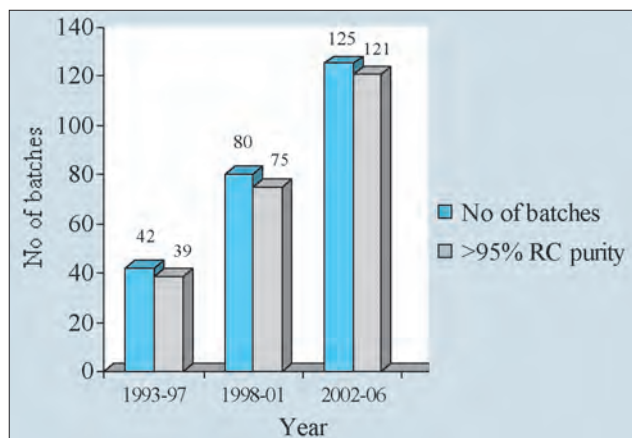


Figure 1. Details of radiochemical (RC) purity in the batches prepared.

Results

Quality control of the labeled product

The pH of the labeled product was between 5-6 for all the 247 batches prepared. Radiochemical purity was found to be above 95% in all except 12 batches (Fig. 1). The batches which failed quality control were discarded. The success rate was more or less the same throughout the study period, on an average 24 out of 25 batches.

Biodistribution

The results of biodistribution as demonstrated in animal imaging studies, revealed physiologic distribution of the radiopharmaceutical, namely in liver, myocardium and kidneys. Images were similar to those of the commercial product. None of the subjects showed any adverse effects until 14-15 days after the iv injection. In two animals sacrificed for organ counting, adrenal/liver ratio was 4:1 and 5:1 respectively. Comparison of our product with the commercial product showed similar characteristics.

Clinical studies

A total of 671 scintigraphy studies were performed in our department, between September 1994 and September 2006, with the in-house preparation of ¹³¹I-MIBG, whereas only 12 studies were performed before September 1994 (Fig. 2), thus showing a significant increase in the number of scintigraphy procedures, since the tracer was available on a regular basis in

Table 1. Indications for ¹³¹I-MIBG scintigraphy

Indications	No of studies	%
Carcinoid tumors	44	6.5
Pheochromocytomas and paragangliomas	232	34.6
Neuroblastomas	86	12.8
Medullary thyroid cancers	54	8.1
Others	255	38.0
Total	671	100

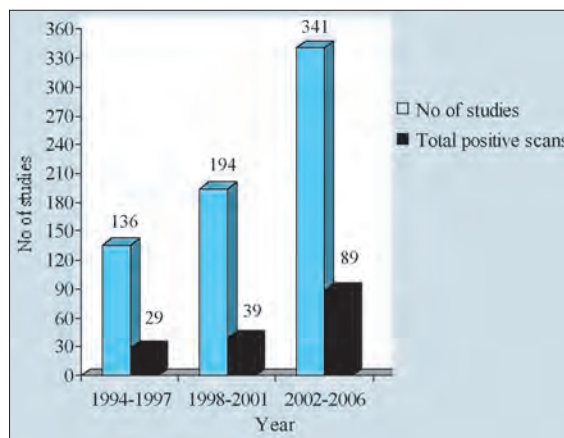


Figure 2. Distribution of total clinical studies during 1994-2006 and positive scans.

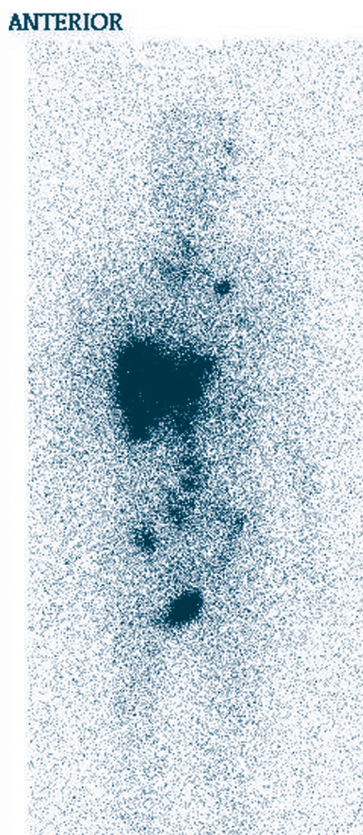


Figure 3. Whole body scintigraphy with ^{131}I -MIBG prepared in-house, showing multiple sites of metastases in a patient with malignant pheochromocytoma.

our hospital. None of the patients developed any side effects pertaining to the radiopharmaceutical administration. The indications for scintigraphy are given in Table 1. The clinical conditions included pheochromocytomas, paragangliomas, carcinoid tumors, neuroblastomas, and medullary thyroid carcinomas (Fig. 3). An analysis of the diagnostic utility in these conditions, is being done in a separate study.

Discussion

MIBG labeled with various iodine isotopes has been proved to be the most reliable tracer for NET [5]. Normal adrenals are uncommonly and faintly visualised with ^{131}I -MIBG at 48 h in about 20% of the cases. In contrast, most adrenal pheochromocytomas show intense focal uptake [6, 7]. Moreover, a positive correlation was found between ^{131}I -MIBG uptake and the number of storage granules in the tumoral tissue [8]. The authors' experience of the in-house preparation of ^{131}I -MIBG even from the first years of its preparation was quite encouraging. The technique was found to be relatively simple. The

quality control studies proved that this preparation was of comparable standards to an internationally available commercial product. It was also found to be very economical. The cost of the commercial product for ten studies was about 3000 US dollars, whereas it was only 600 US dollars for the in-house product.

From April 1993 onwards, the preparation of ^{131}I -MIBG for scintigraphy was carried out in our department. Initially, the frequency of labeling used to be once every 2 months. Later on, it was more frequently prepared, as the number of patients referred for ^{131}I -MIBG scintigraphy showed a gradual increase. The total number of studies done during the period from 1984 to 1992 was 12, whereas this number increased to 330 in 7 years between 1994 and 2001, and to 341 during the next 4 years, between 2002 and 2006. ^{131}I -MIBG scintigraphy had evolved in our institution as a routine imaging modality for NET. There was a significant increase in demand for this product, as the referring physicians and surgeons in our institution, were contented with the availability of ^{131}I -MIBG scintigraphy at a reasonable price throughout the year. *In conclusion*, we describe the technique by which for the last 14 years, we have been preparing ^{131}I -MIBG in our radiopharmacy. Acceptable results of quality control studies, animals' studies, clinical application studies and the low cost of this preparation, make it clinically useful.

Bibliography

1. Troncone L, Rufini V. ^{131}I -MIBG in the diagnosis of neuroendocrine tumours. In: *Nuclear Medicine in Clinical Diagnosis and Treatment*, 3rd edn. Ell PJ, Gambhir SS (eds). Churchill & Livingstone, London 2004; pp: 83-96.
2. Kaltsas G, Mukherjee JJ, Foley R et al. Treatment of metastatic pheochromocytoma and paraganglioma with ^{131}I metaiodobenzyl guanidine (MIBG). *Endocrinologist* 2003; 13: 1-3.
3. Bombardieri F, Maccauro M, de Deckere J et al. Nuclear medical imaging of neuroendocrine tumours. *Ann Oncol* 2001; 12 (Suppl 2), S51-S61.
4. Kurtaran A, Traub T, Shapiro B. Scintigraphic imaging adrenal glands. *Eur J Radiol* 2002; 41: 123-130.
5. Shapiro B, Copp JE, Sisson JC et al. ^{131}I -metaiodobenzyl guanidine for the location of suspected pheochromocytoma: experience in 400 cases. *J Nucl Med* 1985; 26: 576-585.
6. Gross MD, Shapiro B, Bui C et al. Adrenal scintigraphy and metaiodobenzylguanidine therapy of neuroendocrine tumours. In: Sandler PM, Coleman RE, Patton JA et al (eds). *Diagnostic Nuclear Medicine* 4th edn, Lippincott Williams & Wilkins Philadelphia 2003; pp: 713-734.
7. Rufini V, Calcagni ML, Baum RP. Imaging of neuroendocrine tumors. *Semin Nucl Med* 2006; 36: 228-247.
8. Bomanji J, Flatman WD, Home T et al. Quantitation of iodine-123 MIBG uptake by normal adrenal medulla in hypertensive patients. *J Nucl Med* 1987; 28: 319-324.

