Bilateral adrenal metastases and metastatic subcutaneous deposit in the chest wall from osteosarcoma of the mandible: utility of ^{18}F-FDG-PET

Abstract

Adrenal gland involvement as well as metastatic subcutaneous nodule from skeletal osteosarcoma are two extremely rare and unusual manifestations in the natural history of the disease. *We herein report* a 45 yr old female with both these uncommon occurrences, having large bilateral adrenal metastases and a metastatic subcutaneous nodule in the chest wall along with pulmonary metastasis arising from osteosarcoma of the mandible. Our fluorine -18 fluorodesoxy glucose- positron emission tomography study provided all information needed about the disease status in a single examination. *It is noteworthy* that osteosarcoma of the jaws, thought to be relatively less aggressive compared to its counterpart in long bones, can occasionally give rise to widespread metastases, including atypical sites. A systematic *review of the existing literature* aiming to explore the patients' characteristics and clinical behavior of adrenal metastases from osteosarcoma, including the present case, was carried out. This was nearly always associated with pulmonary metastases with occasional association with brain or skeletal metastases. Peripheral long bones were the overwhelmingly common site of the primary, the present one being *the first report of jaw bone being the primary* site, giving rise to adrenal metastases. No age predilection was observed with male to female ratio of 3:1 in the small number of reported cases.

Hell J Nucl Med 2009; 12(1): 51-54 • Published on line (abstr.): 3 March 2009

Sandip Basu[1], Tanuja Shet[2], Sushama Awasare[1]

1. *Radiation Medicine Centre, Bhabha Atomic Research Centre,*
2. *Department of Pathology, Tata Memorial Hospital Annex, Parel, Bombay 400 012. India*

Keywords: Bilateral adrenal metastases – Osteogenic sarcoma of the mandible – Metastatic subcutaneous nodule in the chest – ^{18}F-FDG-PET.

Correspondence address:

Dr Sandip Basu,
Radiation Medicine Centre,
Tata Memorial Hospital Annexe,
Jerbai Wadia Road,
Parel, Bombay 400 012, India
Email:drsanb@yahoo.com

Received: 17 January 2009

Accepted revised: 26 January 2009

Description of the case

A 45 years old lady presented with a history of right-sided jaw swelling of six months duration. An orthopantomogram revealed the presence of a well-defined lytic lesion in the horizontal ramus of the right mandible with an associated soft tissue mass. The right mandibular canal appeared to be involved by the lesion. Evidence of caries was noted in the left 1st lower molar tooth and the left 2nd upper molar tooth. A chest roentgenogram revealed a large well-defined mass posteriorly in the lower lobe of the left lung. No evidence of any cavitation or calcification was seen. Computer tomography (CT) scan of the mandible showed an osteolytic lesion involving the body of the right half of the mandible, with involvement of the root of the first molar tooth and erosion of the alveolar margin and the buccal cortex (Fig. 1). Abnormal enhancing soft tissue was seen within the lesion extending into the buccal space. Biopsy from the posterior 1/3rd of the alveolar lesion proved it to be primary osteoclast-rich osteosarcoma of the mandible with an overabundance of osteoclasts and paucity of tumour osteoid. The tumor cells were positive for vimentin and negative for CK, EMA, S100, SMA, desmin, HMB45 and CD34 on immunohistochemistry. Tranaxial helical spiral CT scan of the thorax and abdomen performed in contrast dynamic mode showed a large mass of 7.5 X 6.3 cm in the left lung lower lobe with calcification touching the pleura and erosion of the left 5th rib. Bilateral large adrenal metastatic lesions were noted (right 5.3X4.5 cm and left 8.2×6.2 cm). She was started on neoadjuvant chemotherapy and was referred for fluorine -18 fluorodesoxy glucose- positron emission tomography (^{18}F-FDG-PET) (Fig. 1a, b and c) 8 days after receiving last chemotherapy for evaluation of disease status. Focus of increased ^{18}F-FDG uptake was noted in the right hemimandible corresponding to the site of the primary. Varying degree of diffuse ^{18}F-FDG uptakes was also noted in the bone marrow of the vertebrae, humerii, pelvis, ribs and proximal femora along with spleen. This was most likely related to the recent administration of granulocyte-macrophage colony stimulating factor (GM-CSF) 8 days prior to the ^{18}F-FDG-PET. Heterogeneous ^{18}F-FDG uptake was seen in the left lung lower zone corresponding to the CT described mass in that area. Heterogeneous ^{18}F-FDG uptakes were also noted in both the

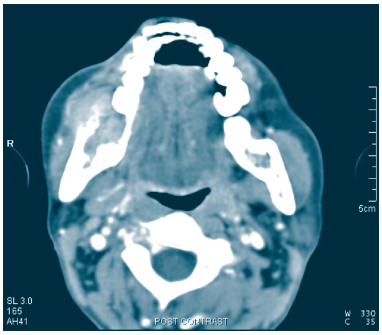

Figure 1. CT scan of the mandible showing an osteolytic lesion involving the body of the right half of the mandible, with involvement of the root of the first molar tooth and erosion of the alveolar margin and buccal cortex. Abnormal enhancing soft tissue is seen within the lesion, which extends into the buccal space.

adrenals, with right adrenal showing evidence of more necrosis compared to the left (Fig. 2a, and b). The areas of photopenia interspersed in the heterogeneous ^{18}F-FDG uptake in the metastatic pulmonary and adrenal lesions were likely to be related to the necrosis related to the treatment effect following neoadjuvant chemotherapy. There was another intense focal ^{18}F-FDG uptake in the left chest in addition to the above, which when triangulated, was found to be in the anterior chest wall in both transaxial as well as the sagittal slices (Fig. 2c). This was further corroborated in the rotatory maximum image projection (MIP) image. The patient was examined clinically and was found to have a mobile subcutaneous nodule of around 2 cm in diameter in the left anterior chest wall, which was hitherto unknown to his treating physician. The excision biopsy of the nodule confirmed it to be a metastasis from osteogenic sarcoma.

Discussion

Skeletal osteosarcoma is the most common primary malignant neoplasm of the bone of mesenchymal derivation, predominantly occurring in the metaphysis of the long bones of adolescents, young adults and affects males slightly more often than females. In the United States, the incidence of osteosarcoma is 400 cases per year [1]. Metastatic spread is the single most important prognostic factor. Osteosarcoma tends to have early hematogenous metastases. The lung is overwhelmingly the most common site of metastases for skeletal osteosarcoma. The mainstay of therapy is removal of the lesion. Limb-sparing procedures are carried out to preserve function. More than 80% of patients subsequently develop recurrent disease that usually present as pulmonary metastases treated with "surgery-only" approach [2, 3]. This is due to the fact that most patients have micrometastatic disease at diagnosis. Therefore, the use of adjuvant chemotherapy is critical for the treatment of patients with osteosarcoma. Neoadjuvant chemotherapy has been used to facilitate subsequent surgical removal by shrinking the tumor, treating distant metastases present at diagnosis and also works as an important risk parameter. Patients who have a good histopathologic response to neoadjuvant chemotherapy (>95% tumor cell kill or necrosis) have a better prognosis.

Adrenal metastases from skeletal malignancies are rare and those from osteogenic sarcoma more so, with only 3 cases reported previously in the literature [4-6]. The patients' characteristics and the clinical details of individual cases are mentioned in Table 1. In the 4 reported cases (including the present one), there does not seem to be any age predilection. While the patients in the first two reports were in their second decade, the cases reported by Kpodonu et al (2005) and that in the present study were in their fourth and fifth decade of age respectively [6]. All the previous reports except the present one have been reported in males (male to female ratio 3:1). In all the previous reports the primary site was in the long bones, essentially reflecting the overwhelmingly common occurence of osteosarcoma in the extremities of long bones and the relatively aggressive behaviour of

Table 1. *Adrenal metastases from osteogenic sarcoma reported in the literature: Salient patient characteristic*

Author	Year	Age/Gender	Site of primary	Clinical setting	Associated metastasis (sites)	Treatment history
Potepan et al [1]	1992	10 yrs/Male	Left proximal tibia	Solitary pulmonary metastasis 26 mths after diagnosis; Right adrenal mass 3 yrs after initial diagnosis	Lungs	Chemotherapy, primary surgery, pulmonary metastatectomy and adrenalectomy
Kauffman et al [2]	1995	16 yrs/Male	Left distal femur	Solitary left adrenal mass developed 5 yrs after diagnosis, along with skeletal and pulmonary metastasis.	Bilateral lungs, Right ring finger (skeletal)	Local resection followed by chemotherapy, resection of pulmonary metastasis and amputation of ring finger
Kpodonu et al [3]	2005	37 yrs/Male	Right femur	Brain and pulmonary metastasis 9 yrs after diagnosis, large right adrenal mass detected 8 yrs after resection of brain and pulmonary metastasis	Brain, bilateral lungs	Craniotomy and sternotomy for resection of brain and pulmonary metastasis. Resection of adrenal metastasis through thoracoabdominal approach.
Present study	2005	45 yrs/Female	Right side of the mandible	Bilateral large adrenal masses detected at diagnosis along with pulmonary and subcutaneous metastasis.	Left lung lower lobe mass, metastatic subcutaneous nodule in the left anterior chest wall	2# neoadjuvant chemotherapy at the time of ^{18}F-FDG-PET

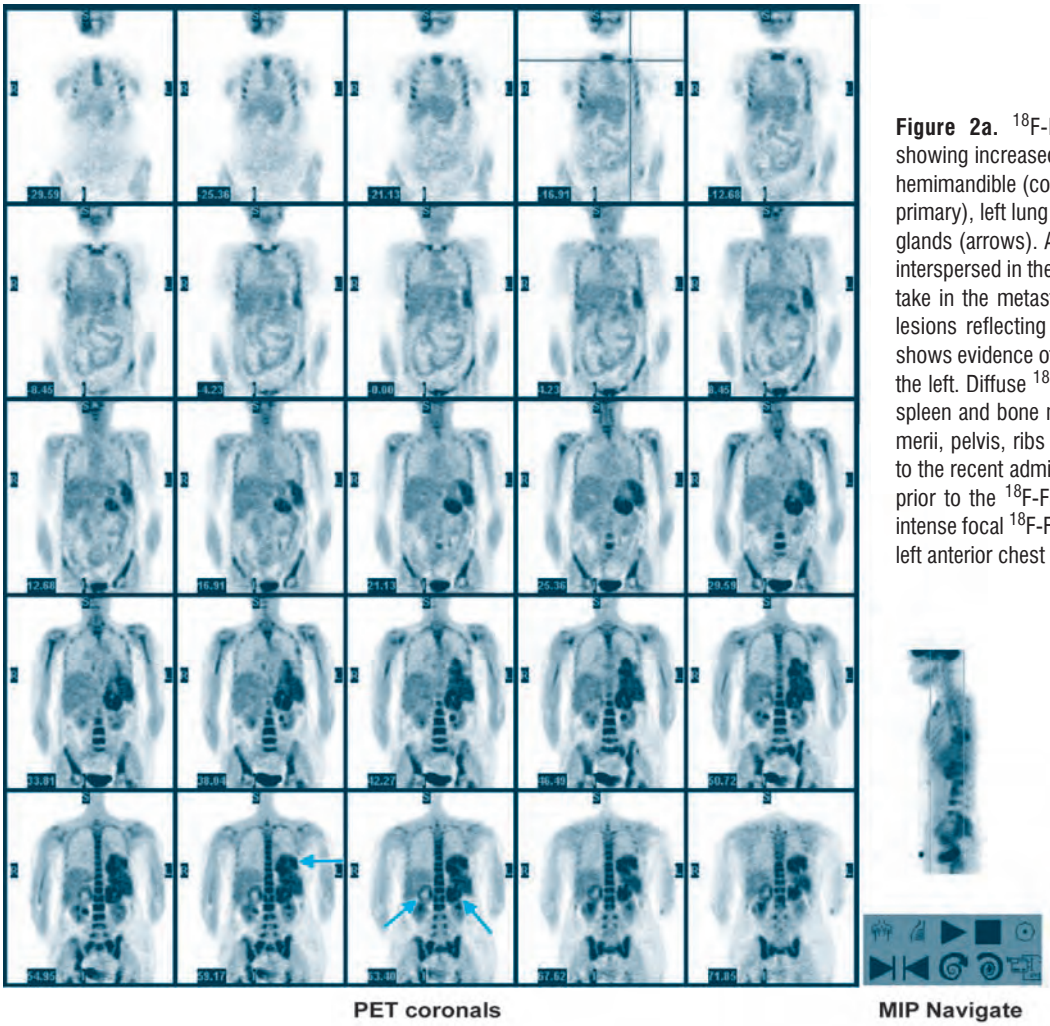

Figure 2a. ^{18}F-FDG-PET coronal images, showing increased ^{18}F-FDG uptake in the right hemimandible (corresponding to the site of the primary), left lung lower zone and both adrenal glands (arrows). Areas of photopenia are seen interspersed in the heterogeneous ^{18}F-FDG uptake in the metastatic pulmonary and adrenal lesions reflecting necrosis. The right adrenal shows evidence of more necrosis compared to the left. Diffuse ^{18}F-FDG uptake is noted in the spleen and bone marrow of the vertebrae, humerii, pelvis, ribs and proximal femora related to the recent administration of GM-CSF 8 days prior to the ^{18}F-FDG-PET study. Another tiny intense focal ^{18}F-FDG uptake is observed in the left anterior chest wall.

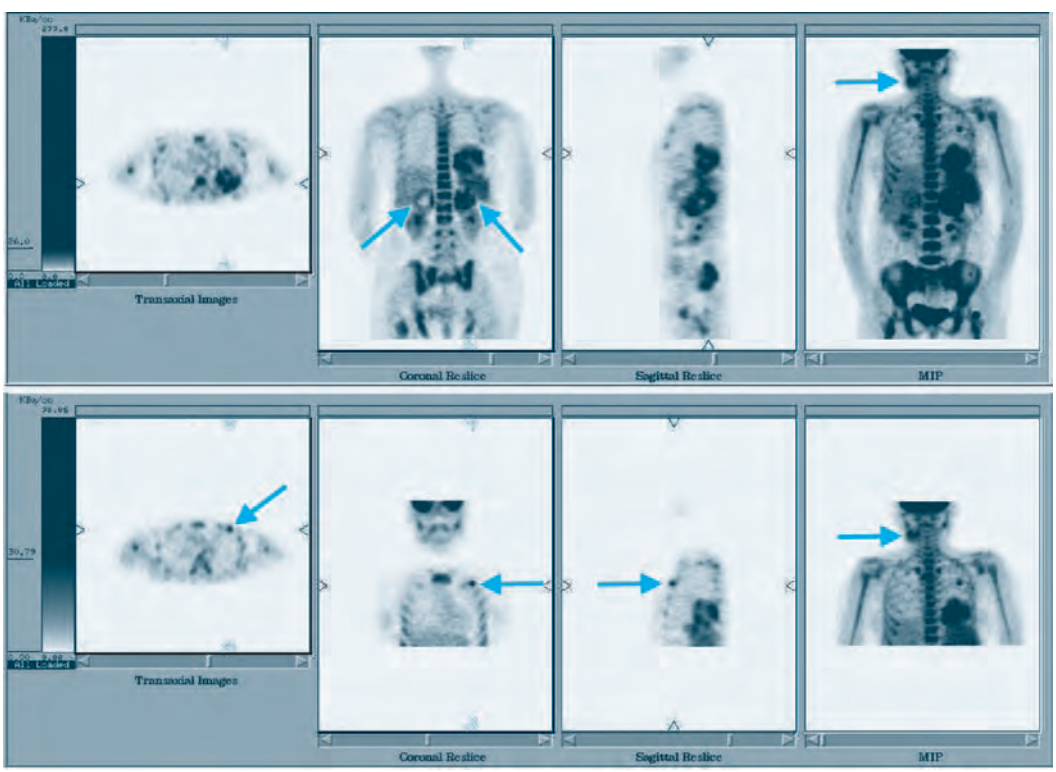

Figure 2b and 2c. ^{18}F-FDG-PET (MIP images) triangulated over the metastatic adrenal glands (upper panel) and the subcutaneous nodule in the left anterior chest wall (lower panel) respectively (arrows).

these compared to the osteosarcoma of the jaws [7-9]. Osteosarcoma of the jaws tends to occur at an older mean age and its prognosis is believed to be better than that arising in other sites [7]. Lower mitotic activity and lesser degree of cellular anaplasia in osteosarcomas of the jaws are the two factors implicated to be responsible for their different clinical and biologic characteristics and for favorable prognosis compared to those of osteosarcomas of the long bones [8]. Overall there is a lesser tendency for osteosarcomas of the jaws to metastasize than for osteosarcomas of the long bones [9]. This is, to the best of our knowledge, the first report of osteosarcoma of the jaws metastasizing to both adrenal glands irrespective of the site of the primary. In the previous 3 reports there has been unilateral adrenal metastasis. The metastatic deposit into the subcutaneous tissue at a site distant from the site of primary osteosarcoma is also hitherto unreported. With the improved outcome with multimodality management and increased survival of patients with osteosarcoma, these atypical metastatic sites are likely to be increasingly encountered in practice.

Bibliography

1. Ries LAG, Smith MA, Gurney JG et al. Cancer incidence and survival among children and adolescents: United States SEER program 1975-1995. Bethesda, Md: National Cancer Institute; 1999. NIH Pub No 99–4649. Available at http://seer.cancer.gov/publications/childhood/.
2. Jeffree GM, Price CH, Sissons HA. The metastatic patterns of osteosarcoma. *Br J Cancer* 1975; 32: 87-107.
3. Rimondi E, Ferrari S, Briccoli A et al. Non-metastatic osteosarcoma of the extremities: the pattern of relapse as a function of the type of treatment and of the modulation of the radiological follow-up of the thorax. *Minerva Med* 1996; 87: 9-15.
4. Potepan P, Danesini GM, Spagnoli I et al. Adrenal gland metastasis in osteogenic osteosarcoma. A radiological case report. *Tumori* 1992; 78: 417-420.
5. Kauffman WM, Winer-Muram H, Sandlund JT. Detection of adrenal metastasis from osteosarcoma by ^{99m}Tc MDP scintigraphy. *Clin Nucl Med* 1995; 20: 741.
6. Kpodonu J, Warso MA, Massad M G. Osteosarcoma Invading Adrenal Gland: Rare Cause of Adrenal Mass. *Urology* 2005; 65: 1226.
7. Sciubba JJ, Fantasia JE, Kahn LB. Tumors and cysts of the jaws (3rd series), *Atlas of Tumor Pathology*, Armed Forces Institute of Pathology, Bethesda, MD. 1999; 181.
8. Piattelli A. and Favia GF. Periosteal osteosarcoma of the jaws. Report of 2 cases. *J Periodontol* 71. 2000; 325.
9. Neville BW, Damm DD, Allen CM et al. Oral and Maxillofacial Pathology 2nd edn, Saunders, Philadelphia, PA. 2002; 577.