Increased serum carbohydrate antigen 19-9 in relapsed ductal breast carcinoma

Vassilios Papantoniou[1], **Spyridon Tsiouris**[1], **John Koutsikos**[1], **Nikolaos Ptohis**[2], **Dimitrios Lazaris**[3], **Cherry Zerva**[1]

1. *Department of Nuclear Medicine,*
2. *Department of Radiology,*
3. *Department of Obstetrics & Gynecology,*

of "Alexandra" University Hospital; 80, Vas. Sophias Ave. and 2, K. Lourou Str., 115 28 Athens, Greece

Keywords: Breast cancer relapse – ^{99m}Tc-sestamibi – Scintimammography – Increased CA 19-9 – Serum CEA

Correspondence address:
Vassilios Papantoniou MD, PhD
"Alexandra" University Hospital,
Department of Nuclear Medicine
80, Vas. Sophias ave.
& 2, K. Lourou str.,
115 28 Athens, Greece,
Tel: +30 210 33 81 785,
Fax: +30 210 77 07 404,
E-mail: jtkoutsik@yahoo.gr

Received:
21 December 2005
Accepted revised:
3 March 2006

Abstract

Increased serum carbohydrate antigen (CA) 19-9 is a quite uncommon manifestation of breast cancer both in early disease and in relapse. A 53-year-old woman with invasive ductal breast carcinoma underwent left-sided mastectomy. Two years later she palpated a subcutaneous mass at the mastectomy scar, arousing suspicion of local relapse. Surgery and histopathology revealed infiltration by breast adenocarcinoma and she was treated with chemotherapy. At that time serum tumor markers, carcinoembryonic antigen (CEA) and CA 15-3 were within normal range. Over the next six months she displayed an increase of serum CEA, while serum CA 15-3 remained within normal range. In an attempt to search for a second neoplasm possibly of gastrointestinal (GI) origin, abdominal computed tomography (CT), magnetic resonance imaging (MRI), magnetic resonance cholangio-pancreatography (MRCP), endoscopy of the upper GI tract and colonoscopy were performed, as well as measurement of serum CA 19-9. While no indication of a GI neoplasm was detected, she displayed an over 10-fold increase of serum CA 19-9. The patient had also an X-ray mammography and technetium-99m hexakis-2-methoxyisobutylisonitrile (^{99m}Tc-MIBI) scintimammography (SM). Whilst mammography was negative for contralateral disease recurrence, SM was suggestive of axillary lymph node involvement. Axillary lymph node dissection confirmed an extensive metastatic infiltration of these nodes by breast adenocarcinoma. Three months later serum CA 19-9 and CEA became normal. The interest of this case lies in the unexpected high serum CA 19-9 values found in a breast relapsed adenocarcinoma and in the important contribution of SM in diagnosing the axillary lymph node metastatic infiltration.

Hell J Nucl Med 2006; 9(1): 36-38

Introduction

Increased serum carbohydrate antigen (CA) 19-9 is uncommon in both early breast cancer and relapse. In breast cancer patients, especially those who underwent chemotherapy and/or radiotherapy, there is an increased risk of developing a second neoplasm [1]. In these patients, an increase in serum CEA and CA 19-9 may indicate a second malignancy most likely of gastrointestinal (GI) origin [1,2]. Schatz et al. (1985) [2] have reported that over a follow-up period of at least one year, serum levels of CA 19-9 increased in only one of 49 patients with breast cancer metastases and concluded that determination of CA 19-9 appears unnecessary in cases of breast cancer. To our best knowledge, no other paper besides the one mentioned above on increased serum CA 19-9 in breast cancer patients has been published.

Technetium-99m-hexakis-2-methoxyisobutylisonitrile (^{99m}Tc-MIBI) scintima-mmography (SM) is complementary to conventional mammography for the detection of breast carcinoma, especially in cases of dense breasts, scars from surgical intervention or radiotherapy, and breast augmentation. It is sensitive (~88%), specific (~93%), and accurate (~90%) in imaging invasive lesions greater than 1 cm in size [3,4]. Moreover, SM is indicated in cases of suspected axillary node metastases with a sensitivity of 79% and specificity of 91% [4-7].

We report a case of breast carcinoma with increased serum CA 19-9 without evidence of a GI neoplasm, normal X-ray mammography and axillary metastases revealed by SM.

Case presentation

A 53-year-old female, three years ago, underwent conventional X-ray mammography, due to left nipple retraction accompanied by a palpable firm breast mass behind the nipple. The corresponding gland area displayed parenchymal architectural distortion with thickened nipple skin and retraction. Breast ultrasonography showed a heterogeneous hypoechoic mass, with irregular borders and acoustic shadowing (Fig. 1). Serum levels of carbohydrate antigen

Figure 1. Conventional X-ray mammography (main frame) and breast ultrasonography (embedded frame). Parenchymal architectural distortion behind the nipple, with skin thickening and retraction (curved arrow), corresponding to an irregular, ill-defined, heterogeneous, hypoechoic mass (transparent arrow), with acoustic shadowing and a hyperechoic rim

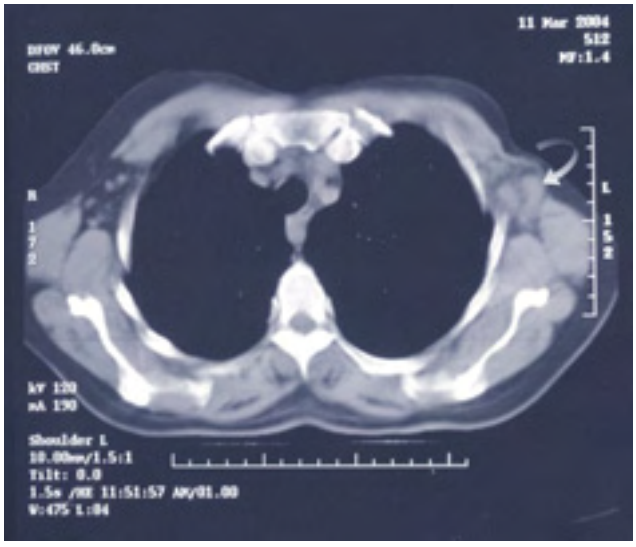

Figure 3. CT of the thorax during the second relapse. A mass of soft tissue density is 'filling up' the left axillary cavity (curved arrow)

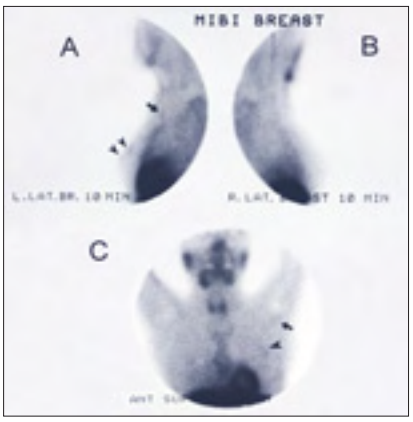

Figure 2. ^{99m}Tc-MIBI scintimammography. Left lateral (A); right lateral (B); and anterior projections (C). Increased bifocal uptake behind the left nipple (arrowheads), suggestive of invasive tumor. Axillary lymph node involvement is not readily visible anteriorly, but in the left lateral projection (arrows)

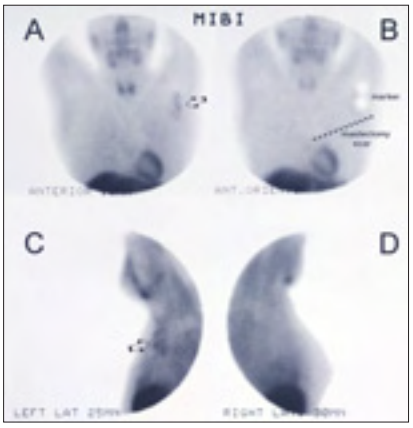

Figure 4. ^{99m}Tc-sestamibi scintimammography at the second relapse. Anterior (A); anterior, with a marker over the palpable axillary mass (B); left lateral (C); and right lateral projections (D). Increased left axillary uptake (transparent arrows), suggestive of malignant lymph node infiltration.

(CA) 15-3 and carcinoembryonic antigen (CEA) were within the normal range (12.2 IU/ml [normal range <31.0 IU/ml] and 0.7 ng/ml [normal range <5.0 ng/ml], respectively).

SM was performed using a single-head γ-camera (Sophycamera DS7®, Sopha Medical Vision International, Buc Cedex, France), equipped with a high-resolution parallel hole collimator. The matrix was 256×256 pixels and the photopeak was centered at 140 keV, with a symmetrical 10% window. Acquisitions were obtained using a special positioning pad (PBI-2 Scintimammography Pad Set®, Pinestar Technology Inc., Greenville, PA, USA), after the intravenous injection of 740 MBq of ^{99m}Tc-MIBI (Cardiolite®, Bristol – Myers Squibb GmbH [Regensburg, Germany]), with early (at approximately 10 min) planar images in lateral prone and anterior supine positions. SM revealed focal increased radiotracer accumulation behind the left nipple (Fig. 2), suggestive of invasive breast cancer.

Fine needle aspiration biopsy showed malignancy, which was confirmed by frozen sections. Left mastectomy was then performed. Histopathology showed grade II invasive ductal breast carcinoma (IDC), displaying significant extracellular mucin production, with co-existent micropapillary ductal carcinoma in situ (DCIS) and with ipsilateral axillary lymph node involvement (2/11 positive nodes). The patient received adjuvant chemotherapy: six cycles of the capecitabine-trastuzumab regimen.

Two years later, the patient palpated a subcutaneous mass at the mastectomy scar area, arousing suspicion of local relapse. She underwent local surgery and biopsy showed infiltration by breast adenocarcinoma with endo- and extracellular mucin production. She received another nine cycles of capecitabine-trastuzumab over the following six months. During that period, serum CA 15-3 and CEA markers remained normal.

Three years after the first diagnosis and surgery and 10 months after the relapse, serum CEA levels increased (27.0 ng/ml), while serum CA 15-3 was within normal range (30.5 IU/ml). At the same time, measurement of serum CA 19-9 was obtained for further evaluation for a possible second neoplasm, and was found increased over 10-fold above normal: 545.0 IU/ml. On palpation the left axilla revealed a soft, nontender mass. Apart from the possibility of disease relapse, CA 19-9 increase in parallel with CEA, aroused suspicion of a second, possible GI, neoplasm.

For further evaluation, abdominal computed tomography (CT), magnetic resonance imaging (MRI), and magnetic reso-

nance cholangio-pancreatography (MRCP) were performed. They did not reveal any hepatic or pancreatic lesions. Similarly, endoscopy of the upper GI tract and colonoscopy showed no indication of a GI neoplasm. Bone scintigraphy showed no skeletal metastases.

For further evaluation of local recurrence, a CT of the thorax was performed and confirmed no other lesion but a left axillary mass, which was believed to be a post surgical cicatrix rather than metastatic lymph node involvement (Fig. 3). Conventional mammography of the right breast did not reveal any signs of contralateral disease recurrence. A second SM was considered appropriate and was performed a few days later, with the same protocol as the first one. The SM did not reveal any increased radiotracer uptake in the bed of the excised left breast, in the mastectomy scar, or in the right breast. However an intense tracer accumulation was apparent in the left axilla (Fig. 4).

Based on the SM findings, the patient was submitted to surgical exploration of the left axilla. Histopathology examined a soft on palpation lymph node block, which was positive for malignancy on frozen sections. Lymph node dissection followed and histology demonstrated extensive metastatic infiltration of the axillary lymphnodes by adenocarcinoma. Thirty three of the 34 axillary nodes dissected were positive. Also, morphological characteristics of mucous breast adenocarcinoma with profound mucin production, was found. Within the following three months, serum levels of CA 19-9 and CEA gradually dropped to normal.

Discussion

Serum CA 15-3 and CEA are currently employed in clinical practice as tumour markers for breast cancer, particularly for the follow-up and after treatment. CEA is of particular value in colorectal carcinoma follow-up. In cases of relapse, a rise in CEA levels usually precedes clinical evidence [8]. It may also rise early in breast cancer relapse, prior to any other clinical evidence; yet, it is a less sensitive indicator, as compared with CA 15-3 [9]. The American Society of Clinical Oncology (ASCO), in its 2000 update of the Clinical Practice Guidelines for the use of tumour markers in breast carcinoma [10], does not recommend CEA for monitoring treatment response of metastatic disease, although, in the absence of readily measurable disease, a rising titer may suggest treatment failure. Likewise, despite the fact that CA 15-3 is a more sensitive marker of relapse, the ASCO expresses skepticism about recommending it for surveillance, due to insufficient literature data [10].

Sialyl Lewis A antigen (another name for CA 19-9) is a high molecular weight glycoprotein originally described as a GI-specific and pancreatic-specific tumour marker. It is sensitive for several GI adenocarcinomas, such as pancreatic, gastric, colorectal, and hepatobiliary. Less often it has been described in association with ovarian, endometrial, cervical, urothelial, and thymic malignancies [11-13]. To our best knowledge, only Schatz et al. (1985) have studied CA 19-9 in breast cancer [2]. CA 19-9 is a ligand for the cell adhesion molecule E-selectin expressed on vascular endothelial cells, thus being involved in the adhesion of cancer cells to vascular endothelium and in inducing hematogenous metastases [14-15]. The overexpression of CA 19-9 is associated with adenocarcinomas of mucinous histotype, similarly to CEA. This was verified in the present case, where the excised axillary lymph nodes were infiltrated by breast adenocarcinoma with avid mucin production.

In conclusion, we describe this case of a female breast cancer patient, because we have noticed increased serum CA 19-9 which is a very uncommon finding and gave rise to suspicion for relapse. Scintigraphy by ^{99m}Tc-MIBI after the initial surgery for breast carcinoma, detected a new breast cancer lesion, thus contributing to proper diagnosis and management.

Bibliography

1. Levi F, Te VC, Randimbison L, et al. Cancer risk in women with previous breast cancer. *Ann Oncol* 2003; 14: 71-73.
2. Schatz C, von Lieven H, Mulders M, et al. The tumor markers CEA, TPA and CA 19-9 and ferritin and osteocalcin in follow-up studies in breast cancer. *Wien Klin Wochenschr* 1985; 97: 873-879.
3. Palmedo H, Schomburg A, Grunwald F, et al. Technetium-99m-MIBI scintimammography for suspicious breast lesions. *J Nucl Med* 1996; 37: 626-630.
4. Papantoniou V, Christodoulidou J, Papadaki E, et al. ^{99m}Tc-(V)DMSA scintimammography in the assessment of breast lesions. Comparative study with ^{99m}Tc MIBI. *Eur J Nucl Med* 2001; 28: 923-928.
5. Lam WW, Yang WT, Chan YL, et al. Detection of axillary lymph node metastases in breast carcinoma by technetium-99m sestamibi breast scintigraphy, ultrasound and conventional mammography. *Eur J Nucl Med* 1996; 23: 498-503.
6. Buscombe J, Hill J, Parbhoo S. The clinical role of scintimammography. Edited by Buscombe J, Hill J, Parbhoo S. In: *Scintimammography – A guide to good clinical practice*; Birmingham, UK; Gibbs Associates Ltd, 1998, p. 34-42.
7. National Institute for Health Consensus Conference. Treatment of early stage breast cancer. *JAMA* 1991; 265: 391-395.
8. Bendardaf R, Lamlum H, Pyrhonen S. Prognostic and predictive molecular markers in colorectal carcinoma. *Anticancer Res* 2004; 24: 2519-2530.
9. Colomer R, Ruibal A, Salvador L. Circulating tumor marker levels in advanced breast carcinoma correlate with the extent of metastatic disease. *Cancer* 1989; 64: 1674-1681.
10. Bast RC Jr, Ravdin P, Hayes DF, et al. 2000 update of recommendations for the use of tumor markers in breast and colorectal cancer: clinical practice guidelines of the American Society of Clinical Oncology. *J Clin Oncol* 2001; 19:1865-1878.
11. Gadducci A, Cosio S, Carpi A, et al. Serum tumor markers in the management of ovarian, endometrial and cervical cancer. *Biomed Pharmacother* 2004; 58: 24-38.
12. Sashide K, Isobe H, Wakumoto Y, et al. CA 19-9 as a serum marker for poor prognosis in urothelial carcinoma. *Urol Int* 2004; 72: 112-117.
13. Misao T, Yamamoto Y, Nakano H, et al. Primary thymic adenocarcinoma with production of carbohydrate antigen 19-9 and carcinoembryonic antigen. *Jpn J Thorac Cardiovasc Surg* 2004; 52: 30-32.
14. Klopocki AG, Laskowska A, Antoniewicz-Papis J, et al. Role of sialosyl Lewis A in adhesion of colon cancer cells – the antisense RNA approach. *Eur J Biochem* 1998; 253: 309-318.
15. Kannagi R. Carbohydrate-mediated cell adhesion involved in hematogenous metastasis of cancer. *Glycoconj J* 1997; 14: 577-584.