Focal tracer uptake in the jaw

Mai R. El-Zahry[1, 2]MSc, Helmut Sinzinger[1]MD

1. Department of Nuclear Medicine, Medical University of Vienna, Austria
2. Department of Clinical Oncology and Nuclear Medicine, Faculty of Medicine, South Valley University, Qena, Egypt
Phone: +4314082633, Fax: +43 14081366, E-mail: helmut.sinzinger@chello.at

Hell J Nucl Med 2014; 17(3): 165-166 *Epub ahead of print: 12 November 2014* *Published online: 22 December 2014*

Focal tracer uptake in the jaw during conventional bone scintigraphy is a quite frequent finding usually due to dental disease and seldom to other diseases including malignant disease [1, 2]. Bone scintigraphy reflects the metabolic activity of the bone and its lesions. Even an approximately 10% increase in the osteoblastic activity can be identified in the bone scan [3]. The methylene diphosphonate-technetium-99m (^{99m}Tc-MDP) 3-phase bone scan is considered the most sensitive imaging method for the detection of jaw osteonecrosis at an early stage as compared to computerized tomography (CT) and magnetic resonance imaging (MRI) in defining the features and extent of the osteolytic lesions [4]. Others reported that bone scintigraphy by ^{99m}Tc-MDP was better than panoramic radiography in order to diagnose dental jaw bone lesions [5]. This finding can also but seldom be seen in patients undergoing palliative radionuclide treatment for bone metastases. Prevalence and the origin of focal tracer uptake in the jaw are not always well described or documented.

Less than 1% of enhanced focal jaw uptake is due to ossifying fibromas, odontomas, residual osteitis, osteomyelitis, enchondromas, osteomas, Gardner's syndrome, actinomycosis or lymphomas [6].

Biphosphonates are powerful osteoclast inhibitors, with anti-tumor and anti-angiogenic properties, that are increasingly used in the management of Paget's disease, fibrous dysplasia, osteoporosis, multiple myeloma and metastatic prostate or breast cancer bone disease. In 2004 it was established that nitrogen-containing biphosphonates may induce jaw osteonecrosis, which has an estimated incidence during the first 3 years of treatment up to 15% [4, 7]. Osteonecrosis of the jaw, its location, and extent in multiple myeloma patients receiving bisphosphonates are better defined by both positron emission tomography/CT (PET/CT) and contrast-enhanced MRI compared with dental panoramic views derived from cone beam CT imaging [8]. The combined use of sestamibi scintigraphy and fluorine-18-fluorodeoxyglucose (^{18}F-FDG) PET/CT has been proposed to avoid risks of surgical biopsy [9].

Dental bone disease, trauma and current bone infection can be diagnosed by dental X-rays, or/and bone image examination [2]. The possibility of metastases in the jaw should also be considered [10].

During the last 15 years in the Nuclear Medicine Department of Vienna University, we studied 347 patients with cancer of the prostate (195), breast (93), lung (19) and 40 with other malignancies (unpublished data). In the group of prostate cancer patients, jaw lesions were 61.2% (57) of all dental lesions. Overall, 23.9% (83) of all cancer patients (347) had one or more jaw lesions (93). Most of these 93 lesions were related to dental disease. A percentage of 4.3% (4) of these lesions had clinical evidence and evidence by PET with samarium-153- ethylene diamine tetramethylene phosphonate (^{153}Sm- EDTMP) and/or MRI that they had metastases in the jaw. Such metastases in the jaw are shown in a patient with breast (A) and in another with prostate cancer (B), in Figure 1.

All patients had received ^{153}Sm-EDTMP pain palliation treatment, according to the so called "Vienna protocol" [11]. By this protocol, 1.1GBq ^{153}Sm-EDTMP is administered intra-

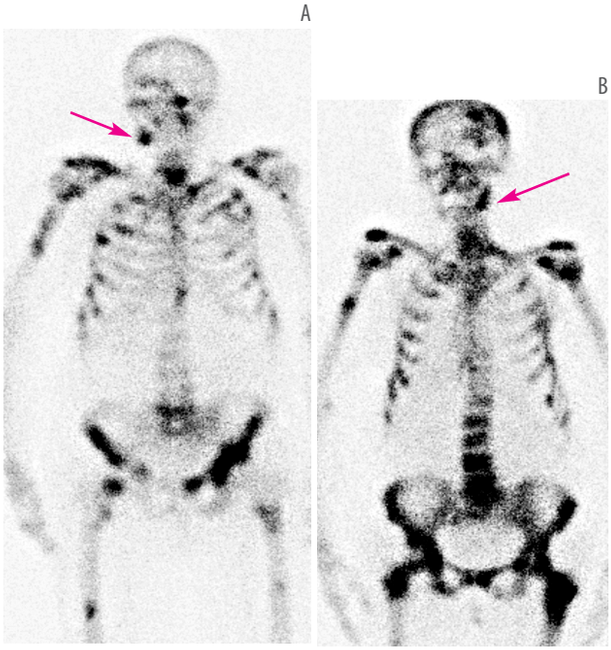

Figure 1. ^{153}Sm-EDTMP scintigraphy scans showing focal hot spots in the right mandible in a patient with breast cancer (A) and in the left, mandible in a patient with prostate cancer (B) (arrows).

venously on an outpatient basis in multiple treatments. This radiopharmaceutical has a lower radiation burden almost equal to that of ^{99m}Tc-MDP and high concentration at sites of increased bone turnover [12]. The higher concentration of this radionuclide in tumors as compared to rhenium may be the reason for showing more positive tumors as focal jaw uptake areas. Other researchers suggested that the distribution and sensitivity of ^{153}Sm-EDTMP was similar to that of ^{99m}Tc- MDP in bone scintigraphy resulting in identical images [13]. Others have found the percentage of metastatic disease in the jaw clinically at the range of 1% to 8%. Bone metastases to the oral cavity account for approximately 90% of all oral metastatic lesions. More than 70% of these occur in the mandible, usually in the molar-premolar regions, where the greatest amount of bone marrow is located. Adenocarcinomas of the breast, prostate, thyroid gland, lung, kidney, uterus, colon, and stomach are the primary tumors most frequently metastasizing to the mandibular region [14].

Further investigation by PET/CT, CT, MRI or by ^{99m}Tc-MIBI in order to avoid biopsy [9] is often necessary to exclude malignancy.

In conclusion, focal jaw lesions are usually benign and of dental origin. In a small percentage of cancer patients of about 4.3%, jaw lesions may be due to malignancy. Unfortunately, the number of studies is small, most of them are retrospective and few show biopsy results.

The authors declare that they have no conflicts of interest.

Bibliography

1. Arias JA, Pardo C, Olmos A et al. Dental diseases and radionuclide imaging of the jaws. *Nucl Med Commun* 2004; 25: 305-10.
2. Söderholm AL, Lindqvist C, Hietanen J et al. Bone scanning for evaluating mandibular bone extension of oralsquamous cell carcinoma. *J Oral Maxillofac Surg* 1990; 48: 252-7.
3. Craemer TD, Ficara AJ. The value of the nuclear medical scan in the diagnosis of temporo-mandibular joint disease. *Oral Surg Oral Med Oral Pathol* 1984; 58: 382-5.
4. Chiandussi S, Biasotto M, Dore F et al. Clinical and diagnostic imaging of bisphosphonate-associated osteonecrosis of the jaws. *Den tomaxillofacial Radiol* 2006; 35: 236-43.
5. El-Abedien AZ. Radionuclide skeletal scanning in dentistry. *Egypt Dent J* 1995; 4: 1383-90.
6. Lyons KP, Jensen JL. Dental lesions causing abnormalities on skeletal scintigraphy. *Clin Nucl Med* 1979; 4: 509-12.
7. Dimopoulos MA, Kastritis E, Anagnostopoulos A et al. Osteonecrosis of the jaw in patients with multiple myeloma treated with bisphosphonates; evidence of increased risk after treatment with zole dronic acid. *Haematologica* 2006; 91: 968-71.
8. Dammacco F, Rubini G, Ferrari C et al. ^{18}F-FDG PET/CT; a review of diagnostic and prognostic features in multiple myeloma and related disorders. *Clin Exp Med* 2014 Sept 14 [Epub ahead of print].
9. Catalano L, Del Vecchio S, Petruzziello F et al. Sestamibi and FDGPET scans to support diagnosis of jaw osteonecrosis. *Ann Hematol* 2007; 86: 415-23.
10. Stavropoulos MF, Ord RA. Lobular adenocarcinoma of breast metastatic to the mandibular condyle. *Oral Surg Oral Med Oral Pathol* 1993; 75: 575-8.
11. Sinzinger H, Weiss K, Hiltunen J. Background, reasons and benefits using the Vienna Protocol for the treatment of painful bone recurrences with ^{153}Sm-EDTMP. *Anticancer Res* 2009; 29: 3393-6.
12. Sabino M, Ghilardi J, Feia K. The involvement of prostaglandins in tumorogenesis, tumor induced osteolysis and bone cancer pain. *J Musc Skel Neur Interact* 2002; 2: 561-2.
13. Ramachandran K, Kathirresan, Begum B, Rangarajan. Comparison of ^{99m}Tc-MDP and ^{153}Sm-EDTMP bone scan. *Indian J Nucl Med* 2011; 26: 163-4.
14. Aniceto GS, Peñìn AG, Pages RM et al. Tumors metastatic to the mandible; analysis of nine cases and review of the literature. *J Oral Maxillofac Surg* 1990; 48: 246-51.

Henri de Toulouse-Lautrec (1864-1901): Private room in the "Le rat mort" (1899). Oil on canvas. Courtauld Gallery, London.